British Journal of Pharmacology and Toxicology 1(1): 1-5, 2010
ISSN: 2044-2467

Submitted Date: April, 05, 2010 Accepted Date: April 22, 2010 Published Date: June 20, 2010

Effects of Aqueous Extracts (Leaves and Stem) of *Vitex doniana* on Carbon Tetrachloride Induced Liver Injury in Rats

[1]D.B. James, [1]O.A Owolabi, [2] M. Bisalla and [1]H. Jassium
[1]Department of Biochemistry, Ahmadu Bello University, Samaru Zaria, Nigeria
[2]Department of Microbiology and Pathology, Ahmadu Bello University, Samaru Zaria, Nigeria

Abstract: Effects of aqueous extracts of leaves and stem of *Vitex doniana* on carbon tetrachloride induced liver injury in rats was assessed. Thirty- six (36) albino rats were divided into six groups of 6 animals each by the randomized random design method, each were allowed food and water *ad libidium*. Group I (control) was given olive oil, while the rest groups were injected intraperitoneally with a single dose of CCl_4 (1 mg/kg) as a 50% (v/v) solution in olive oil and all animals fasted for 36 h, this was repeated every week for a period of four (4) week after 36 h of induction, group III, IV, V and VI were given extracts of *Vitex doniana* at concentration dose of 100 and 200 mg/kg body weight. At the end of 4 weeks, weight change and histological sections of organs were examined. There was significant ($p<0.05$) reduction in percentage change in weights in rats treated with CCl_4 when compared to the control-group. Significant ($p<0.05$) increase in percentage change in liver, kidney and spleen in animals treated with CCl_4 was observed compared with control group and all animal administer *Vitex doniana*. Histological section of the organs shows that the levels of hepatic, renal and lymphatic damage were higher in CCl_4 treated rats than those rats supplemented with aqueous extract of *Vitex doniana*. These findings suggested that aqueous extract of *Vitex doniana* may have anti-hepatotoxic effect against CCl_4-induced liver injury in rats and that this effect is concentration dependent.

Key words: Carbon tetrachloride, hepatoprotective, histopathology, liver damage, *Vitex doniana*

INTRODUCTION

Vitex doniana is a savanna species in wooded grassland and can also be found along forest edges. It can be found throughout tropical Africa. The fruit are black, edible, sweet and mealy. It is frequently eaten as a snack and sold in local markets. The fruits are approximately 3 cm long and contain one to four seeds. The fruits are collected form April to June. Fresh fruits cannot be stored for long time periods (Ruffo *et al*., 2002).

Vitex doniana (*Verbernaceae*) commonly known as black plum or "Ori-nla" is wide spread in the southwestern Nigeria as a perennial trees. In Nigeria, from information available from the indigenous traditional healers, a decoction of the chopped stem bark part of *V. doniana* is prepared and taken orally for treatment of gastroenteritis. It is administered for ailments including diarrhea and dysentery. It is also taken to improved fertility and the juice may be squeezed into the eyes to treat eye troubles. it is also used in the treatment of liver disease.

Earlier workers have reported the use of the fruits and leaves for medicinal purposes (Sofwora, 1993; Babalola, 1993). The ability of an aqueous extract of *Vitex doniana* bark to protect the liver of albino rats from carbon tetrachloride-induced liver damage evaluated by measuring serum levels of Alanine Amino Transferase (ALT), Aspartate Amino Transferase (AST), Alkaline Phosphatase (ALP), bilirubin and total protein has been a report by Ladeji and Okoye (1996).

Among various chemicals that specifically injure the liver, carbon tetrachloride (CCl_4) is known to injure the liver through a series of reactions mediated by an oxidation involving free radicals (Clawson, 1989; Recknagel *et al*., 1989; Maezone *et al*., 1996). The mechanism through which carbon tetrachloride exerts its toxicity is still not understood clearly. The present study was conducted to evaluate effect of aqueous leaf and stem bark of *Vitex doniana* on CCl_4 induced liver injuries.

MATERIALS AND METHODS

Plant materials: This study was conducted in November, 2009 in Biochemistry Department, Ahmadu Bello University, Samaru, Zaria. The leaves and stem barks of *Vitex doniana* were collected from the Department of Anatomy faculty of medicine, Ahmadu Bello University, Zaria, Kaduna State. The leaves were identified at the herbarium in the Department of Biological Sciences, Ahmadu Bello University, Zaria.

Preparation of plant (whole plant): The collected plant was rinsed in clean water and dried at room temperature for two weeks. The dried plant sample was ground into

Corresponding Author: D.B. James, Department of Biochemistry, Ahmadu Bello University, Samaru Zaria, Nigeria

powder using a mortar and pestle, the powder obtained was then used to prepare the extracts.

Extractions: One hundred gram of each of the ground stem, barks and leaves were weighed into two conical flasks and 500 ml of distilled water was poured into each of the flasks. The contents of the 2 flasks were shaken and the tops were covered with aluminium foil and kept at room temperature for 48 h (2 days) after which the extracts were obtained by filtering using a filter paper. The extracts were then concentrated by drying in a water bath maintained at a temperature of 45ºC until brownish black residues were obtained and these were kept in sealed containers and refrigerated at 2-4ºC until required.

Lethal dose 50 (LD_{50}): Lethal dose 50 test involves the administration of a substance to a group of animals at increasing doses in order to determine the dose that kills 50% of the test subjects within a set time frame. Administration of leaves and stem barks of *Vitex doniana* were orally. The animal used for LD_{50} was grouped into 3 phases. All the phases had 3 groups with 3 animals in each group.

Animal grouping: Healthy wistar albino rats of both sexes weighing between 150-200 g were purchased from University of Jos, Plateau state, Nigeria and were kept in well-aerated laboratory cages and acclimatized for two weeks. They were allowed free access to water and feed diet (Vital Agricultural feeds Nigeria Limited) throughout the period of the experiment. Thirty-Six (36) were divided into six groups of 6 animals each by the randomized random design method. Group 1 was kept on normal diet and distilled water and served as control. The rest groups were injected intraperitoneally with a single dose of CCl_4 (1 mg/kg) as a 50% (v/v) solution in olive oil and fasted for 36 h, this was done once a week for a period of 4 weeks

Group 1: Rats given olive oil
Group 1: Rats given CCl_4 in olive oil

Table 1: Effect of *Vitex doniana* stem bark and leaf extracts on body weight and organ weight in CCl_4 treated albino rats

Change (%)	Control	CCl_4+ Water	CCl_4 + 100 mg/stem	CCl_4 + 200 mg/stem	CCl_4+ 100 mg/leaf	CCl_4 + 200 mg/leaf
Body weight	57.17 ± 0.04^a	31.40 ± 14.26^b	35.17 ± 21.40^b	46.33 ± 5.89^b	34.00 ± 10.41^b	20.00 ± 6.48^c
Liver weight	2.07 ± 0.04^b	2.36 ± 0.09^a	2.09 ± 0.02^b	1.93 ± 0.13^b	2.02 ± 0.05^b	1.62 ± 0.18^c
Kidney weight	0.45 ± 0.02^b	0.50 ± 0.01^a	0.42 ± 0.08^b	0.39 ± 0.01^b	0.42 ± 0.02^b	0.35 ± 0.02^c
Spleen weight	0.26 ± 0.03^b	0.32 ± 0.02^a	0.29 ± 0.02^{ab}	0.23 ± 0.02^c	0.25 ± 0.05^b	0.22 ± 0.03^b

Values are mean of six determinations ±S.D. values with different superscript in columns differ significantly ($p<0.05$)

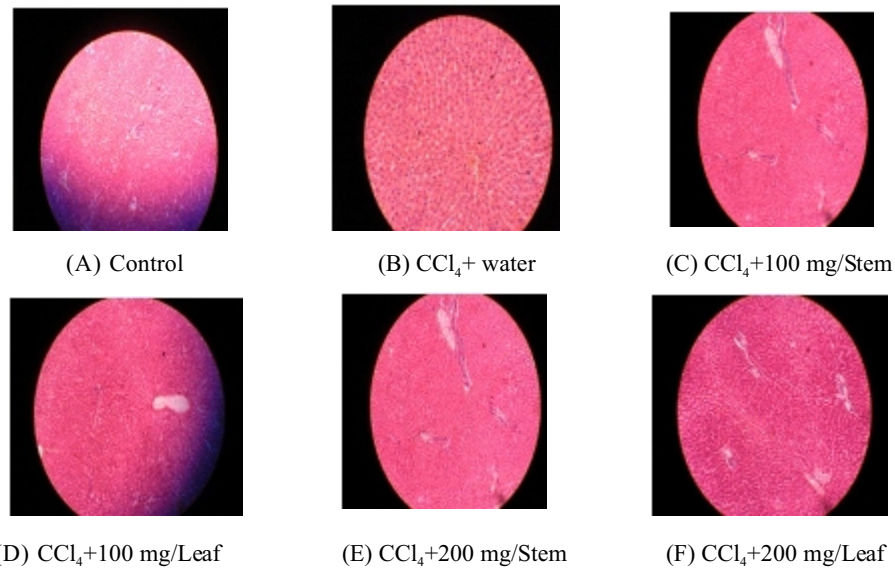

Fig. 1: Representative microscopic appearance of rat Liver after chronic CCl_4

A: Normal architecture of hepatic cells
B: Diffused areas of necrosis of hepatocytes. Prominent sinusoids and sinusoidal spaces were mostly obliterated. Distorted hepatic architecture and mononuclear cellular infiltration (per vascular cuffing)
C: It was seen that some few hepatocytes appeared to have retained their nuclei and sinusoidal spaces begin to open
D: It was observed that the hepatocytes and sinusoidal spaces were well defined, but kuffer cells were still prominent
E: Some hepatocytes appeared to have retained their nuclei. The sinusoidal spaces appeared to be opening up, but they were few scattered areas of necrotic hepatocytes
F: Most hepatocytes were seen to be intact. Liver appeared to move closer to control, or tending towards control

Group 3: Rats given CCl_4 in olive oil+ 100 mg/kg body weight Stem extract
Group 4: Rats given CCl_4 in olive oil + 200 mg/kg body weight Stem extract
Group 5: Rats given CCl_4 in olive oil+ 100 mg/kg body weight leaf extract
Group 6: Rats given CCl_4 in olive oil+ 200 mg/kg body weight leaf extract

Liver tissues examination: The animals were anesthetized on the 28th day and blood was collected by direct anesthesia of the animals. The livers, kidneys and spleens were removed, weighed and then fixed in 10% formaldehyde and processed for paraffin embedding using the standard micro-technique (Galozhger and Kocloff, 1971). Sections of the liver, spleen and kidney (5 µm) were stained and alum hematoxylin and eosin and observed with the light microscope for histopathological changes.

RESULTS AND DISCUSSION

In order to examine the effects of both leaves and stem barks of *Vitex doniana* on CCl_4 induced changes in body weight and tissue weight of albino rats, albino rats and their tissues were weighed (Table 1). After 4 weeks of CCl_4 treatment, there was significant ($p<0.05$) reduction in percentage change in weights in rats when compared to the control-group. Significant ($p<0.05$) reduction in percentage change in body weight in rats treated with 200 mg/kg leaf extract when compared to both the control and the treated groups was observed.

The percentage change in weights of liver, kidney and spleen were significantly ($p<0.05$) higher in rats treated with CCl_4 alone when compared with control and animals treated with both leaves and stem barks extracts of *Vitex doniana* and control. There was no significant change in Percentage change in Liver and kidney weight of animals administered extracts compared with the control except at 200 mg Kg body weight of leaf extract that was significantly ($p<0.05$) lower than the control Histological section (Fig. 1-3) of the organs shows that the levels of hepatic, renal and lymphatic damage were higher in CCl_4 treated rats than those rats supplemented with aqueous extract of *Vitex doniana*.

These results shows that the toxicity of CCl_4 is related to weight loss and abnormal tissue weight increase in rats, there was a significant ($p<0.05$) reduction in percentage change in weight in the group treated with CCl_4without extract when compared to the control. Also,

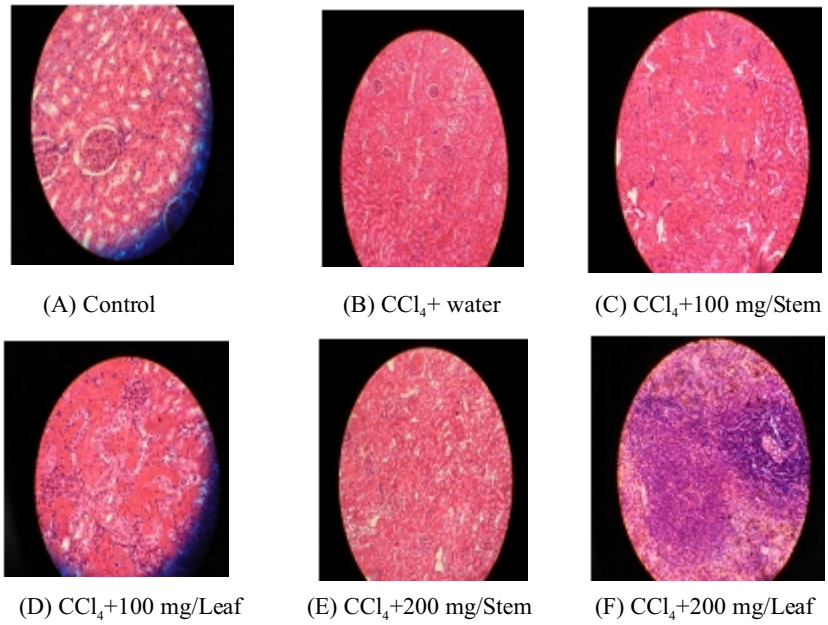

Fig. 2: Representative microscopic appearance of rat kidney after chronic CCl_4

A: Normal architecture of renal tube
B: showing collapse diffused necrosis of renal tubule and mononuclear infiltration into interstitial
C: Some tubules appeared to have retained nuclei in renal epithelium and some few tubules have clear lumens
D: Most kidney tubules were seen to be intact with well defined lumen but with few tubules still necrotic
E: Most renal tubules were seen to be intact with their nuclei. But there were few scattered foci of necrotic renal tubules
F: Renal tubules were seen to be intact with well-defined and clear lumens. Kidney tending towards control

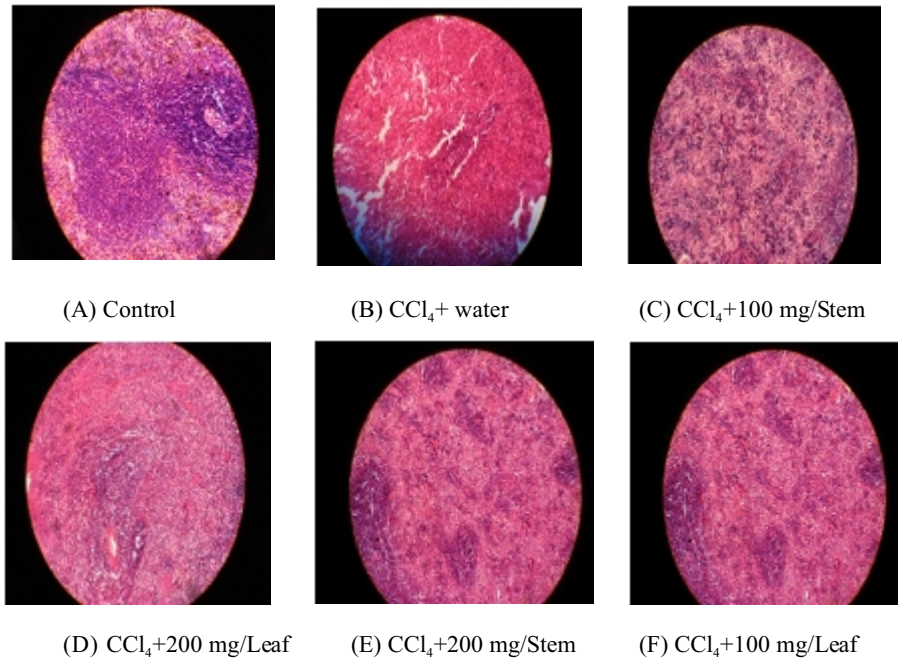

Fig. 3: Representative microscopic appearance of rat Spleen after chronic CCl_4

A: Normal architecture of lymphoid cells
B: There was depletion of lymphoid cells
C: Small diffused proliferation of lymphoid cells were seen
D: Lymphoid cells proliferation of germinal centers
E: Diffused proliferation of lymphoid cells were seen
F: Lymphoid cells proliferation at germinal center spleen tending towards control

group administered with 200 mg/kg body of leaf extract showed a significantly ($p<0.05$) lower percentage change in weight when compared to the rest groups. The significant ($p<0.05$) reduction in the weight of animal administered 200 mg/kg body weight of the leaf extract may be attributed to the presence of tannins in the plant extract. Tannins are complex phenolic polymers, which can bind to proteins and carbohydrates resulting in reduction in digestibility of these macromolecules and thus inhibition of microbial growth (Nwogu *et al*., 2008; Bulter, 1989). Tannins causes decreased feed consumption in animals; bind dietary protein and digestive enzymes to form complexes that are not readily digestible (Aletor, 1993). They also cause decreased palatability and reduced growth rate (Roeder, 1995). Presence of tannins has been reported by Suleiman and Yusuf (2008).

The table also shows the percentage change in weight of liver, kidney and spleen. There was a significant ($p<0.05$) increase in liver, kidney and spleen in groups induced with CCl_4without treatment compared to the control and the treated group.

In histopathological examination of the liver, kidney and spleen treated with CCl_4, cells of near the hepatoportal vein, the sinusoidal spaces, the lumen, tubules and lymphoid cells showed signs of vascular degeneration or necrosis as seen in (Fig. 1-3). On administration of extracts, there was regeneration of the cells of the liver, kidney and spleen, which depends on the dosage. The higher the dosage of extracts of *Vitex doniana* taken the more then regeneration of the cells

REFERENCES

Aletor, V.A., 1993. Allelochemicals in plant foods and feeding Stuffs. Part I. Nutritional, Biochemical and Physiopathological aspects in animal production. Vet. Hum. Toxicol., 35(1): 57-67.

Babalola, E.O., 1993. The persistence of African Traditional medicine in contemporary Nigeria Society. African Marburgensia, 26: 4.

Bulter, L.G., 1989. Effects of Condensed Tannins on Animal Nutrition. In: Hemmingway, R.W. and J.J. Kachey, (Eds.), Chemistry and Significance of Condensed Tannins. Plenum Press, New York, pp: 391-402.

Clawson, G.A., 1989. Mechanism of carbon tetrachloride hepatotoxicity. Pathol. Immunopathol. Res., 8: 104-112.

Galozhger, A.E. and E.N. Kocloff, 1971. Essential Practical Microtechnique. 2nd Edn., Lee and Febizer, Philadelphia, pp: 77.

Ladeji, O. and Z.S.C. Okoye, 1996. Anti-hepatotoxic properties of *Vitex doniana* bark extract. Pharm. Biol., 34(5): 355-358.

Maezone, K., K. Kajiwara, K. Mawatari, A. Shinkai, K. Torii and T. Kaki, 1996. Alanine protects liver from injury caused by D-galactosamine and CCl_4. Hapatology, 24: 185-191.

Nwogu, L.A., C.U. Igwe and A.A. Emejulu, 2008. Effects of *Landolphia owariensis* leaf extract on the liver function profile and haemoglobin concentration of albino rats. Afr. J. Biotechnol., 2(12): 240-242.

Recknagel, R.O., E.A. Glende Jr, J.A. Dolack and R.L. Waller, 1989. Mechanisms of carbon tetrachloride toxicity. Pharmacol. Ther., 43: 139-154.

Roeder, E., 1995. Medicinal plants in Europe containing Pyrrolidizine alkaloids. Pharmazie, 50: 83-98.

Ruffo, C.K., A. Birnie and B. Tengas, 2002. Edible Wild Plants of Tanzania. Relma Technical Handbook No. 27, pp: 766.

Sofwora, A., 1993. Medicinal Plants and Traditional Medicine in Africa. Spectrum Books Ltd. 2nd Edn., pp: 26-100.

Suleiman, M.M. and S. Yusuf, 2008. Antidiarrheal Activity of the Fruits of *Vitex doniana* in laboratory animals. Pharm. Biol., 46(6): 387-392.