Current Research Journal of Biological Sciences 3(4): 308-312, 2011
ISSN: 2041-0778

Received: January 15, 2011 Accepted: March 08, 2011 Published: July 15, 2011

The Effect of *Yaji*-Meat-Sauce Consumption on Cerebellar Neurons of White Albino Rats

[1,2]A.O. Nwaopara, [1,3]U. Akpamu, [2]A.M. Izunya, [2]G.A. Oaikhena, [4]O. Okhiai, [2]L.C. Anyanwu, [5]B.O. Idonije and [6]G.P. Oyadonghon
[1]Anthonio Research Centre, Ekpoma, Nigeria
[2]Department of Anatomy,
[3]Department of Physiology,
[4]Department of Nursing Sciences,
[5]Department of Chemical Pathology, Ambrose Alli University, Ekpoma, Edo, Nigeria
[6]Department of Anatomy, Ambrose Alli University, Uturu, Abia State, Nigeria

Abstract: This study on the cerebellum is one in the series of several studies aimed at determining the effects of *Yaji* on the histology of the brain. Eighteen-week-old white albino rats of an average weight of 170 g were used for this study and they were divided into eight (8) groups (A-H). Group A served as control while groups B-H served as the test groups. For 2 weeks, group A received normal feed only, while groups B-H received feed plus graded levels of *Yaji* (10, 20, 30, 40, 50, 60, and 70%, respectively) per ration of feed daily. The results showed distortions in the cellular architecture of the cerebellum irrespective of the dosage. The micrographs presented histological signs of purkinge cell degeneration and the clumping of granular cells with cerebellar cavitations. Our findings suggests that *Yaji* has neurotoxic potentials, which 'illuminates' further the rising concern about the safety of *Yaji* consumption even beyond the shores of Nigeria, as well as re-echo the urgent need to regulate the production and consumption of *Yaji*.

Key words: Additives, cerebellum, excitotoxicity, *Suya*, *Yaji*, spices

INTRODUCTION

There is a growing concern about the indiscriminate and mass consumption rate of *Yaji*, which, in recent years, have been the basis of several scientific investigations (Nwaopara *et al*., 2004; 2007a, b; 2008a, b; 2009; 2010a, b). Some of the findings from such investigations show that an excessive consumption of *Yaji* has the capability to induce pancreatic, liver, kidney and brain damage (Nwaopara *et al*., 2004; 2007b; 2008a; 2010a, b). These findings further illuminate the fears that an unregulated production and consumption of *Yaji*, portends serious dangers to the health of its consumers. Of importance also, are the reports that some of the active principles in *Yaji*, like capsaicin, piperine and monosodium glutamate possesses excitotoxic and apoptotic potentials (Choi, 1988; Blaylock, 1997; Lipton and Rosenberg, 1994; Whetsell and Shapira, 1993; Olney, 1989; Olney *et al*., 1997; Sugimoto *et al*., 1998; Ankarcrona *et al.* 1998; Martin *et al*., 2000).

This Nigerian meat sauce known as *Yaji*, is a complex physical mixture of groundnut cake powder, additives, spices and salt (Okonkwo, 1987). Its main additive called 'white maggi' contains monosodium glutamate (MSG) while the constituent spices-ginger, clove, red pepper and black pepper (Nwaopara *et al*., 2004) contains gingerol (Witchtl, 2004), eugenol (Krishnaswamy and Raghuramulu, 1998), capsaicin (Collier *et al*., 1965), and piperine (McGee, 2004) as active principles respectively. In fact, the potential health hazards of *Yaji*, based on its active principles in combination, have been highlighted (Nwaopara *et al*., 2007a).

The Nigerian meat delicacy served with *Yaji* is called *Suya*. It is a popular, traditionally processed, ready to eat meat product that may be served or sold along streets, in club houses, at picnics, parties, restaurants and within institutions (Igene and Mohammed, 1983). According to Omojola (2008), it is one of such intermediate moisture products that is easy to prepare and highly relished while Uzeh *et al*. (2006) describes it as a mass consumer fast food whose preparation and sales along the streets, are usually not done under strict hygienic condition because they are still done locally.

With focus on the complexity of *Yaji* and the barrage of health related questions on it, this two-week study on the cerebellum is one in the series of several studies aimed at determining the effects of *Yaji* consumption on organ systems.

Corresponding Author: Nwaopara Anthony Obioma, Department of Anatomy, Ambrose Alli University, Ekpoma, Edo State, Nigeria. Tel.: +234803 744 1401; +234809 198 5381

MATERIALS AND METHODS

Location and duration of study: This study was conducted at the histology laboratory of Anthonio Research Center, Ekpoma, Edo State, Nigeria. The preliminary studies, animal acclimatization, ingredients procurement/*Yaji* production, actual animal experiment, histological processing, microscopy/micrography and evaluation of results, lasted for a period of seven months. However, the actual administration of *Yaji* to the test animals lasted for two weeks.

The substance of study: The constituents of *Yaji* were procured from the Aduwawa Cattle market, Benin City, Edo State, Nigeria, and subsequently mixed as appropriate in powdery forms. Since the commonly sold *Yaji* is a crude mixture of its constituents with no standard production procedure (weight for weight), the mixture of these constituents to produce *Yaji* for this study was as directed by the dealers of *Yaji* at the Aduwawa Cattle market, Benin City, Edo State, Nigeria but were respectively measured in order to determine the respective quantities of the constituents in a given quantity of *Yaji*.

The measurements were done using an electric weighing balance by Denver Company USA (200398.1REV.CXP-3000). The measured quantities were Ajinomoto ('white maggi' containing MSG) (150 g), Black pepper (30 g), Clove (39 g), Ginger (78 g), Groundnut cake powder (230 g), Red pepper (22 g), and Salt (100 g). The total value of these constituents summed up to 649 g. To produce pellets for the experimental animals, appropriate quantities of *Yaji* and feed were mixed with sprinkles of water and the resultant paste was then split into bits and allowed to dry under the sun.

The subjects/ substance administration: White albino rats of an average weight of 170 g were used for this study. They were divided into eight (8) groups (A-H). Group A served as the control while the subgroups of B-H served as the test groups. Through out the duration of the experiment, group A rats were fed with normal feed (Growers mash) from the Bendel Feeds and Flour Mills (BFFM), Ewu, Edo State, Nigeria, while test groups B-H rats were fed for two weeks with growers mash from the same source plus graded levels of *Yaji* (B, 10%; C, 20%; D, 30%; E, 40%; F, 50%; G, 60%; H, 70%) per ration of feed daily.

The total daily feeding allowance for each experimental group was 30 g while the feeding allowance per rat was 6g. Test groups B (10%) received 3g of *Yaji* daily (0.6 g/rat), C (20%) received 6g of *Yaji* daily (1.2 g/rat), D (30%) received 9 g of *Yaji* daily (1.8 g/rat), E (40%) received 12 g of *Yaji* daily (2.4 g/rat), F (50%) received 15 g of *Yaji* daily (3 g/rat), G (60%) received 18 g of *Yaji* daily (3.6 g/rat), and H (70%) received 21 g of *Yaji* daily (4.2 g/rat).

Tissue processing: The experimental animals were sacrificed after two (2) weeks and the tissues obtained were immediately fixed in formaldehyde to prevent autolysis and putrefaction. Tissue sections were produced by normal histochemical methods of fixation, dehydration, impregnation, embedding, sectioning and staining (with H and E) described by David (2004). The micrographs of the relevant stained sections were subsequently taken with the aid of a light microscope (at magnification × 40).

RESULTS AND DISCUSSION

The result of this study showed several degenerative changes amongst which are the presence of vacuolations, eosinophilic cells, pyknotic nuclei, and gliosis. The generally observed distortions in the cellular architecture of the cerebellum were independent on the dosage. Specifically, the micrographs showed histological signs of purkinge cell degeneration as marked "A" or "a" and the clumping of granular cells with cerebellar cavitations in the Plates labelled 10, 20, 30, 40, 50, 60 and 70%.

Considering the obvious complexity of *Yaji* in terms of the contained active principles and the known negative potentials of its active ingredients particularly in combination; as well as the obvious histological signs of purkinge cell degeneration, clumping of granular cells, and cerebellar cavitations represented on the micrographs, one can postulate that the contents in *Yaji* can induce cerebellar cell damage. Eweka and Om'Iniabohs (2007) had earlier suggested that MSG consumption may have some deleterious effects on the cerebellum of adult wister rats at higher doses and by extension may affect the functions of the cerebellum thereby resulting in tremor, unstable and uncoordinated movement or ataxia. The basis for this assertion is predicated upon the fact that monosodium glutamate may act as a toxin to cerebellar neurons; affect cerebellar cellular integrity; and cause defects in membrane permeability and cell volume homeostasis. Of course, the excitotoxicity potentials of MSG are no longer in doubt (Espinar *et al*., 2000; Urena-Guerrero *et al*., 2003).

There are reports too that on one hand, piperine in black pepper is cytotoxic to cerebellar granule neurons (Unchern *et al*., 1998), while on the other hand, it promotes DNA damage (Piychatuwarat *et al*., 1995), which is itself, a significant trigger for apoptosis. Thus, these well-known excitotoxic potentials of piperine in black pepper may have contributed to the observed histological changes. This also applies to capsaicin in red pepper, known to cause neurodegeneration (Jancso *et al*., 1977; Ritter and Dinh, 1993; Chard *et al*., 1995; Wood *et al*., 1993).

Another consideration is the known deleterious effects of oxidized groundnut oil on the architecture of tissues (Florence and Adewale, 2004), which in this

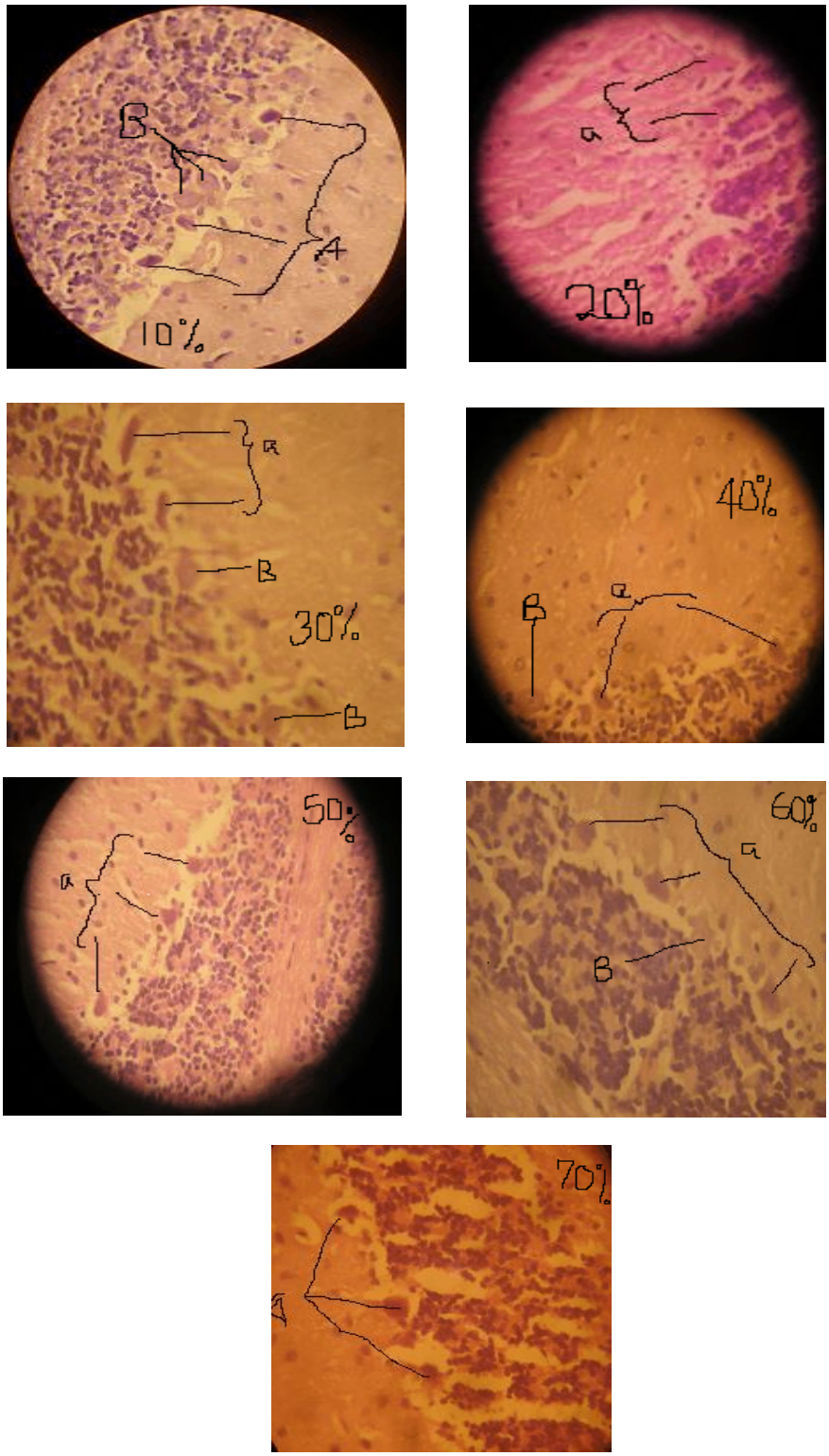

Plate 1: 10, 20, 30, 40, 50, 60, 70% (Cerebellum Brain H&E x40) showing histological signs of purkinge cell degeneration (as marked A or a) and clumping of granular cells with cerebellar cavitations. Compare the surviving purkinge cells with the degenerating eosinophilic ones in plates 10, 30, 40 and 60% (as marked B)

circumstance, implicates the fried ground cake powder in *Yaji*. This is predicated upon the fact that dietary oil rich in polyunsaturated fatty acids is susceptible to oxidative changes during use like frying (Ologan, 2002) resulting in the formation of peroxides, aldehydes, ketones, aldehydroesters and ozonides (Frankel, 1980; Kubow, 1992; Odutuga *et al*., 1997) known to be injurious to health (Frankel, 1980; Halliwell and Gutteridge, 1984; Addis, 1986; Kubow, 1992).

CONCLUSION

Our findings therefore, suggest that there are active ingredients in *Yaji* that have neurotoxic potentials, confirming an earlier assertion that *Yaji* has the capacity to induce neurodegeneration (Nwaopara *et al*., 2010). It is our candid opinion that the growing concern about the safety of *Yaji* consumption even beyond the shores of Nigeria and the urgent need to regulate its production and consumption can no longer be ignored.

ACKNOWLEDGMENT

We are sincerely grateful to Mr. Olupona Babafemi of the Histopathology Laboratory, University College Hospital (UCH) Ibadan, Oyo State, Nigeria, for his technical assistance.

REFERENCES

Addis, P.B., 1986. Occurrence of lipid oxidation products in food. Food Chem. Toxic., 24: 1021-1030.

Ankarcrona, M., J.M. Dypbukt, E. Bonfoco, B. Zhivotovsky, S. Orrenius, S.A. Lipton and P. Nicotera, 1998. Glutamate-induced neuronal death: A succession of necrosis or apoptosis depending on mitochondrial function. Neuron, 15: 961-973.

Blaylock, L.R., 1997. Excitotoxins: The Taste that Kills. Santa Fe, NM., Health Press, pp: 248-254.

Chard, P.S., D. Bleakman, J.R. Savidge and R.J. Miller, 1995. Capsaicin induced neurotoxicity in cultured dorsal root ganglion neurons: Involvement of calcium activated proteases. Neuroscience, 65(4): 1099-1188.

Choi, D., 1988. Glutamate neurotoxicity and diseases of the nervous system. Neuron, 1: 623-634.

Collier, H.O., W.J. McDonald-Gibson and S.A. Saeed, 1965. Letter: Stimulation of prostaglandin biosynthesis by capsaicin, ethanol and tyramine. J. Physiol. (Lond), 179(2): 248-262.

David, K., 2004. Tissue Preparation. Retrieved from: htpp://www.siumed.edu/~dking2/intro/tissuprep.htm, (Accessed on: 20 October).

Espinar, A., A. García-Oliva, E.M. Isorna, A. Quesada, F.A. Prada and J.M. Guerrero, 2000. Neuroprotection by melatonin from glutamate-induced exocitoxicity during development of the cerebellum in the chick embryo. J. Pineal Res., 2: 81-88.

Eweka, A.O. and F.A.E. Om'Iniabohs, 2007. Histological studies of the effects of monosodium glutamate on the cerebellum of adult wistar rats. Internet J. Neurol., 8(2).

Florence, O.Z. and Z. Adewale, 2004. Histological changes of selected tissues following the ingestion of thermally oxidized groundnut oil. Biokemistri, 16(1): 1-10.

Frankel, E.N., 1980. Lipid Oxidation. Prog. Lipid Res., 19: 1-22.

Halliwell, B. and J.M.C. Gutteridge, 1984. Lipid peroxidation, oxygen radicals, cell damage and antioxidant therapy. Lancet, 1: 1396-1398.

Igene, J.O. and I.D. Mohammed, 1983. Consumers' attitudes towards 'suya' meat product. Ann. Borno. 1: 169-176.

Jancso, G., E. Kiraly and A. Jancso-Gabor, 1977. Pharmalogically induced selective degeneration of chemosensitive primary sensory neurons. Nature, 270: 741-754.

Krishnaswamy, K. and N. Raghuramulu, 1998. Bioactive phytochemicals with emphasis on dietary practices. Indian. J. Med. Res., 108: 167-181.

Kubow, S., 1992. Route of formation and toxic consequences of lipid oxidation products in food. Free Rad. Bio. Med., 12: 63-81.

Lipton, S. and P. Rosenberg, 1994. Excitatory amino acids as a final common pathway for neurologic disorders. NEJM, 330: 613-622.

Martin, L.J., F.E. Sieber and R.J. Traystman, 2000. Apoptosis and necrosis occur in separate neuronal populations in hippocampus and cerebellum after ischemia and are associated with differential alterations in metabotropic glutamate receptor signaling pathways. J. Cereb. Blood Flow Metab., 20: 153-167.

McGee, H., 2004. On food and Cooking: The Science and Lore of the Kitchen. Scribner, New York, pp: 427-429.

Nwaopara, A.O., L.C. Anyanwu, C.A. Oyinbo and I.C. Anaikot, 2004. The histological changes in pancreas of wister rats fed with diets containing Yaji (Local meat Sauce). J. Expt. Clin. Anat., 3(2): 44-47.

Nwaopara, A.O., M.A.C. Odike, T.A. Ikhuoriah and L.C. Anyanwu, 2007a. Potential health hazards in Yaji: The complex suya meat sauce. Medilink J., 8(74): 34-38.

Nwaopara, A.O., M.A.C. Odike, U. Inegbenebor and M.I. Adoye, 2007b. The Combined effects of excessive consumption of ginger, clove, red pepper and black pepper on the histology of the liver. Pak. J. Nutr., 6(6): 524-527.

Nwaopara, A.O., M.A.C. Odike, U. Inegbenebor, S.O. Nwaopara and G.I. Ewere, 2008a. A comparative study on the effects of excessive consumption of ginger, clove, red pepper and black pepper on the histology of the Kidney. Pak. J. Nutr., 7(2): 287-291.

Nwaopara, A.O., M.A.C. Odike, U. Inegbenebor, S.O. Nwaopara and E.I. Ekhoye, 2008b. A comparative study on the effects of excessive consumption of ginger, clove, red pepper and black pepper on the histology of the Heart. Electron. J. Biomed., 3: 61-64.

Nwaopara, A., C. Anibeze, F. Akpuaka and S. Nwaopara, 2009. Antimicrobial potentials of yaji-spices: The constituents of a complex nigerian suya meat sauce inducing histological investigations. Internet J. Altern. Med., 6(2).

Nwaopara, A.O., C.I.P. Anibeze, and F.C. Akpuaka, 2010a. Induced histological features of hypoxia-ischaemia in the brain of rats fed with diet containing Yaji: The complex nigerian meat sauce. Res. J. Appl. Sc, Engr. Tech., 2(1): 67-72.

Nwaopara, A.O., C.I.P. Anibeze and F.C. Akpuaka, 2010b. Histological signs of neurodegeneration in the cerebrum of rats fed with diet containing Yaji: The complex nigerian suya meat sauce. Asian J. Med. Sc., 2(1): 16-21.

Odutuga, A.A., J.A. Obaleye and F.O. Ologan, 1997. Hermoxidied Soybean oil: Spectroscopic investigation and effects on selected rat tissues. Biokemistri, 1: 45-58.

Okonkwo, T.M., 1987. About suya and Yaji. J. Food Agric., 1(1): 51.

Olney, J., 1989. Glutamate, a neurotoxic transmitter. J. Child Neurol., 4: 218-26.

Olney, J.W., D.F. Wozniak and N.B. Farber, 1997. Excitotoxic neurodegeneration in Alzheimer's disease. Arch. Neurol., 54: 1234-1240.

Ologan, F.O., 2002. Some physicochemical properties of thermally oxidized groundnut oil and their toxicological effects on selected rat tissues. Ph.D. Thesis, University of Ilorin, Ilorin, Nigeria.

Omojola, A.B., 2008. Yield and organoleptic characteristics of Suya (an intermediate moisture meat) prepared from three different muscles of a matured bull. Afr. J. Biotechnol., 7(13): 2254-2257.

Piychatuwarat, P., S. Kingkaeohoi and C. Toskulkao, 1995. Potentiation of carbon tetrachloride hepatotoxicity by piperine. Drug Chem. Toxicol., 18(4): 333-344.

Ritter, S. and T.T. Dinh, 1993. Capsaicin Induced Degeneration in Rat Brain and Retina in Capsaicin in the Study of Pain. Academic Press, San Diego CA, pp: 105-138.

Sugimoto, T., C. Xiao and H. Ichikawa, 1998. Neonatal primary neuronal death induced by capsaicin and axotomy involves an apoptotic mechanism. Brain Res., 807(1-2): 147-54.

Unchern, S., H. Saito and H. Nisli-Yama, 1998. Death of cerebella granules neurons induced by piperine is distinct from that induced by low potassium. Neurchem. Res., 23(1): 97-102.

Urena-Guerrero, M.E., S.J. Lopez-Perez and B. Beas-Zaratel, 2003. Neonatal Monosodium glutamate treatment modified glutamic acid decarboxylase activity during rat brain postnatal development: Neurochem. Int., 42(4): 269-276.

Uzeh, R.E., R.E. Ohenhen and O.O. Adeniji, 2006. Bacterial contamination of tsire-suya, a nigerian meat product. Pak. J. Nutr., 5(5): 458-460.

Whetsell, W. and N. Shapira, 1993. Biology of disease, neuroexcitation, excitotoxicity and human neurological disease. Lab. Invest., 68: 372-387.

Witchtl, M., 2004. Herbal Drugs and Phytopharmaceuticals. 3rd Edn., CRC Press, Boca Raton FL, pp: 653-656.

Wood, J., 1993. Capsaicin in the Study of Pain. Academic Press Inc., San Diego, London, ISBN: 10: 01276855X.

AUTHORS CONTRIBUTION

Nwaopara, A.O. is the research team leader. He conceived and supervised this research study. Akpamu, U. is the assistant research team leader and research laboratory supervisor at Anthonio Research Lab. Ekpoma, Edo State, Nigeria. His animal/tissue handling experience immensely contributed to the success of this study. Tissue processing was supervised by Nwaopara, A.O. and U. Akpamu, with technical assistance from Mr. Olupona Babafemi. Micrography, results evaluation, research reporting and critical inquisitions were undertaken by the entire research team (Nwaopara, A.O., U. Akpamu, A.M. Izunya, G.A. Oaikhena, O. Okhiai, L.C. Anyanwu, B.O. Idonije and G.P. Oyadonghon,) Their backgrounds in Anatomy, Physiology and Pathology played significant roles.