Current Research Journal of Biological Sciences 4(4): 482-487, 2012
ISSN: 2041-0778

Submitted: March 19, 2012 Accepted: April 10, 2012 Published: July 10, 2012

Effect of the Overcrowding Stress on Fundus of Stomach in Adult Male Albino Rats

Maisa Mohammad Amin Al-Qudah
Department of Allied Medical Sciences, Zarka University College,
Al-Balqa Applied University, Jordan

Abstract: Overcrowding as a chronic source of stress constituted a major threat to psychological well-being. Dense populations were characterized by considerably increased aggressive behavior . The present study aimed to examine the effect of overcrowding stress on the histology of fundus and fundic glands of male albino rats .Ten animals were used in this study divided into two groups: control group (group A) was formed of 5 animals and experimental group (group B) was formed of 5 animals that were subjected to overcrowding. The rats were kept in the overcrowded condition continuously for 4 h/day, for a period of 7 days. at the end of the experiment stomach specimens were obtained, processed and subjected to different histological techniques. All the layers of stomach were affected in rats exposed to overcrowding stress conditions. Overcrowding stress led to desquamation, necrosis and ulceration of gastric epithelium. Mononuclear cellular infiltrate and congested blood vessels were also noted in lamina propria. Necrosis in mucosa was the prominent histological change when the effect reached the maximum. It could be concluded that overcrowding stress lead to gastric mucosal damage represented by necrosis and ulceration. Moreover, the other layers of fundus were affected such as muscularis.

Keywords: Fundic glands, histology, light microscope, overcrowding, rats, stomach

INTRODUCTION

Crowding is a psychologic and ecologic aspect of population density which produces a significant impact upon the behavior and physiology both of individuals and of social groups. Crowding , as a chronic source of stress, constituted a major threat to psychological well-being. Crowding results in anxiety and social instability. Dense populations were characterized by considerably increased aggressive behavior. In the literature there is growing evidence linking oxidant molecules and the degenerative and physiological changes that occur with advancing age (Alfawwaz and Alhamdan, 2006; Saalu *et al*., 2008; Saalu *et al*., 2011) .

Overcrowding was considered one of the most important problems in many cities in different countries of the world. It disturbed the homeostasis and might induce various disorders (Bateson *et al*., 2004). Crowding became one of the most popular stressors in experimental medicine, since it could be regulated easily and was reproducible (Nagaraja *et al*., 1997; Mostafa, 2010). Dense populations could influence the hypothalamic-pituitary-adrenocortical axis, the hypothalamic-pituitary-gonadal axis, sympatho-adrenomedullary system and sympathetic nervous system, leading to changes in many organs (Cvijic and Dordevic, 2003). Overcrowding stress had been implicated in hypertension, arteriosclerosis, diabetes mellitus and other diseases in clinical and epidemiological studies (Delaunay *et al*., 1997; Mostafa, 2010).

Although crowding is a relatively mild stressor, it affects signal transduction in Hypothalamichypophyseal-adrenal Axis (HHA) (Bugajski *et al*., 2006; Gadek-Michalska *et al*., 2005; Dorko *et al*., 2000). Stressors are classified into acute and chronic type based upon the dimension of intensity, frequency of exposure and duration of exposure . Regardless of their degree of severity, stressor may promote physiological and behavioral disturbances ranging from psychiatric disorders to immune system dysfunction (Brown, 1993). The organism usually responds to stress with a variety of behavioral, biological and cognitive changes. Stressful events may profoundly influence the use of alcohol or other drugs (Roman *et al*., 2003; Nagaraja and Jeganathan, 2003).

Chronic stress has been proposed to compromise the function of the hippocampus, a region in the brain important for memory processing (Eichenbaum, 1997). Chronic exposure to stress steroids, known as Glucocorticoids (GCs), makes hippocampal neurons vulnerable to GC such that over a life span, damage may eventually arise in the neurons (Sapolsky, 1992). Though stress-induced memory impairments have been extensively studied, very few studies have looked into possible ways of preventing their deleterious effects. Stress exerts detrimental effects on several cellular functions through impairment of antioxidant defenses, leading to oxidative damage, a process central to many diseases (Torres *et al*., 2004; Kumar *et al*., 2009).

Some research has suggested that crowded conditions can detrimentally affect children's development. Goduka *et al.* (1992) found that crowding was an important predictor of both cognitive development and selfconcept in a sample of South African children. Similarly, Widmayer *et al.* (1990) found that overcrowding in the home was associated with poor psychomotor development in Haitian children. Crowding also seems to affect the quality of caregiver-child interaction. Fuller *et al.* (1993) found that crowded conditions were associated with lower levels of verbal stimulation and responsiveness by mothers towards their children.

Nayanatara *et al.* (2009) indicated that cumulative effect of repeated chronic unpredictable stressors on a daily basis for a period of 10 days increases the lipids and biochemical parameters in Wistar rats. Moreover, crowding was found to decrease body weight and increase adrenal epinephrine secretion, thereby indicating that crowding may be considered as a stressful stimulus (Chaouloff and Zamfir, 1993). The aim of the experiment was to determine the effect of acute overcrowding stress on fundus and fundic glands.

MATERIALS AND METHODS

Animals: Ten adult male albino rats (aged six months) with an average weight of 250 ± 5 gm were used in this study. Rats were obtained and housed in the animal House of Department of pharmacology - Faculty of Medicine, University of Jordan. The rats were kept at room temperature (22-26ºC) in a controlled room with a 12-h light: 12-h dark cycle. The normal rat chow and tap water were provided *ad libitum* during the experiment. The duration of the experiment was 7 days. The study was approved by the animal ethics committee of the University of Jordan. All rats were first put in control plastic cages. The size of the control cage was 41×28×19 cm which allowed the animals to move freely. All animals were supplied with drinking water and ample amounts of food. They were handled daily for one week prior to the experiment to minimize the non specific stress on the days of the experiment. The study was conducted in the department of histological sciences, university of Jordan, in September , 2011.

Stress protocol: The stress procedure used was based of that described by Nagaraja and Jeganathan (2003), involved placing group of five male rats in cage of size 31×18×10 cm in such a way that only minimum mobility was possible inside the cages. The rats were kept in this overcrowded condition continuously for 4 hours / day then they were shifted to the control cages. All experimental stress procedures started between 9:00: am and end at 1:00: pm to minimize the effect of circadian rhythm of hormones.

Animal groups:

Group A: The control group . It is consisted of 5 rats which were kept under standard laboratory conditions without any stress exposure.

Group B: Crowding stress group . Included 5 animals which were subjected to acute crowding condition (stress for 7 days). They were housed in the small cages (31×18×10) cm for 4 h/day for 7 days according to stress protocol mentioned before.

All the animals were sacrificed at the end of the experimental period without any discomfort and all survived to the end of the experiment. After the last four hours of crowding stress, the animals were sacrificed at the appropriate time. The abdomen was opened and stomach was excised. It was opened along its greater curvature, washed gently with saline. Each specimen was fixed in 10% formaldehyde, dehydrated, cleared and paraffin sections were prepared as usual and were subjected to Haematoxylin and Eosin stains.

Preparation of tissues for microscope examination: The tissues removed were fixed for 7 days in 10% formaldehyde after which dehydration was carried out in ascending grade of alcohol. The tissues were then cleared of xylene overnight (16 h) to remove the alcohol.Infiltration/impregnation was done in three changes of molten soft paraffin wax at - 68ºC for 1 hour each. Embedding and casting in paraffin wax with stainless steel block was done and sectioning carried out using a microtome . The sectioned tissues from stomach were loaded on slides . Dewaxing was done using hot plate and then clearing in two changes of xylene. Xylene was removed with absolute alcohol and finally before staining, hydration was done. Haematoxylin and eosin staining was used . The slides were then evaluated for pathological changes under light microscope.

RESULTS

Examinations of sections of the fundus of stomach of control rats (Fig. 1) showed that the wall of the fundus of the stomach was formed of 4 classic layers namely, mucosa, submucosa, musculosa and serosa. The fundic glands were simple branched tubular with different types of cells lined the pit and glandular regions. Surface mucous cells lined the gastric pits; they were columnar acidophilic cells with oval basal nuclei . The neck of the glands was lined by mucous neck cells. They appeared as groups of cuboidal cells with flattened basal nuclei and vacuolated cytoplasm. Parietal cells are dispersed throughout the gland characterized by their highly acidophilic cytoplasm and central rounded nuclei (Fig. 1).

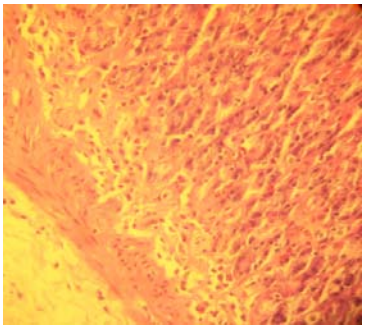

Fig. 1: Stomach control, Transverse section of fundic glands with chief cells at the base. 400X, (H&E stain)

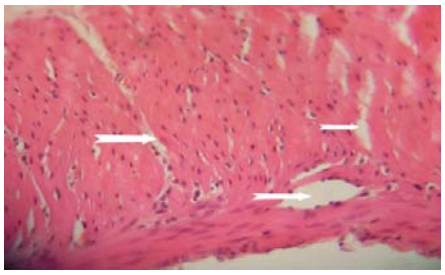

Fig. 2: Transverse section of treated rat stomach. → disintegration of muscle fibers in muscularis. 400X, (H&E stain)

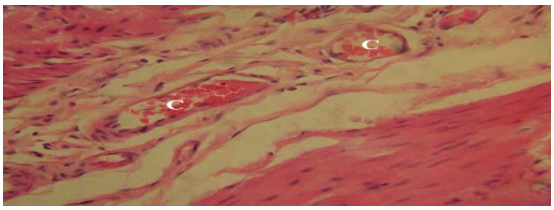

Fig. 3: Transverse section of treated rat stomach. C: congested blood vessels in submucosa. 400X, (H&E stain)

Chief cells that lined the base showed basal basophilia, apical acidophilic cytoplasm and basal nuclei. The lamina propria of the stomach was composed of loose connective tissues interspersed between gastric glands together with connective tissue cells and smooth muscle fibers that separated the mucosa from the underlying submucosa.

All the layers of stomach were affected in rats exposed to overcrowding stress conditions. In muscularis the muscle fibers were disintegrated as shown in (Fig. 2) in comparison to that of control rats (Fig. 1). Abnormal numbers of blood vessels as well as congested blood vessels were recorded in submucosa (Fig. 3 and 4). Many histological changes were recorded in mucosa began from congestion in mucosa in addition to abnormal fundic glands in mucosa as shown in (Fig. 5).The effect increased and atrophy of mucosal glands was recoded (Fig. 5 and 6) . The blood vessels in different layers of fundus were congested as well as mononuclear cellular

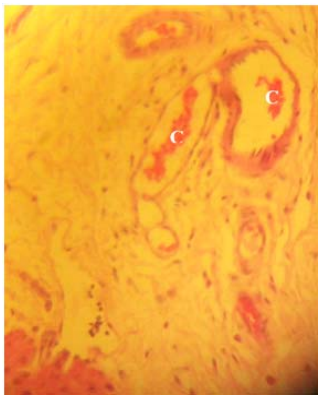

Fig. 4: Transverse section of treated rat stomach. Abnormal numbers of vaculature. C: congested blood vessels in submucosa. 400X, (H&E stain)

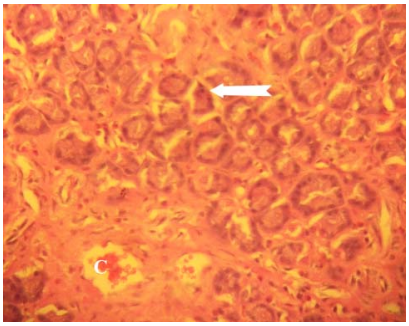

Fig. 5: Transverse section of treated rat stomach. C:congestion in mucosa, →Abnormal fundic gland in mucosa. 400X, (H&E stain)

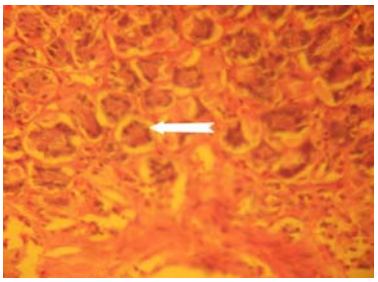

Fig. 6: Transverse section of treated rat stomach. C: congestion in mucosa, →Atrophy in mucosal gland. 400X, (H&E stain)

infiltration could be seen within the lamina propria (Fig. 6). The fundic mucosa of animals showed areas of discontinuity of surface mucosa and other areas of erosion at pits of the mucosa. There was distortion of normal architecture of fundic glands with invasion by mononuclear cells (Fig. 7). Moreover, the mucosa showed ulceration of the surface and vacuolation of some parietal cells (Fig. 8). Necrosis in mucosa (Fig. 8) was the prominent histological change when the effect reached the maximum.

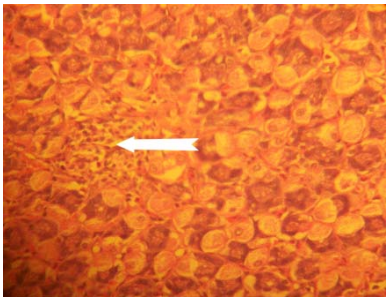

Fig. 7: Transverse section of treated rat stomach. →Neutrophil infiltration in mucosa. 400X, (H&E stain)

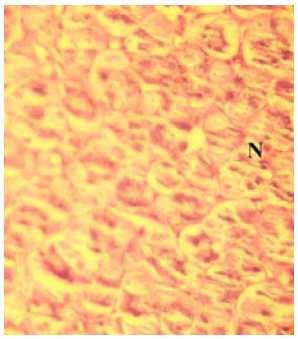

Fig. 8: Transverse section of treated rat stomach. N: necrosis in mucosa. 400X, (H&E stain)

DISCUSSION

The human populations of the world are rapidly becoming more crowded through excessive rates of population growth, urbanization and increased social and communicative contact. Many urban areas throughout the world are showing classic symptoms of crowded animal populations. Overcrowded areas were one of highest problems in the world. The authorities in different countries put plans and budgets for treating or even shrink this problem.

In this experiment the overcrowding stress resulted in marked affection of fundic glands of adult male albino rats. The findings of the present work were in consistence with the clinical findings of many investigators who reported in their study that prevalence of gastric symptoms like heart burn, epigastric pains, nausea and vomiting were increased in areas of dense populations (Csermely, 2000).

These findings were revealed as ulcerations, necrosis, desquamation and distorted fundic glands. These were in agreement with some researchers, James *et al*. (2008) who explained that crowding stress led to increased glucocorticoids as it disturbed hypothalamo-hypophyseal-pituitary axis. Glucocorticoids led to inhibition of cyclooxygenase enzymes that proved to be responsible for prostaglandins production. Several components of mucosal defense were influenced or mediated by prostaglandins. Other workers said that the mucosa of crowded subgroup showed marked reduction of oxidative phosphorylation enzymes so cell metabolism became severely affected (Nagaraja *et al*., 1997).

Recently it has been reported that overcrowding stress led to desquamation, necrosis and ulceration of gastric epithelium in adult male albino rats . Mononuclear cellular infiltrate and congested blood vessels were also noted in lamina propria. Parietal cells were decreased in number while mucous neck cells were increased in fundic glands. Acid mucous produced by mucous neck cells was increased more than neutral mucous produced by surface mucous epithelial cells. E cadherins were decreased in intensity in surface mucous epithelial cells led to disturbed barrier against gastric acidity (Mostafa, 2010).

Abu-Syed *et al.* (2008) reported that overcrowding could lead to many defensive mechanisms as increased number of mucous neck cells and decreased number of parietal cells. These are defensive mechanisms to overcome the state of damage generated by crowding stress. Galpin *et al.* (1992) postulated that crowding affected the mucous barrier and acidity of the stomach with subsequent bacterial invasion. These bacteria were chemotactic for mononuclear cells and also caused congestion of blood vessels. Emel and Saadet (2007) reported that crowded environment could alter the intercellular junctions due to alteration in PH of the gastric lumen and disturbed metabolism of surface epithelial cells.

Moreover, several possible mechanisms were considered to be involved in the mucosal damage by overcrowding. It was reported that crowding induced oxidative damage of surface epithelium (Emel and Saadet, 2007; Chaouloff and Zamfir, 1993). This postulation was confirmed by others who stated that crowding induced generation of reactive oxygen radicals in the fundic glands of the affected rats (Kovács and Csermely, 2007). Another etiological factor was also supposed by biochemical investigators who recorded in their study that a decline in activities of many endogenous antioxidant enzymes exacerbating oxidant mediated tissue injury (Xigeng *et al*., 2004). Bernatova *et al.* (2010) suggest in their study that chronic stress can markedly impair Nitric Oxide (NO) production and vascular function in conditions when NO production is slightly disturbed by a low dose of NO synthase inhibitor in normotensive rats.

In humans, overcrowding appears to result in a decline in task performance and deterioration in social behaviour. However, these effects are not universal and may depend on a rage of other factors including the amount of perceived control the person has over the situation. Additionally, overcrowding may have health effects. Some of these are attributable to the stress that may result from overcrowding; others to the fact that

crowded situations can facilitate the spread of disease. Some research has suggested that crowded conditions can detrimentally affect children's development. Goduka *et al.* (1992) found that crowding was an important predictor of both cognitive development and selfconcept in a sample of South African children. Similarly, Widmayer *et al.* (1990) found that overcrowding in the home was associated with poor psychomotor development in Haitian children. Crowding also seems to affect the quality of caregiver-child interaction. Fuller *et al.* (1993) found that crowded conditions were associated with lower levels of verbal stimulation and responsiveness by mothers towards their children.

CONCLUSION

It could be concluded that overcrowding stress lead to gastric mucosal damage represented by necrosis and ulceration. Moreover, the other layers of fundus were affected such as muscularis. Additionally, results also suggest caution in the housing of rats because an inappropriate crowding may affect results of the experiment significantly.

REFERENCES

Abu-Syed, M., M. Shigeru, S. Fumiko, T. Takashi and M. Ikunobu, 2008. Identification of M1 muscarinic receptor subtype in rat stomach using a tissue segment binding method and the effects of immobilization stress on the muscarinic receptors. Europ. J. Pharmacol., 599(1-3): 146-151.

Alfawwaz, R.A. and A.A. Alhamdan, 2006. The modulatory effect of n-acetyl cysteine supplementation on hepatic glutathione concentration and lipid peroxidation status in old rats fed a low-protein diet. Pak. J. Nutr., 5: 156-165.

Bateson, P., D. Barker, T. Clutton-Brock, D. Deb, B. D'Udine, R. A. Foley, P. Gluckman, K. Godfrey, T. Kirkwood, M.M. Lahr, J. McNamara, N.B. Metcalfe, P. Monaghan, H.G. Spencer and S.E. Sultan, 2004. Developmental plasticity and human health. Nature, 430: 419-421.

Bernatova, I., J. Kopincova and A. Puzserova, 2010. Chronic stress deteriorated nitric oxide production in wistar rats exposed to a low dose of L-NAME. Act. Nerv. Super Rediviva., 52(3): 200-205 .

Brown, G.W., 1993. Life events and affective disorder. Replication and limitations. Psychosom. Med., 55: 248-259.

Bugajski, A.J., A. Gadek-Michalska and J. Bugajski, 2006. The involvement of nitric oxide and prostaglandins in the cholinergic stimulation of hypothalamic-pituitary-adrenal response during crowding stress. J. Physiol. Pharmacol., 57: 463-477.

Chaouloff, F. and O. Zamfir, 1993. Psychoneuroendocrine outcomes of short term crowding stress. Physiol. Behav., 54: 767-770.

Csermely, P., 2000. Crowding Stress. In: Encyclopedia of Stress. In: Fink, G., (Ed.), Academic Press, 1: 601-603, Retrieved from: http://www. linkgroup. hu/ petercsermely. php#2000.

Cvijic, G. and J. Dordevic, 2003. Hypothalamo-pituitary-adreno-cortical and Sympatho-adrenomedullary systems in stress response. Jugoslov. Med. Biohem., 22: 3-10 .

Delaunay, F., A. Khan, A. Cintra, B. Davani, Z.G. Ling, A. Andresson, C.G. Ostenson, J.A. Gustaffsson, S. Efendic and S. Okert, 1997. Pancreatic β cells are important targets for the diabetogenic effects of glucocorticoids . J. Clin. Invest.,100: 2094-2098.

Dorko, F., M. Kocisova, M. Sirotakova, K. Schmidtova, K. Lovasova and E. Dorko, 2000. The localization of NADPH-diaphorase positive cells and autonomic innervation of the rat thymus. Pak. J. Biol. Sci., 3(5): 759-762.

Eichenbaum, H., 1997. How does the brain organize memories. Science, 277: 330-332.

Emel, S. and G. Saadet, 2007. Immobilization stress in rat tissues: Alterations in protein oxidation, lipid peroxidation and antioxidant defense system. Com. Bioch. Phys. C, 144(4): 342-347.

Fuller, T.D., J.N. Edwards, S. Vorakitphokatorn and S. Sermsri, 1993. Household crowding and family relations in bangkok. Soc. Probl., 40: 410-430.

Gadek-Michalska, A., J. Spyrka and J. Bugajski, 2005. Psychosocial stress affects the involvement of prostaglandins and nitric oxide in the lipopolysaccharide- induced hypothalamic-pituitary-adrenal response. J. Physiol. Pharmacol., 56: 287-298.

Galpin, O., C. Whitaker and A. Dubiel, 1992. Helicobacter pylori infection and overcrowding in childhood. Lancet, 339: 619.

Goduka, Ivy N., A.D. Poole and A.P. Lillian, 1992. A comparative study of black South African children from three different contexts. Child Dev., 63(3): 509-525.

James, O.M., J.M. Dambrosia and A. Judith, 2008. Effect of housing density on reproductive parameters and corticosterone levels in nursing mice. J. Am. Assoc. Lab. Anim. Sci., 47(2): 9-15.

Kovács, L. and P. Csermely, 2007. Crowding Stress. In: Fink, G., (Ed.), Encyclopedia of Stress, 2nd Edn., Academic Press, Oxford, 1: 669-672. Retrieved from: http://www.linkgroup.hu/docs/pcs2/210-07crowding-stress.pdf.

Kumar, R.S., S.N. Narayanan and S. Nayak, 2009 . Ascorbic acid protects against restraint stress-induced memory deficits in wistar rats. Clinics, 64(12) :1211-1217.

Mostafa, H.K.K., 2010. Effect of the overcrowding on fundus of stomach in adult male albino rats with special reference to the protective role of Bran. Egypt. J. Histol., 33(3): 479-488.

Nagaraja, H.S. U.J.A. D'souza and P.S. Jeganathan, 1997. Effect of isolation and crowding stress on some selected physiological and biochemical parameters in albino rats. Biomedicine, 17(2): 85-90.

Nagaraja, H. and P. Jeganathan, 2003. Effect of acute and chronic conditions of over-crowding on free choice ethanol intake in rats. Indian J. Physiol. Pharmacol., 47(3): 325-331.

Nayanatara, A.K., H.S. Nagaraja, C. Ramaswamy, K. Bhagyalakshmi, B.M. Ramesh, G.K.M. Damodara and S.M. Venkappa, 2009. Effect of chronic unpredictable stressors on some selected lipds parameters and biochemical parameters in Wistar rats. J. Chinese Clin. Med., 4(2): 92-97.

Roman, E., P. Hyytia and I. Nylander, 2003. Maternal separation alters acquisition of ethanol intake in male ethanol preferring AA rats. Alcohol. Clin. Exp. Res., 27: 31-37.

Saalu, L.C., P.I. Jewo, I.O. Fadeyibi and S.O. Ikuerowo, 2008. The effect of unilateral varicocele on the contralateral testicular histo-morphology and function in rattus norvegicus. J. Med. Sci., 8: 654-659.

Saalu, L.C., P.I. Jewo, O.E. Yama and J.A. Oguntola, 2011. Evaluation of the histomorphometric evidences of hydroxyurea-induced testicular cytotoxicity in sprague-dawley rat. J. Pharmacol. Toxicol., 6: 409-417.

Sapolsky, R.M., 1992. Stress, the Aging Brain and the Mechanisms of Neuron Death. MIT Press, Cambridge, pp: 603, ISBN 0-262-19320-5.

Torres, R.L., I.L.S. Torres, G.D. Gamaro, F.U. Fontella, P.P. Silveira, J.S.R. Moreira, M. Lacerda, J.R. Amoretti, D. Rech, C. Dalmaz and A.A. Belló, 2004. Lipid peroxidation and total radical-trapping potential of the lungs of rats submitted to chronic and subchronic stress. Braz. J. Med. Biol. Res., 37: 185-92.

Widmayer, S.M., L.M. Peterson, M. Lamer, S. Carnahan, A. Calderon, J. Wingerd and R. Marshall, 1990. Predictors of haitian-american infant development attwelve months. Child Dev., 61: 410-415.

Xigeng, Z., L. Yonghui, L. Xiaojing, X. Lin, W. Dongmei, L. Jie, Y. Xiaoyan and S. Nan, 2004. Social crowding sensitizes high-responding rats to psychomotor-stimulant effects of morphine. Pharmacol. Biochem. Behav., 79: 213-218.