Current Research Journal of Biological Sciences 4(1): 55-59, 2012
ISSN: 2041-0778

Submitted: March 01, 2011 Accepted: November 25, 2011 Published: January 20, 2012

Experimental Study of H120 Vaccination Efficacy on Respiratory Tract in Broiler Chickens

[1]Yousef Doustar, [2]Adel Feizi, [3]Mehrdad Nazeri and [4]Amirreza Ebadi
[1]Department of Pathobiology,
[2]Department of Clinical Sciences,
[3]Young Researchers Club, Tabriz Branch, Islamic Azad University, Tabriz, Iran
[4]Department of Microbiology, Ahar Branch, Islamic Azad University, Ahar, Iran

Abstract: Infectious bronchitis is an acute viral disease with high contagious and mortality among chicks. Apparent symptoms of Infectious bronchitis in chicks are tracheal respiration and nasal discharges. The objective of this study was to assessment H120 vaccination efficacy on respiratory tract in Broiler Chickens. In this study, 60 Ross 308 commercial strain one-day old chicks free of *Mycoplasma galisepticum* and mycoplasma synoviae were divided into two, control and treatment, groups and three sub groups of 10 chicks. The treatment sub groups were vaccinated against bronchitis on the first day. All of chicks were placed in the hatchery and 20 mL of 10% formalin. H120 lyophilized vaccine of massachoset strain prepared in Razi institute was used for vaccination. The results of the present study show that spraying form of vaccination has a high reaction. So it is recommended that this kind of vaccination is used carefully. In the present study the aftermath of H120 vaccine spray was observed and recorded during Histopathological studies.

Key words: Broiler chickens, infectious bronchitis, respiratory tract

INTRODUCTION

Infectious bronchitis was observed for the first time in North Dakota in 1930. Infectious bronchitis at first was recognized as a young chicks' disease. The disease was observed in semi matured and lying flocks later on. Incidence and economical importance of the disease resulted in some efforts in order to prevent the disease occurrence. Through these efforts the lying flocks in growth stage were exposed to the disease. Such an effort by Van Eck and Goren (1991) was conducted successfully which was the first step forward to vaccination programs developments. Wang *et al*. (1993, 1999) reported the Connecticut strain in 1993 and Massachoset strain in 1999 (Fulton *et al*., 1993; Hopkins and Yoder, 1984; Bilgili, 1999).

The increasing need for food especially for protein on one hand and quality, fast growth and high poultry yield on the other hand cause to fast growth and development of poultry industry across the world. In existence breeding systems the large numbers of birds are raised in a small space which causes the susceptibility of chicks to environmental factors. The too crowded and especial conditions of breeding have caused the incidence of fatal disease in this industry which may threat the life of strategic industry and make heavy losses to it. One of the economically important diseases is infectious bronchitis which is very important due to worldwide incidence, fast propagation and various serotypes. The caused losses have been significant either directly on chicks and matured birds or due to creating some conditions for other diseases. The multiplicity of the disease's serotypes makes the prevention very difficult. In any case, vaccination in broiler and lying flocks is one of the efficient preventing ways. Broiler flocks are usually vaccinated with extenuated spray vaccine but the main problem about this kind of prevention is the occurrence of respiratory problems. With regard to the hygienic, management and high incidence of *Mycoplasmosis, galisepticum* and *Mycoplasma synoviae* in Iran, the possibility of the disease severity is high. For this reason the broilers' breeders don't demonstrate any tendency for bronchitis vaccination which may cause serious problems. The aim of present study was to determination of complications of H120 vaccination pathologically in broiler chickens.

MATERIALS AND METHODS

Present study was carried out in most important farms of east Azerbaijan Province during summer 2011. 60 Ross 308 commercial strain one-day old chicks free of *Mycoplasma galisepticum* and mycoplasma synoviae were divided into two, control and treatment, groups and three sub groups of 10 chicks. The treatment sub groups

Corresponding Author: Yousef Doustar, Department of Pathobiology, Faculty of Veterinary Medicine, Tabriz Branch, Islamic Azad University, Tabriz, Iran

Table 1: Comparison of observed pathologic lesions in under studied groups

Tissue injury Sub group (n = 10)	Mononuclear invasion in tracheal epithelium and bronchioles	Ciliary falling of tracheal epithelium and bronchioles	Separation of tracheal epithelium and bronchioles	Hyperplasia of tracheal epithelium and bronchioles	Mononuclear invasion, hyperemia and hemorrhage in pulmonary parenchyma	Significant differences
Control group on 5th day	0	0	0	0	0	
Treatment group on 5th day	+	+	0	0	0	
Control group on 10th day	0	0	0	0	0	
Treatment group on 10th day	++	++	++	++	+++	# – *
Control group on 21th day	0	0	0	0	0	
Treatment group on 21th day	+++	+++	++	+++	++++	**

Zero: normal tissue; +1: little injury; +2: moderate injury; +3: sever injury; +4: more sever injury; *: Significant difference with control and treatment subgroups on 5th day ($p<0.05$); **: Significant difference with control and treatment subgroups on 5th day ($p<0.01$); #: Significant difference with treatment subgroups on 21th day ($p<0.05$)

were vaccinated against bronchitis on the first day. All of chicks were placed in the hatchery and 20 mL of 10% formalin.

H120 lyophilized vaccine of massachoset strain prepared in Razi institute was used for vaccination. This vaccine contains extenuated virus of Massachoset strain infectious bronchitis cultured in under vacuum lyophilized SPF eggs' embryos. Any vaccine dosage contains a titer approximately $10^{3.5-4}EID^{50}$ after dissolving in a solution. All stages of the chain consisting transmission, maintenance and vaccine preparation was observed carefully. 2000 dosage vial dissolved in a cold solution and was poured in a spraying container. Treatment sub groups were vaccined by spraying (the diameter of spraying machine was 150-1000 micron) such that the chicks only were moistened. The period of the experiment was 3 weeks and feeding as well as keeping conditions were according to standards. The temperature was 30, 28 and 26ºC at the first, second and third weeks, respectively. During the breeding period there was no mortality. Sampling was done on fifth, tenth and twenty first days from the first to third sub treatment groups and control groups, identically. So, the chicks were anesthetized by electrical shock such that one end of a 220 v wire was connected to the foot and another end was connected to the beak (Brown and Brace well, 1988). The chicks were autopsied carefully and the upper part of respiratory tract and lungs were separated and were placed in a 10% Formalin in order to stabilization. Histopathological sections were obtained with 5 micron thickness and were studied following staining with hematoxilin - eosin. Various pathologic lesions observed based on occurrence severity were ranked from zero to +4 (zero for normal tissue, +1 for little injury, +2 for moderate injury, +3 for sever injury and +4 for very sever injury). Histological data were analyzed statistically bt non parametric U test of Mann-Whitney. $p<0.05$ was regarded as significant.

RESULTS

The comparison of pathologic lesions in understudied groups has been provided in Table 1.

In tissue sections obtained from trachea of understudied control sub group the Focal falling of ciliary was observed. Bronchial mucous was edematous, hyperemia and contained mono nuclear inflammatory cells. In control sub-group trachea the spread falling of ciliary along with mucosal exudation discharge, moderate proliferation of cupule shape cells and moderate invasion of mononuclear cells was observable.

Separation and falling of tracheal epithelial tissue and bronchial were apparent in some parts. In pulmonary parenchyma there were edema, hyperemia, propagated hemorrhage and relatively vast invasion of mononuclear cells in pulmonary connective tissue were significant. In sub control group pulmonary the vast falling of ciliaries was observed along with sever invasion of mononuclear inflammatory cells, moderate and propagated loss of epithelial tissue and cupular shape cells hyperplasia on 21st day. Hyperemia, hemorrhage, relatively severs pneumonia and formation some nodes in pulmonary parenchyma were another pathological findings. In pulmonary epithelial tissue the bronchioles and lung in sub control groups had not any pathological changes (Fig. 1 to 4).

DISCUSSION

Using the extenuated infectious bronchitis vaccine in order to prevent the disease is a common issue in Iran that the time and way of its using is different and depends on management. But noticeably the use of vaccine on first day in the form of spraying is advised which is caused to some problems. Immunity responses and intensity of reaction depend on the prescription. The chicks which received non-respiratory vaccine such as drinking vaccines show less reactions. Based on the results

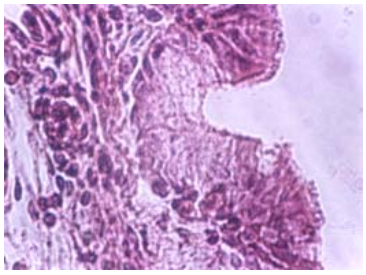

Fig. 1: Microscopic view of broilers trachea in sub control group on 5th day. Focal and little falling of epithelial tissue ciliaries is evident (H&E staining, ×40 magnification)

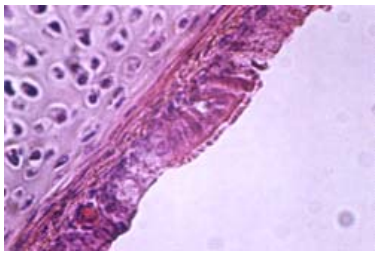

Fig. 2: Microscopic view of broilers trachea in sub treatment group on 10th day. Propagated falling of epithelial tissue ciliaries is evident (H&E staining, ×40 magnification)

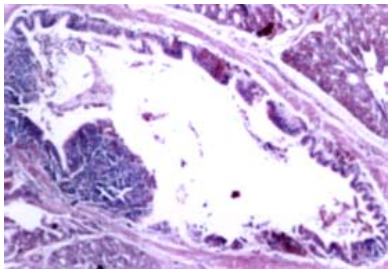

Fig. 3: Microscopic view of broilers pulmonary in sub treatment group on 21st day in which inflammatory changes in bronchiole is evident. Edema and mononuclear cells' invasion along with inflammatory exudation in internal tract of respiratory bronchiole (H&E staining, ×40 magnification)

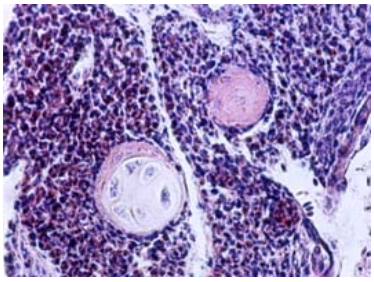

Fig. 4: Microscopic view of broilers pulmonary in sub treatment group on 21st day in which gristle nodes were seen in pulmonary tissue (H&E staining, ×400 magnification)

obtained from this survey the falling of ciliaries in epithelium, mucosal hyperplasia and inflammatory changes in respiratory bronchiole demonstrate the following bronchitis resulted in spraying vaccination. The presence of some disorders in muco-ciliary system resulted in decreasing immunity mechanisms which the tracheal epithelium can be infected and finally the pathogens can spread to other tissues. In affected poultries the heterophils increase as the first response but that increase can't prevent viral proliferation. In fact this kind of invasion involves in tracheal epithelium injury. Focal chondroidal nodes in lung can be resulted of chondrocyte embolic focuses. These changes also can be associated with weal ventilation, high carbon dioxide and ammoniac concentration and the high dust level. Existence of cartilage focuses can be due to formalin used in hatchery. These tissue injuries can cause indirect physiologic disorders in bird's respiratory system. Based on the present study, some inflammatory processes begin in respiratory tract which can cause secondary pathogens in chicks if the environmental conditions don't be controlled (Wang *et al*., 1999; Wang *et al*., 1993).

Although the information about single factors of poultry's respiratory disease is very much, its simple infections are regarded as exceptions. Under farm condition, infections are complicated with multiple bacterial, viral factors as well as immunity destroying factors and unfavorable environmental conditions. Furthermore, some reactions caused by vaccination programs can play the main role in respiratory disease development. Maybe the best example understanding multiple respiratory infections is the involvement of mycoplasma. Although non-complicated infections by *Mycoplasma galisepticum* in turkeys resulted in respiratory symptoms and air sacs inflammation, simple infection by *Mycoplasma galisepticum* or *Mycoplasma synoviae* in poultries cause moderate sub clinical disease. Interaction of these viruses with Newcastle or infectious bronchitis viruses resulted in *Mycoplasma galisepticum* infections' increase. Such interaction occurs with *Mycoplasma synoviae* and the intensity of respiratory viruses maybe influence on the *Mycoplasmic infections*. Coincident challenge of *Mycoplasma synoviae* with vaccine strain of infectious bronchitis causes more moderate respiratory disease compared with farm strain of infectious bronchitis virus. Also, the chicks passaged with vaccine virus demonstrate more sever inflammatory lesions in air sacs compared with those received original vaccine (Di-Matteo *et al*., 2000; Kleven and Glisson, 1997; Riddell, 1987).

The period of expose to infectious factors is important in complex infections' pathogenesis. Usually infection by respiratory viruses and *Mycoplasmic infection* occur coincidentally so able to act synergistically. Poultry non-infected by *Mycoplasma demonstrate* a moderate reaction following infection by infectious bronchitis virus compared with poultry which

infected by *Mycoplasma galisepticum* chronically. Triple interaction among vaccine virus (Newcastle or infectious bronchitis virus), mycoplasma (*Mycoplasma galisepticum or Mycoplasma synoviae*) and Escherichia coli causes more sever diseases compared with their twofold interaction. The diseases resulted of two of mentioned factors is more moderate compared with existence of three factors and challenge only with one factor causes no disease or a moderate one. The poultry which expose to infectious bronchitis and *Mycoplasma galisepticum* don't have susceptibility to Escherichia coli until 8 days after expose to virus (Van Eck and Goren, 1991; Kleven and Glisson, 1997).

Mycoplasma galinarum which is as a non pathologic agent will cause air sacs' inflammation in chicks if accompanied with Newcastle or infectious bronchitis vaccine. The interaction among Escherichia coli and other respiratory factors occurs in absence of mycoplasma. Exposing to infectious bronchitis or Escherichia coli will cause to increase the clinical symptoms and mortality. Such challenges are used for evaluating produced immunity (Kleven *et al*., 1978; Smith *et al*., 1985). The harmful factors for immunity, especially Gambro, in poultry cause top increase their susceptibility to respiratory infections. The challenge of poultry against Gambro virus resulted in unfavorable effects on antibody reaction and resistant against Newcastle, infectious bronchitis, *Mycoplasma synoviae*, aspergillus flavus and fumigatus. Controlling the Gambro disease in farm for controlling respiratory diseases in broilers is an essential factor. Although Mark disease has been known as a harmful factor for immunity, its role in respiratory diseases has not been studied yet. In any case the poultry infected by Mark diseases virus are not able to react well to *Mycoplasma synoviae* compared with healthy poultry. Respiratory disease and air sacs' inflammation increase during cold seasons but very few studies has been done about the effect of temperature on respiratory sensitivity. The poultry which were challenged with mycoplasma synoviae and infectious bronchitis virus, demonstrated extensive lesions of air sacs in 7-10ºC compared with 24-29ºC. All active viral vaccines proliferate in birds and create some degrees of cellular injuries. Clinical symptoms of this viral proliferation and its pathologic results are called vaccine aftermath. Respiratory viral active vaccines cause to immunity reaction while having less injuries on healthy bird in a good condition. In a stress condition such as cold, vaccine aftermath of infectious bronchitis or Newcastle begins 3-5 days following vaccination, clinically and continues further a period of 3-5 days. If the aftermath of vaccine is more sever or longer than the normal status, it is called rolling the vaccine aftermath or simply severs reaction of vaccination. Sever and prolong reactions of vaccine following the use of Newcastle or infectious bronchitis's active vaccine occur very common in commercial poultry. Flocks which demonstrate sever reaction to vaccine are affected by respiratory coli bacillus. Most of poultry hygienic specialists believe that respiratory diseases resulted of respiratory viral vaccines interaction with *Escherichia coli* are very common in commercial birds (Kleven and Glisson, 1997; Smith *et al*., 1985).

Various conditions cause to increase the severity of vaccine aftermath. Using Formalin in hatchery and vaccination on first day by infectious bronchitis causes to the condition intensification. In a study the chicks which received only the vaccine demonstrated a moderate falling of epithelial tissue, enlargement of ciliary cells and microvillia cells one day following vaccination while the groups which received formalin gas in hatchery showed more sever cell falling. It has been demonstrated that immunity damage increases the ability of pathogen to produce a disease. On the other hand the immunity damage causes to slow the ability of bird for limiting the proliferation of vaccine virus and causes sever reaction of vaccine (Wang *et al*., 1993).

Vaccination of the birds which their respiratory tract infects with other pathogens causes a sever reaction; its important example is *Mycoplasma galisepticum* and *Mycoplasma synoviae*. The birds infected with Escherichia coli have also the same condition. Newly hatched chicks in a high infected environment by Escherichia coli may demonstrate a sever reaction following use of active Newcastle or infectious bronchitis vaccine. Some of active Newcastle, infectious bronchitis and larengotrakeit vaccines may have increased intensity if have the propagation chance. This kind of vaccine aftermath can occur for a long period with more severity. Environmental factors can influence on the severity of vaccine aftermath. Ammonia and dust interfere with respiratory pathogens and increase the severity of the disease. Ammonia with a concentration of 25 or 50 ppm leads to weight loss, decrease of food consumption, pulmonary enlargement and increase of air sacs in poultry which have been challenged with infectious bronchitis virus. Incorrect use of respiratory viral vaccines can cause to increase the severity of reaction. Using spray form of vaccination with very fine drops (less than 150 micron) make available the virus for deep respiratory parts which leads to inordinate viral proliferation in lungs and air sacs as well as strong immunity (Kleven and Glisson, 1997; Kling and Quarles, 1974).

Vaccination with aerocell following challenging with *Mycoplasma synoviae* leads to more sever inflammation of air sacs. Since respiratory vaccine viruses are available in various levels, correct use of vaccine for especial conditions is important. Very young birds are vaccinated with more extenuated vaccines while the older birds are vaccinated with less extenuated one. When the chicks are vaccinated with active virus of Newcastle or infectious bronchitis vaccine virus strain of H52, a sever reaction occurs (Di-Matteo *et al*., 2000; Kleven *et al*., 1978).

The results of the present study show that spraying form of vaccination has a high reaction. So it is recommended that this kind of vaccination is used carefully. In the present study the aftermath of H120

vaccine spray was observed and recorded during Histopathological studies. Although H120 vaccine spray is the best vaccination method for controlling infectious bronchitis, some observations can decrease and control the relative aftermaths; they are as follows:

- Spraying with large drops (more than 150 micron)
- Non-using of spray in Mg^+ chicks (*Mycoplasma galisepticum*)
- Non-using of spray in stress condition such as cold

ACKNOWLEDGMENT

Thanks to research assistance branch of Tabriz Islamic Azad University.

REFERENCES

Bilgili, S.F., 1999. Recent advances in electrical stunning. Poult. Sci., 78: 282-286.

Brown, A.J. and C.D. Brace well, 1988. Effect of repeated infections of chickens with infectious bronchitis viruses on the specifity of their antibody responses. Vet. Rec., 122: 207-208.

Di-Matteo, A.M., M.C. Snoez, C.M. Plano and I. Von Lawzewitsch, 2000. Morphologic observations on respiratory tract of chickens after hatchery infectious bronchitis vaccination and formaldehyde fumigation. Avian Dis., 44: 507-518.

Fulton, R.M., W.M. Reed and H.L. Thacker, 1993. Cellular responses of the respiratory tract of chickens to infection with Massachusetts 41 and Australian T infectious bronchitis viruses. Avian Dis., 37: 951-960.

Hopkins, S.R. and H.W. Yoder, 1984. Increased incidence of airsacculitis in broilers infected with *Mycoplasma synoviae* and chicken passaged infectious bronchitis virus. Avian Dis., 28: 386-396.

Kleven, S.H. and J.R. Glisson, 1997. Multicausal Respiratory Disease; Disease of Poultry. 10th Iowa State University Press, pp: 1008-1010.

Kleven, S.H., C.S. Edison and O.J. Fletchers, 1978. Airsacculitis induced in broilers with a combination of *Mycoplasma galisepticum* and respiratory viruses. Avian Dis., 22: 707-716.

Kling, H.F. and C.L. Quarles, 1974. Effects of atmospheric ammonia and the stress of infectious bronchitis vaccination on leghorn males. Poult. Sci., 53: 1161-1167.

Riddell, C., 1987. Avian histopathology. American Association of Avian Pathology. Kennett Square, PA, pp: 119-120.

Smith, H., J. Cook and Z. Parsell, 1985. The experimental infection of chickens with mixtures of infectious bronchitis virus and *Escherichia coli*. J. Gen. Virol., 66: 777-786.

Van Eck, J.H. and E. Goren, 1991. An Ulster 2C strain derived Newcastle disease vaccine: Vaccinal reaction in comparison with other lentogenic Newcastle disease vaccines. Avian Pathol., 20: 497-507.

Wang, L., D. Junker and E.W. Collisson, 1993. Evidence of natural recombination within the S1 gene of infectious bronchitis virus. Virology, 192: 710-716.

Wang, L., D. Junker, L. Hock, E. Ebiary and E.W. Collisson, 1999. Evolutionary Implications of genetic variation in the S1 gene of infectious bronchitis virus. Virus Res., 34: 327-338.