Current Research Journal of Biological Sciences 4(1): 90-95, 2012
ISSN: 2041-0778

Submitted: November 18, 2011 Accepted: December 20, 2011 Published: January 20, 2012

Geometric and Histopathologic Assessment of Yarrow Extracts (*Achillea millefolium*) and on Healing of Experimental Skin Wounds and its Comparison with Zinc Oxide on Rats

[1]Ali Rezaie, [2]Daryoush Mohajeri, [3]Mohammadreza Valilou, [1]Ghafour Mousavi, [4]Mehrdad Nazeri, [5]Babak Mohammadi and [5]Solmaz Zakhireh
[1]Department of Clinical Science, Tabriz Branch, Islamic Azad University, Tabriz, Iran
[2]Department of Pathobiology, Tabriz Branch, Islamic Azad University, Tabriz, Iran
[3]Department of Veterinary Medicine, Shabestar Branch, Islamic Azad University, Shabestar, Iran
[4]Young Researchers Club, Tabriz Branch, Islamic Azad University, Tabriz, Iran
[5]Department of Basic Science, Faculty of Chemistry, Ahar Branch, Islamic Azad University, Ahar, Iran

Abstract: Skin wound healing especially when it occurs on the face or somewhere important for cosmetic reasons, is very significant physiological procedure. It is quite obvious that promoting this healing is important too. In this study we tried to compare the effects of *Achillea millefolium* and Zinc oxide on secondary intentioned open-wound healing in rats. Zinc oxide is being used worldwide as an absorbent and protective compound. Its pharmacological properties are wide and its non-toxic material allows it to be used as a routine skin care substance. In current study, 70 female wistar rats where included in 5 groups. Full thickness Incisional wound with 23 mm diameter was made with surgical scissors and scalpel. The whole operation was taking place under general Anesthesia and analgesia circumstances. After making surgical wounds, rats are treated as mentioned in the text. Rats are observed for 28 days for wound closure process and inflammatory conditions taking place in wound. Biopsy intervals are 0 (the day of surgery), 3, 7, 14, 21 and 28th day after surgery. In these certain days rats were euthanized and biopsies of wound sites were obtained. Wounds areas are also measured by Scion Image ™ software daily. At last, all data were analyzed using SPSS statistics ver.17. As a result, *Achillea millefolium* at the dose of 10% has significant healing properties compared to Zinc oxide. These data were validating under confidence surface of 95% ($p<0.01$).

Key words: Achillea millefolium, healing, rats, skin wounds, zinc oxide

INTRODUCTION

The genus Achillea (Asteraceae), named after the mythological Greek warrior Achilles, who used Achillea species for healing wounded-soldiers during the Trojan War (Cheers, 1999). The genus Achillea comprises of ~85 species, most of which are endemic to Europe and the Middle East. Turkish flora possesses 42 Achillea species and 23 of them are endemic (Duman and Achillea, 2000). These species have some interesting properties and are used in cosmetics, fragrances and agriculture, for example, plant protection (Senatore *et al*., 2005). Some Achillea species have been known to be ethnopharmacologically used in folk remedies for various purposes such as hemorrhoid and wound healing (Baytop, 1999). Herbal teas prepared from some Achillea species are very often used in folk medicine as diuretic, for abdominal pain, against diarrhea, flatulence and emmenagog, moreover for wound healing purposes (Fujita *et al*., 1995; Honda *et al*., 1996; Yesilada *et al*., 1993). Achillea biebersteinii is locally named yarrow, and other species widely used as a folk remedy to treat abdominal pain, wounds and stomachache as well (Sezik *et al*., 2001; Baytop, 1997). A. biebersteinii Afan. [Asteraceae, Section: Filipendulinae (D.C.) Boiss] (syn. A. micrantha) is a perennial herb, villose, stems erect, simple or branched from the base; 30-60 cm high; leaves up to 10 cm, oblong-lanceolate in outline, pinnatisect into numerous narrow segments, segments divided into minute linear-lanceolate mucronate lobes; the heads are radiate, in large dense compound corymbs; involucre 4-5 mm, oblong-ovoid; flowering period, April-May. Several biological activity studies have been performed on various Achillea species, including antibacterial, antioxidant, anti-inflammatory and antispasmodic activities (Karamenderes and Apaydın, 2003; Candan *et al*., 2003; Al-Hindawi *et al*., 1989; Skocibusic *et al*., 2004).

Zinc oxide is an inorganic compound with the formula ZnO. It is a white powder that is insoluble in water. Zinc is an essential trace element of which about 2 g is found in the adult human body. At least 200 enzymes in different biological systems are dependent on the presence of the zinc ion. Among these zinc-dependent enzymes, DNA and RNA polymerases are crucial during

Corresponding Author: Ali Rezaie, Department of Clinical Science, Tabriz Branch, Islamic Azad University, Tabriz, Iran

tissue repair as they affect cell proliferation and protein synthesis. In accordance with the biochemical role of zinc a reduced synthesis of DNA, reduced deposition of granulation tissue, decreased tensile strengths in skin incisions, and delayed closure rates in excised wounds in zinc-deficient rats have been demonstrated (Sandstead *et al*., 1970; Prasad and Oberleas, 1974). Zinc supplementation restored to normal the tensile Strengths of the incisional and healing rates of the excisional wounds (Sandstead *et al*., 1970). It has been clinically shown that the healing of leg ulcers is delayed in patients with subnormal serum-zinc levels (Haley, 1979). Zinc given as oral and topical zinc sulfate or as topical zinc oxide normalizes impaired healing ability in these patients (Haley, 1979; Golden *et al*., 1980; Stromberg and Agren, 1984).

The aim of the present study was to investigate the *in vivo* wound healing activity of *A. millefolium* in order to elucidate traditional use of this plant from the scientific point of view.

MATERIALS AND METHODS

Animals: This study was conducted in Islamic Azad university research center during summer 2011. In this study, 70 male wistar rats weighted 210±10 g and aged 12 weeks old were selected. All animals were kept in same situation (temperature 24ºC and humanity 70%) and food and water were provided ad libitum.

Pre-operation measures: The operation (induction wound in the skin) required general anesthesia, analgesia and muscle relaxation. In term, we used of Ketamine (10%, 60 mg/kg) and xylazine (2%, 10 mg/kg) through IM injection to induction of anesthesia and pre-operation drugs, respectively. To prevention of drugs side effects, liquid therapy with dextrose 5% at the dose of 50-100 mg/kg/day was exerted immediately after induction of anesthesia.

Operation measures: After preparation the dorsal skin of rats (distinct between scapula to ischial tuberosity), a wound in circle shaped with 7 mm in diameter and by biopsy punch were inducted. In this study rout of wounding was excisional wounding that in way epidermis, dermis, hypoderm and Panniculus Carnosus completely were removed. After wounding, rats were divided into 5 groups of 15.

Group 1: received high doses (20%) of herbal extract
Group 2: received low doses (10%) of herbal extract
Group 3: as positive control group received zinc oxide 20%
Group 4: as negative control group received eucerin
Group 5: as control not received any drug

Samples were fixed in the formalin 10% and sent to pathology laboratory.

Post-operation measures: After biopsy and washing wound area with normal saline, all drugs were administrated as local way by an applicator in the wound area. This administration continued for 21 days.

Sampling: On days 0, 3, 7, 14, 21 and 28 of research, samples as tissue specimens from biopsy areas were collected and sent to pathology laboratory. Sampling was done under anesthesia condition and this anesthesia was induced by Ketamine and Rampon. Sampling was exerted by scalpel. Samples were fixed into formalin 10%. In lab, after processing and staining to H&E method slides were achieved. Slides were investigated by a light microscope.

Statistical analysis: The Statistical Package for Social Sciences (SPSS Inc., Chicago, IL, USA), version 17.0, was used for statistical analysis. All data are presented as mean ±SEM. Before statistical analysis, all variables were checked for normality and homogeneity of variance by using the Kolmogorov-Smirnoff and Levene tests, respectively. The data obtained were tested by ANOVA followed by Tukey's post-hoc multiple comparison test. $p<0.05$ was considered statistically significant.

RESULTS

Geometric findings: On the first day of trial, ulcer size in all five groups showed a significant increase compared to day zero. On the second day, wound size in high dose treatment group was reduced significantly. So that this finding was observed in low dose and zinc oxide groups, control group and eucerin group on days 3, 4 and 5 respectively. Over seven days until day 7, according to the size of the wound, the highest rate of wound shrinkage was observed in high dose, low dose, zinc oxide, eucerin and control group respectively. On day 21, maximum and minimum shrinkage was observed in low dose and control groups, respectively.

Histopathologic findings: On day 3 in high dose treatment group, pustule covered the wound but still retains its moisture. Re-epithelialization is seen from wound sides. Inflammatory cells also are existed. Infiltration of fibroblasts into the connective tissue was obvious. In low dose treatment group, wound was covered by pustule consist of fibrin and blood cells and purulent materials such as neutrophils and RBC remnants. Clod on the wound had more and low inflammatory cells than high dose and zinc oxide groups, respectively. In zinc oxide group, wound was covered by thick and keratinous pustule. Wound was filled with granular connective tissue and hyperemia was obvious. In eucerin group, hemorrhage in the profound layers was obvious and was not seen any pustule and healing has not been started (Fig. 1).

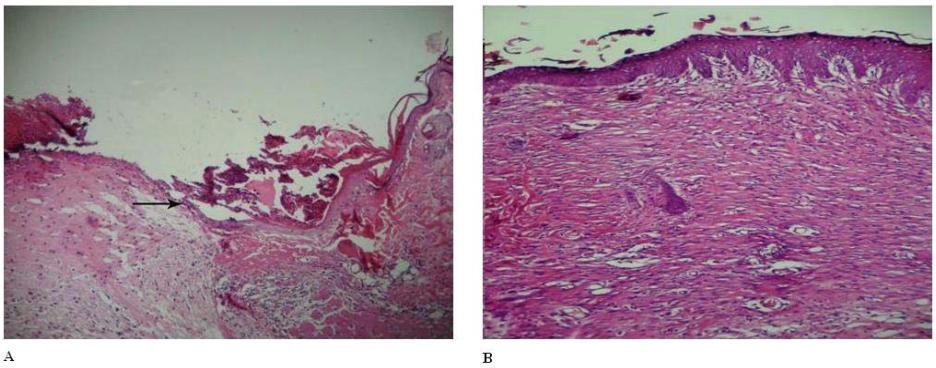

Fig. 1: (A) Microscopic view from wound area in healing from high dose group on day 3. Arrow shows Re-epithelialization from wound sides, (B) Microscopic view from wound area in healing from high dose group on day 3. H&E 100x

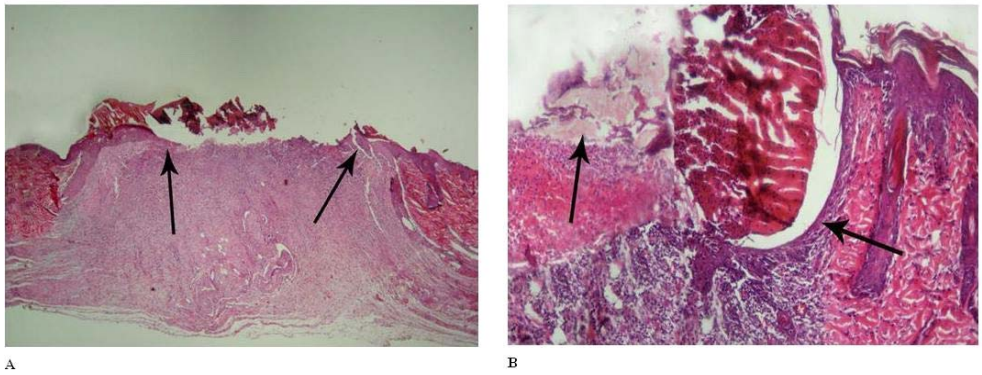

Fig. 2: (A) Microscopic view from wound area in healing from high dose group on day 7. Arrows shows Re-epithelialization from wound sides. H&E 40x, (B) Microscopic view from wound area in healing from group 4 on day 7. Arrows shows expanding of epithelial cells into the pustule. H&E 100x

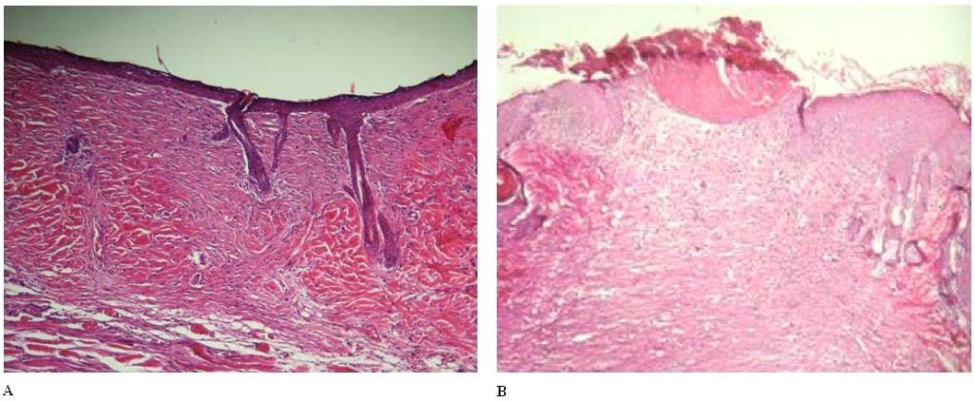

Fig. 3: (A) microscopic view from wound area in healing from group 2 on day 14. H&E 80x, (B) microscopic view from wound area in healing from group 3 on day 14. H&E 80x

On day 7, in high dose treatment group, in some cases, pustules on the wound still have not been completely dried but wound area has been filled with multicellular and vascular granular tissue. Epithelial regeneration continues and the amount of inflammatory cells is also greatly reduced. In low dose treatment group, wound surface covered by pustules and internal space of wound in the middle parts filled by fibrinous and granular connective tissue and inflammatory and purulent cells are seen between fibrin and connective tissue and granular

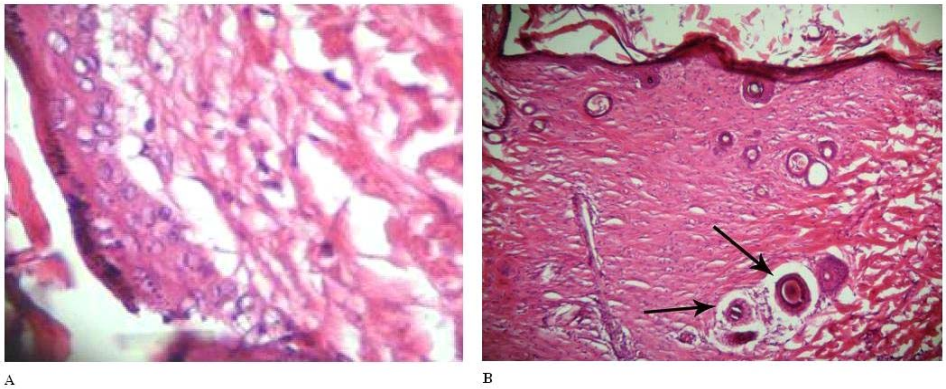

Fig. 4: (A) microscopic view from wound area in healing from group 2 on day 21. H&E 220x, (B) microscopic view from wound area in healing from group 3 on day 21. Arrows shows skin appendix H&E 60x

texture is full of newly built vessels. In zinc oxide group, situation is entirely like with low dose treatment group. In eucerin treatment group, wound surface is covered by pustules and regenerative epithelial cells starts to expanding on to the wound surface from sides. Inflammatory cells are purulent and infiltration of fibroblasts and existence of newly built vessels indicates formation of new granular tissue. In control group, granular tissue as vascular and low filament tissue are seen. Hemorrhage and hyperemia is also seen in Fig. 2.

On day 14, in high dose treatment group granular tissue is existed in the wound area and newly formed vessels are low than previous days. The intensity of inflammatory cells is reduced. Collagen fibers are more delicate and have more organization. Hydropic degeneration is also seen in some of the epithelial cells. In low dose treatment group, more thickly epithelial covered wound surface. Collagen is thicker and has more organization. Coagulum isn't existed. In zinc oxide group, fibroblasts start to synthesis of collagen. Inflammatory cells reduced and newly formed vessels increased. Lining tissue is seen in margin of the wound but clot is seen in some places. Blood clot on the wound contains large amounts of acute inflammatory cells were neutrophils and RBC has penetrated into the clot. In eucerin group, space of wound around is occupied by young and multicellular tissue and regeneration of the lining tissue starts from sides. Wound surface covered by pustules that follows contains hyperemia granular tissue. In control group, Marginal parts of the wound are completely covered by epithelial tissue. Also, new and hyper cellular connective tissue covered dermal layer (Fig. 3).

On day 21, in high dose treatment group, in some cases wound surface is covered by lining tissue but in some others this is not occurred completely. The severity of inflammation and hydropic degeneration is reduced. In low dose treatment group, partial edema and hyperemia is still seen and collagen fibers were thicker and condensed and were more organized than day 14. In zinc oxide group, dermal accessories and hair follicles increased in the treated tissues. Collagen fibers increased and have more organization. In the eucerin and control groups, situations were same with day 14 with exception hydropic degeneration (Fig. 4).

On day 28, treatment was seen in about all groups.

DISCUSSION

Zinc oxide ointment is among the most widely used topical ointments to treat ulcers is that content is 20 percent zinc oxide powder. Protect the surface, being astringent, antiseptic, and nontoxic relative of the outstanding characteristics that make the drug as an active ingredient in health and pharmaceutical compounds widely used. In this study were used of this ointment as positive control group too.

Achillea species have been so far reported to contain diterpenes, sesquiterpenes, flavonoids, lignans, essential oil and rarely triterpenes (Ahmed *et al*., 2002; Barrero *et al*., 1990; Mockute and Judzentiene, 2003; Marchart and Kopp, 2003; Aljancic *et al*., 1996; Maffei *et al*., 1994; Oksuz *et al*., 1991; Kusmenoglu *et al*., 1995). For instance, *A. vermicularis* was shown to have guaianolide- and germacrenetype sesquiterpenes as well as flavonoids, whereas *A. setacea* was reported to contain sesquiterpenes, essential oils and flavonoids (Marchart and Kopp, 2003; Oksuz *et al*., 1991; Unlu *et al*., 2002). In addition to extracts, essential oils of the Achillea species were also analysed. The oil of *A. pachycephala* was found to contain 1,8-cineole and camphor as the major constituents, whereas 1,8-cineole and Artemisia ketone were major in *A. oxyodonta*. On the other hand *A. biebersteinii* was rich in camphor and borneol followed by 1,8-cineole. It was stated that all the oils were rich in oxygenated monoterpenes (Esmaeili *et al*., 2006). Non-volatile components of *A. biebersteinii* afforded in

addition to β-sitosterol, stigmasterol two sesquiterpene lactones, germacranolide (Badahdah and El-Orfy, 2004). Essential oil of *A. millefolium* consists of a number of monoterpenes such as α-pinene, β-pinene, 1,8-cineole, camphor and borneol in addition to some sesquiterpene lactones of germacrene-derivatives (Mockute and Judzentiene, 2003). Major component in the essential oils of both *A. setacea* and *A. teretifolia* was elucidated to be 1,8-cineole (Unlu *et al*., 2002) whereas α-pinene, 1,8-cineole and camphor as well as germacrene D and bisabolene as the major constituents of ten other Achillea species (*A. biserrata*, *A. clypeotala*, *A. crithmifolia*, *A. filipendula*, *A. macrophylla*, *A. pannonica*, *A. pyrenaica*, *A. sibirica*, *A. taygetea* and *A. tenuifolia*) (Maffei *et al*., 1994). Various biological activity studies were also completed on *Achillea* species. The antimicrobial and antioxidant activities of the essential oil and the methanolic extract of *A. biebersteinii* were studied in vitro by (Baris *et al*., 2006). The essential oil showed antimicrobial activity against 8 bacteria sp., 14 fungi sp. and the *C. albicans*, whereas the methanolic extract remained inactive.

When a wound occurs and is exposed to external environment, it is more prone to attack by microbes, which invade through the skin and delay the natural wound healing process. Reactive Oxygen Species (ROS), are vital part of healing and serve as cellular messengers that drive numerous aspects of molecular and cell biology. ROS can trigger the various beneficial pathways of wound healing, for example, at micromolar concentrations of hydrogen peroxide can promote Vascular Endothelial Growth Factor (VEGF) expression in keratinocytes (Khanna *et al*., 2001; Prasad and Oberleas, 1974; Nayak *et al*., 2009). During the inflammation phase of healing neutrophils and macrophages are attracted into the injured tissue by various chemotactic factors. They locate, identify, phagocytize, kill and digest microorganisms and eliminate wound debris through their characteristic "respiratory burst" activity and phagocytosis (Clark and Moon, 1999). At high concentrations, ROS can induce severe tissue damage and even lead to neoplastic transformation, which further impede the healing process by causing damage to cellular membranes, DNA, proteins and lipids as well (Martin, 1996). Hence, if a compound or a plant extract having antioxidant potentials and antimicrobial activity additionally, it can be a good therapeutic agent for accelerating the wound-healing process.

Several preparations containing *A. millefolium* extract was quite successfully healed the wounds and scars. The liniment containing hiperisin oil and *A. millefolium* extract patented by *Motogna accelerates* the healing of wounds and gives esthetic scars. Since the liniment is applied as a spray it is easily applied and painless (Motogna, 1971). The activiy most probably comes from the synergistic effect of compounds present in the extract and also additive effect of hiperisin.

According to results reported here yarrow extracts was found to have better activity on the wound healing experimental models compared to the other extracts.

ACKNOWLEDGMENT

This study was extracted from research project which was supported financially by Islamic Azad university of Tabriz branch so the authors thanks for mentioned university.

REFERENCES

Ahmed, A.A., A.A. Mahmoud, E.T. Ali, O. Tzakou, M. Couladis, T.J. Mabry, T. Gáti and G. Tóth, 2002. Two highly oxygenated eudesmanes and 10 lignans from *Achillea holosericea*. Phytochemistry, 59(8): 851-856.

Al-Hindawi, M.K., I.H. Al-Deen, M.H. Nabi and M.A. Ismail, 1989. Anti-inflammatory activity of some Iraqi plants using intact rats. J. Ethnopharmacol., 26(2): 163-168.

Aljancic, I., S. Macura, N. Juranic, S. Andjelkovic, N. Randjelkovic and S. Milosavljevic, 1996. Diterpenes from *Achillea clyopetala*. Phytochemistry, 43: 169-171.

Badahdah, K.O. and H.S. El-Orfy, 2004. Phytochemical constituents of *Achillea biebersteinii*. J. Saudi Chem. Soc., 8: 115-120.

Baris, O., M. Gulluce, F. Sahin, et al., 2006. Biological activities of the essential oil and methanol extract of *Achillea biebersteinii* Afan (Asteraceae). Turk. J. Biol., 30(2): 65-73.

Barrero, A.F., R.E.A. Manzaneda, R.R.A. Manzaneda, S. Arseniyadis and E. Guittet, 1990. Achilleol B: A new tricyclic triterpene skeleton from *Achillea odorata* L. Tetrahedron., 46(24): 8161-8168.

Baytop, T., 1997. A Dictionary of vernacular names of wild, publication of the Turkish Language Society. Ankara, 578: 163-238.

Baytop, T., 1999. Therapy with Medicinal Plants in Turkey, Past and Present. 2nd Edn., Nobel Tıp Kitapevi, Istanbul, Turkey.

Candan, F., M. Unlu, B. Tepe, D. Daferera, M. Polissiou, A. Sökmen and H.A. Akpulat, 2003. Antioxidant and antimicrobial activity of the essential oils and methanol extracts of *Achillea millefolium* susp. millefolium Afan. (Asteraceae). J. Ethnopharmacol., 87: 215-220.

Cheers, G., 1999. Botanica Konemann. Koln, Germany.

Clark, L.A. and R.E. Moon, 1999. Hyperbaric oxygen in the treatment of life-threatening soft-tissue infections. Respir. Care Clin. No. Am., 5(2): 203-219.

Duman, H. and L. Achillea, 2000. In: Guner, A., N. Ozhatay, T. Ekim and K.H.C. Baser, (Eds.), Flora of Turkey and the East Aegean Islands. Edinburgh University Press, Edinburgh, UK, 11: 158-159.

Esmaeili, A., F. Nematollahi, A. Rustaiyan, N. Moazami, S. Masoudi and S. Bamasian, 2006. Volatile constituents of *Achillea pachycephala*, A. oxyodonta and A. biebersteinii from Iran. Flavour Fragrance J., 21(2): 253-256.

Fujita, T., E. Sezik, M. Tabata, et al., 1995. Traditional medicine in Turkey VII. Folk medicine in middle and west Black Sea regions. Econ. Bot., 49(4): 406-422.

Golden, M.H.N., B.E. Golden and A.A. Jackson, 1980. Skin breakdown in kwashiorkor responds to zinc. Lancet, 1: 1256.

Haley, J.V., 1979. Zinc sulfate and wound healing. J. Surg. Res., 27: 168.

Honda, G., E. Yesilada, M. Tabata, E. Sezik, T. Fujita, Y. Takeda, Y. Takaishi and T. Tanaka, 1996. Traditional medicine in Turkey VI. Folkmedicine in West Anatolia: Afyon, Kutahya, Denizli, Mugla, Aydin provinces. J. Ethnopharmacol., 53(2): 75-87.

Karamenderes, C. and S. Apaydın, 2003. Antispasmodic effect of *Achillea nobilis* L. subsp. sipylea (O. Schwarz) Bassler on the rat isolated duodenum. J. Ethnopharmacol., 84(2-3): 175-179.

Khanna, S., S. Roy, D. Bagchi, M. Bagchi and C.K. Sen, 2001. Upregulation of oxidant-induced VEGF expression in cultured keratinocytes by a grape seed proanthocyanidin extract. Free Rad. Biol. Med., 31(1): 38-42.

Kusmenoglu, S., K.H.C. Baser, T. Ozek, M. Harmandar and X. Gokalp, 1995. Constituents of the essential oil of *Achillea biebersteinii* Afan. J. Essential Oil Res., 7(5): 527-528.

Maffei, M., M. Mucciarelli and S. Scannerini, 1994. Essential oils from Achillea species of different geographic origin. Biochem. Syst. Ecol. 22(7): 679-687.

Marchart, E. and B. Kopp, 2003. Capillary electrophoretic separation and quantification of flavone-O- and C-glycosides in *Achillea setacea* W. et K. J. Chromatography B., 792: 363-368.

Martin, A., 1996. The use of antioxidants in healing. Dermatol. Surg., 22(2): 156-160.

Mockute, D. and A. Judzentiene, 2003. Variability of the essential oils composition of *Achillea millefolium* ssp. millefolium growing wild in Lithuania. Biochem. Syst. Ecol., 31(9): 1033-1045.

Motogna, A., 1971. Liniment for treating serious burns. (Combinatul de Industrie Locala), Rom. RUXXA3, RO 52874, 19711125, Appl., RO 68-58261.

Nayak, B.S., S. Sandiford and A. Maxwell, 2009. Evaluation of the wound-healing activity of ethanolic extract of *Morinda citrifolia* L. leaf. Evidence-Based Complementary Altern. Med., 6(3): 351-356.

Oksuz, S., S. Gumus and K. Alpınar, 1991. Sesquiterpenoids and flavonoids of *Achillea species*. Biochem. Syst. Ecol.19(5): 439.

Prasad, A.S. and D. Oberleas, 1974. Thymidine kinase activity and incorporation of thymidine into DNA in zinc-deficient tissue. J. Lab. Clin. Med., 83: 634.

Sandstead, H., V.C. Lanier, G.H. Shepard and D.D. Gillespie, 1970. Effects of zinc deficiency and zinc supplementation. Amer. J. Clin. Nut., 23: 514.

Senatore, F., F. Napolitano, N.A. Arnold, M. Bruno and W. Herz, 2005. Composition and antimicrobial activity of the essential oil of Achillea falcata L. (Asteraceae). Flavour Fragrance J., 20(3): 291-294.

Sezik, E., E. Yesilada, G. Honda, Y. Takaishi, Y. Takeda and T. Tanaka, 2001. Traditional medicine in Turkey X. Folk medicine in Central Anatolia. J. Ethnopharmacol., 75(2-3): 95-115.

Skocibusic, M., N. Bezic, V. Dunkic and A. Radonic, 2004. Antibacterial activity of *Achillea clavennae* essential oil against respiratory tract pathogens. Fitoterapia., 75(7-8): 733-736.

Stromberg, H.E. and M.S. Agren, 1984. Topical zinc oxide treatment improves arterial and venous leg ulcers. Brit. J. Dermatól., 1: 461.

Unlu, M., D. Daferera, E. Donmez, M. Polissiou, B. Tepe and A. Sokmen, 2002. Compositions and the in vitro antimicrobial activities of the essential oils of *Achillea setacea* and *Achillea teretifolia* (Compositae). J. Ethnopharmacol., 83(1-2): 117-121.

Yesilada, E., G. Honda, E. Sezik, M. Tabata, K. Goto and Y. Ikeshiro, 1993. Traditional medicine in turkey IV. Folk medicine in the Mediterranean subdivision. J. Ethnopharmacol., 39(1): 31-38.