International Journal of Animal and Veterinary Advances 1(2): 28-31, 2009
ISSN: 2041-2908

Submitted Date: June 08, 2009 Accepted Date: August 14, 2009 Published Date: October 30, 2009

Hematological and Histological Response of Wister Albino Rat *Rattus norvegicus* a Dietary Supplement of Seaweed Diet *Gracilaria edulis*

[1]R. Dhanapal , [2]T. Anbalagan and [1]S. Sivasuriyan
[1]Department of Zoology and Biotechnology,A.V.V.M. Sri Pushpam College (Autonomous), Poondi-613 503, Tamil Nadu, India
[2]C.A.S. in Marine Biology, Annamalai University, Parangipettai-608 502, Tamil Nadu, India

Abstract: A dietary supplementation of seaweed *Gracilaria edulis* haematological and histological response of albino rat *Rattus norvegicus* .The blood protein, cholesterol, albumin, calcium, phosphorus and urea of the seaweed feed albino rats having an increased tendency during the experimentation when compared with control rats. Its note mostly that the experimental rat showing a decreasing level of glucose when compared with control rats. The oral picture of the haematological change of albino rat fed with seaweed diet evidenced their active participation on the metabolism of the experimental subject. These findings were well correlated with histological observation in the liver and intestine shows the hepatocyte appearance and deposited fat and foci at necrosis is also seen in photomicrographs.

Keywords: Suplementation, haematology, histology, seaweed and Albino rat

INTRODUCTION

Recent seaweeds are used for feed purpose only during the period of scarcity and shortage of other feed materials is there over and above in this period of advanced achievements in the field of agriculture and modern feeding techniques. Seaweed dose not hold prime position in feeding field but used only supplementary feed (Dave *et al*., 1977). Meals prepared from seaweeds can be given as supplements to the daily of the cattle, poultry shrimps and fin fishes. Major regional studies of Gracilari include those of Yamamoto (1978) for Japan. Chang and Xia (1976) for mainland Chaina, Uma Maheswara Rao (1972) for India. To investigate the biochemical composition of some marine algae from Mandapam (Chennubhola *et al*., 1990) and feed formulation as the related to investigate that Sobha *et al*., 1999).

Hematological studies and immune response at algal extraction from Sargassum swartzii administered to Wister albino rat, Rattus norvegicus working for Sasikala and Makesh (1999) and addition of histological changes. Were previous work done by Anshu verma *et al* (2000) to the supplemented in the mushroom feed among changes in rat. Chandra and Manjunaresh (1987) was reported that histological structure of albino rats and also the histological analysis that Freeman and Brain Bralegirdle, (1996). The present study was discussed to determine the seaweed supplementary diet on experimental rats in Blood biochemical and histology.

MATERIAL AND METHODS

Fresh seaweed, *Gracilaria edulis* was collected from intertidal region of *Thonitharavai* near Pampan (Lat.95º45′ N; Lon.79º 15′ E) and immediately brought the laboratory in plastic bags, then the seaweeds were washed throughly with tap water to remove all the unwanted impurities, epiphytes and adhering sand particles, etc. The samples were shade-dried until constant weight obtained and ground in an electric mixer. The Power samples were then stored in refrigirater for future use.

Experimental animal: The albino rat (Wister strain) weighing 50-55 g are used in this study (45 days old). These were distributed randomly into two groups of five animals each into separate gauges, over-ruling the effects of littermate size, sex and weight of the animals.

Formulation of the feed: In normal group of animals served as control feed ingredients is *Topioca* flour 6.64g, *Ricebran* 6.64 g, Groundnut cake 43.36 g, *Ragi* powder 43.36 g and Treated animals feed ingredients is *Topioca* flour 3.00 g, *Ricebran* 3.00 g, Groundnut cake 31.33 g, *Ragi* powder 31.33 g and *Gracilaria edulis* Powder 31.34 g in 100 g were mixed with water and formed prepared separately a pellet feed. Control and treated groups of animals were well-aerated and hygienic room (room temperature 32ºC). Normal and treated feeds were administrated to the rats through oral incubation method. Animals had an access for food in 20 g after 3-4 hours of administration in 20 days experiment. Once in a 4 days mean weight of animals were noted (Table.1).

Maintenance of animals: Control and experimented groups of animals were well-ventilated and hygienic room (room temperature 32ºC). Normal and treated feeds were

Corresponding Author: T. Anbalagan, C.A.S. in Marine Biology, Annamalai University, Parangipettai-608 502, Tamil Nadu, India

Table 1: Percentage composition of feed ingredients in control and experimental diets (For 100 g feed)

Feed ingredients	Control feed (g)	Experimental feed (g)
Tapioca flour	6.64	3.00
Rice bran	6.64	3.00
Groundnut cake	43.36	31.33
Ragi powder	43.36	31.33
Gracilaria sp.powder	--.	31.34
	100.00 g	100.00 g

administered to the rats through oral incubation method. Animals had an access for food in 20 g after 2-4 hours of administration in 20 days experiment. Once in a 4 days mean weight of animals were noted.

Collection of sample: The Haemato-biochemical studies blood was collected by cardiac puncture under anesthesia in vials containing EDTA (mg/ml) of the end of the experiments was used for the, protein, (Bradford, 1976); Glucose, (Schmidt, 1971); cholesterol, (Flag, 1973); Calcium, (Smith, 1979); Phosphorous, (Henry, 1979), Urea, (Henry 1963) and For histological studies liver and intestine were collected from sacrificed animals the methods followed by (Freeman and Brain Bralegirdle, 1966).

RESULTS

The dietary supplement of *Gracilaria edulis* feeds to the albino rat. There is a significant changes observed in the blood, tissues and weight of the rat. Mean weight (in g) five animals shows that the Table 2. Weight of animals is gradually increased and significant variation is also identified in the control and seaweed treated group of animals.

Hematological changes in animal serum: The amounted total serum protein in the experiment animals showed significant fluctuation. The protein content ranged from 9.4±0.026g/dl it was found to be low in control rats and high in treated rats. The amount of glucose content in the serum of experimental rats showed significant variation. It ranged from high in control rats 166±0.24 mg/dl and low in treated animals is 143±0.26mg/dl. It clear from the data the cholesterol content is 271±0.19 mg/dl and maximum in treated is 293±0.35.The amount of albumin content in the serum experimental animal showed the variation among the rats. It varied from 6.8± 0.024 g/dl in control values also increase in treated sample is 7.1±0.026 g/dl. Calcium content in the blood of experimental animals showed variation in ranged from 13.1±0.026mg/dl in control animal serum and slightly increased in 13.8±0.03 mg/dl in the seaweed treated animals. The phosphorus level of animal blood sample is control value is 7.1±0.03mg/dl and varied in treated value is 7.6±0.023 mg/dl. The urea value is varied from the control animal value is 52±0.26 mg/dl up to seaweed treated animal value is 64±0.32 mg/dl in blood (Table 3)

Histological changes: Histological changes were noticed in liver and intestinal tissues. Fig 2 and 4 showing

Table 2: Mean weight (g) of control and seaweed diet groups once in four days at 20 days experiment

S.N0	Normal	Experiment
1	50	55
2	54	61
3	60	68
4	66	75
5	72	82
6	78	89

Table 3: Level of blood biochemical in the blood of albino rat.

S.no	Blood	Control	Experiment
1	Total protein(g/dl)	9.4±0.026	9.6±0.023
2	Glucose (mg/dl)	166±0.24	143±0.26
3	Cholesterol(mg/dl)	271±0.14	293±0.35
4	Albumin)mg/dl)	6.8±0.024	7.1±0.026
5	Calcium(mg/dl)	13.1±0.026	13.8±0.03
6	Phosphorus(mg/dl)	7.1±0.03	7.6±0.023
7	Urea(mg/dl)	52±0.26	63±0.32

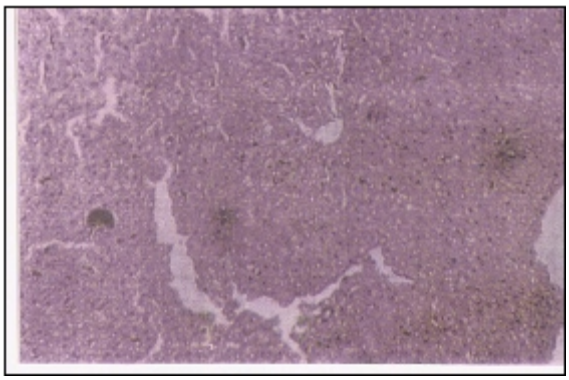

Fig 1: shows no histopathological changes in liver of control groups



Fig 2: Shows histopathological changes in seaweed treated group of control groups, a. Feathery degeneration of hepatocytes with ground glass appearance. b. Fat deposition and foci of necrosis.

changes are visible but not in Fig 1 and 3. Liver shows feathery degeneration of hepatocytes with ground glass appearance, fat deposition and foci of necrosis. Area of congestion is also seen in seaweed treated when compared to normal. Intestine shows mucosal ulcerations sparse inflammation and foci of necrosis, on seaweed treated rats (b) when compared to normal rats.

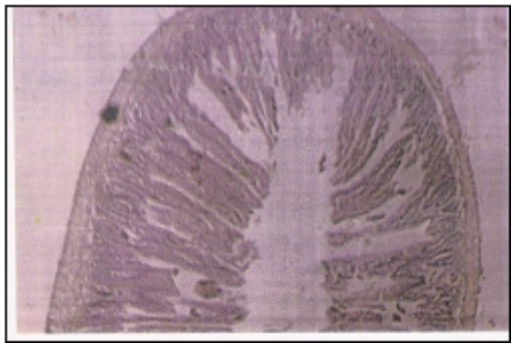

Fig 3: Shows no histopathological changes in intestine of control groups

Fig 4: Shows histopathological changes in seaweed treated group of albino rat. i. Mucosal ulcerations sparse inflammation. ii. Foci of necrosis

DISCUSSION

The present study represents a preliminary contribution to the biochemical and cytological status of Wister albino rat to seaweed diet. Central sheep and wool research institute conducted feeding trials; Avikanagar (Rajasthan) is conducted feeding trials with the additional seaweed meal 5-15 percent along with the regular feed. They observed seaweed when fed up to 20 percent in the other ratio gives average gain in weight more than the control diet. Report on Directorate of veterinary Education and Research, Tamilnadu have 10% seaweeds supplemented diet for chicken against control one. They observed and noticed weight or quantity of eggs may increase (Dave *et al.*, 1979). In the presence study the blood biochemical of apparently control and treated animals shows significant variation in protein level. The average value of protein content showed in higher value in the treated rat. In large amount of protein content in the seaweed supplemented feed used for rats. The normal rat the protein content average level or value, the difference in protein content. This can be attributed that the seaweed could be a good source of dietary fiber in diet but they may modify digestibility of dietary protein and minerals (Urbano *et al.*, 2002). Glucose is another important energy yielding component. These are precursors for the synthesis of all organic components found in plants, animals and also seaweeds. They constitute the important source of food materials. The cholesterol is the animal sterol, which occur free state or as fatty esters. It is an important component of some cell membrane and plasma protein; in control serum value is minimum and also high in agrees with earlier observations (Metha *et al.*, 1989). Intestine shows mucosal ulcerations sparse inflammation and foci at necrosis. Effect of hydro coritisone acetate on the histological structure of albino rats already reported Chandra and Manjunaresh (1987), Effect of Norethindrone acetate on Glycogen and Phosprorylase of adult rat (Sengupta *et al* 1981), Effect of age on strout-ium-calcium discrimination by rat tissues (Kshivsagar, 1985). Pre-treatment with alcoholic extract of Sargassum polycystum significantly reduced the toxic of acetaminophen by improving the severely altered haematological and biochemical parameters suggesting a free radical scavenging property (Balaji *et al* 2004). It concludes the present investigation, which suggest that the seaweed mixed diet definitely have some stimulatory effect on the blood biochemical and histology of the albino rat.

REFERENCE

Anshu, V., K. Ameeta, H.S. Kushwah, H.S.Singh and M.R. Malik, 2000. Haemato-biochemical and histological changes in rats upon dietary supplementation of cultivated mushroom, Indian J. Nur. Dietet., 38:191-198.

Balaji, R., H. Rao, A. Sathivel and T. Devaki, 2004. Effect of *Sargassum polycystum* against acetaminophen induced haematological and biochemical changes in experimental rats. Seaweed Res. Utiln., 26(1-2): 121-126.

Bradford, M.M., 1976, A rapid and sensitive method for the quantitation of microgram quantities of protein utilizing the principle of protein-dye binding. Anal. Biochem., 72: 248-254.

Chandra, N. and Manjunaresh, 1987. Effect of hydro cortisone acetate on the histological structure of albino rats, J. Anat. Sci, 9: 29-33.

Chang, C.F. and B.M. Xia, 1976. Studies on Chinese species of *Gracilaria*, Stud. Mar. Sin. 11: 91-163.

Chennubhola, V.S.K., M. Najmuddin, J.R. Ramalingam, and N. Kaliyaperumal, 1990. Biochemical composition of some marine algae from Mandapam Coast, Tamilnadu, CMFRI Bull., 44: 442-446.

Dave, M.J., S.K. Gany and R.R. Iyengar, 1977. Assessment of the possibility at seaweeds to be utilized as supplementary animal feed, CSMCRI, Bhavnagar Salt Res. Ind., 13(122): 33-40.

Dave, M.J., R.G. Parekh, S.K. Garg, and D.J. Mehta, 1979. Preparation of seaweed meal for the farm animals, salt Res. India, CSMCRI, Bhavnagar, 15(1-2): 34-38.

Flag, H.M., 1973.Ann. Clin. Biochem., 10:1350-1356.

Freeman, W.H. and B. Brain, 1966. An Atlas of histology.Histochemical analysis of Tissues.Heinmann Educational Books LTD., London, pp: 53-73.

Henry, J.B., 1979. Clinical diagnosis and management by Laboratory methods, W.B.Saunders and company, Philadelphia, P.A., pp: 365.

Henry, R.J., 1963. Clinical Chemistry Principle and Techniques, Harper and Row, New York, pp: 268.

Kshivsagar, S.G., 1985. Effect of ageon strout-ium-calcium discrimination by rat tissue, Indian J. Exp. Biol., 23: 366-369.

Mehta, U., S.N. Mehta, G.C. George, S. Mehta, V.P. Dexit, and P.C. Verma, 1989. Effect of dietary zinc and copper or peripheral blood plasma cholesterol, testosterone and histomorphology of testis in rats, Indian J. Exp. Biol., 27: 469-471.

Sasikala, S.L. and S.V. Makesh,1999. Haematological studies and immune response of algal extractives from Sargassum swartzii administered to wister albinorat,Rattus norvegicus,Seaweed Res.Utiln., 21(1-2): 155-160.

Schmidt, F.H., 1971. Methodon der Ham,Und Blutzuckar bestimmung II. Blutzuckar, E.F. Pleiffer, (Ed.). Handbuck desDiabetes Mellitus, J. F.Lehmann's Veriag Munich, 2: 938.

Sengupta, D., P.K. Datta, S. Saha and S. Samaddar, 1981. Effect of norethindropne acetate on glycogen and phosphorylase of adult rat, Indian J. Exp. Biol., 19: 649-650.

Smith, H.G., 1979. Biochem., 18:5067.

Sobha ,V., M.S. Bindu and K.V. Jayasree,1999. Effect of algal feed on growth and digestive enzyme activity of Labeo rohita Hamilton and Oreochromis mossombicus Peters, Seaweed Res. Utiln., 21(1-2): 129-136.

Uma Maheswara Rao, M., 1972. On the *Gracilaria*ceae of the seas around India, J.Mar.Biol.Ass.India, 14: 671-696.

Urbano, M.G. and T. Goni, 2002. Bioavailabity of nutrients in rats fed on edible seaweeds, Nori (Porphy ratenera) and Wakame (undaria pinnatifida), as a source of dietary fibre, Food Chem., 76: 281-286.

Yamamoto, H., 1978 .systematic and anatomical study of the genus Gracilari in Japan. Mem. Fac. Fish. Hokkaido Univ., 25: 97-152.