

Research Article

Amelioration of High Cholesterol Diet Caused Lipids Accumulation in Hepatic Cells by Rutin and Ascorbic Acid

Abdulaziz M. Aleisa

Department of Pharmacology and Toxicology, College of Pharmacy, King Saud University,
P.O. Box 2457, Riyadh 11451, Saudi Arabia, Tel.: +96614677178, Fax: +96614677200

Abstract: Non Alcoholic Fatty Liver Disease (NAFLD) has become a very common metabolic disorder. It refers to a group of conditions where excess fats are deposited in hepatic cells. Several approaches have been considered for the management of NAFLD including dietary changes, which were reported to suppress hepatic lipids accumulation in previous studies. The present study was designed to investigate the possible synergistic effects of Rutin (RT) and Ascorbic Acid (AA) against lipids accumulation in hepatic cells of male Wistar albino rats. Thirty animals received freshly prepared experimental High Cholesterol Diets (HCD) with or without RT and/or AA for 6 consecutive weeks. In hepatic tissues nucleic acids, total protein, Total Cholesterol (TC) and Triglycerides (TG) concentrations were measured. Histopathological changes were also observed. In hepatic cells, nucleic acids and total protein levels were significantly reduced in HCD alone fed group, quite the reverse, TC and TG levels increased. RT and/or AA supplementation along with HCD showed antilipidemic effects in hepatic cells while compared to only HCD group. Histopathological assessment of the liver sections revealed moderate degree of hepatotoxicity following HCD feedings and mild degree of hepatotoxicity when combining either RT or AA with HCD, while HCD+RT+AA group had no such changes. The present data demonstrated that the degree of HCD induced hepatotoxicity is in positive correlation with hepatic lipids accumulations. Both RT and AA could reduce this toxicity through their antilipidaemic properties, which may be augmented by their combined intake.

Keywords: Ascorbic acid, fatty liver, high cholesterol diet, hypercholesterolemia, rutin

INTRODUCTION

Hypercholesterolemia is considered nowadays as one of the most familiar metabolic diseases. Obesity, diabetes, and metabolic syndrome are closely associated with hypercholesterolemia (Farrell *et al.*, 2008; Postic and Girard, 2008; Trauner *et al.*, 2010). Hypercholesterolemia can eventually lead to Non-Alcoholic Fatty Liver Disease (NAFLD), which is known to be a common cause of chronic liver disease in adults and children in many world regions. It is usually progress to cirrhosis or even Hepato Cellular Carcinoma (HCC) (Kim *et al.*, 2012). Reports showed that 34% of the general population and over 75% of obese and extremely obese individuals are suffering from have fatty liver (Browning and Horton, 2004). In addition, deposition of lipids and triglycerides in liver of experimental animals was reported following high cholesterol diet supplementation (Lee *et al.*, 2007). Experimentally induced hypercholesterolemia can impairs lipid metabolism leading to elevation of both blood and tissue lipid profile (Vasu *et al.*, 2005). Moreover, studies demonstrated that even short exposure to HCD is capable of inducing hypercholesterolemia (Tomofuji *et al.*, 2006). Therefore, it is necessary to search for effective

approaches to control hypercholesterolemia and the associated fatty liver. Non pharmacological approaches for hypercholesterolemia include increased physical activity and weight reduction through lifestyle modification as well as dietary changes (Kim *et al.*, 2012). Dietary supplementation of antioxidants may effectively suppress hepatic lipids accumulation, which seems to be a useful therapy (Yang *et al.*, 2012).

Rutin (RT), a quercetin-3-rutinosid or vitamin-P, is a well known flavonoidal glycoside. It is an antioxidant, which comprised of the flavonolquercetin and the disaccharide rutinose (Ihme *et al.*, 1996; Lindahl and Tagesson, 1997). It is mainly found in onions, apples, tea and red wine (Hertog *et al.*, 1993). Various pharmacological properties were reported for rutin including antibacterial, antitumor, anti-inflammatory, anti-diarrheal, antiulcer, anti-mutagenic, vasodilator and immunomodulator (Janbaz *et al.*, 2002). Moreover, rutin can suppress adipocyte differentiation from pre-adipocytes (Choi *et al.*, 2006). On the other hand, ascorbic acid (AA; as a reduced form of vitamin C) is a famous effective antioxidant. Ascorbic acid is the most predominant form of vitamin C in the human body and is involved in tissue growth and repair. It is a water-soluble enzyme cofactor, abundantly present in different plants and animals. In earlier studies, plasma

concentrations of cholesterol and fatty acids were noticed to be increased during vitamin C deficiency (Dunn *et al.*, 1984; Ha *et al.*, 1990; Nelson *et al.*, 1981). Moreover, vitamin C showed beneficial effects against NAFLD in several studies (Ersoz *et al.*, 2005; Oliveira *et al.*, 2003).

Several studies have investigated the possible additive protective effects of dietary vitamins on the development of NAFLD (Arendt and Allard, 2011; Assy, 2011). Therefore, this study was designed to assess the possible synergistic effects of RT and AA on hepatic lipid deposition and cellular damage following HCD supplementation for 6 weeks in male Wistar rats as a model of NAFLD.

MATERIALS AND METHODS

Animals: Thirty young male Wistar albino rats were provided from the Experimental Animal Care Center (King Saud University, Riyadh, Saudi Arabia). Animals had approximately the same age and weight (80-100 g). Experimental environment was maintained under controlled conditions of temperature (22±1°C), humidity (50-55%), and light (12 h light/dark cycles). All methods including euthanasia procedure were conducted in accordance with the Guide for the Care and Use of Laboratory Animals, Institute for Laboratory Animal Research, National Institute of Health (NIH Publications No. 80-23; 1996) and approved by the Ethical Guidelines of the Experimental Animal Care Center (College of Pharmacy, King Saud University and Riyadh, Saudi Arabia).

Experimental design and diet preparation: Animals were randomly arranged in five groups, six animals per each, as follow:

- Control (Cont) fed on normal diet

- HCD fed on 1% cholesterol +0.5% cholic acid
- RT+HCD fed on 0.2% RT+1% cholesterol +0.5% cholic acid
- AA+HCD fed on 0.4% AA+1% cholesterol +0.5% cholic acid
- RT+AA+HCD fed on 0.1% RT+0.2% AA+1% cholesterol +0.5% cholic acid

All experimental feeding diets were prepared weekly and shade dried in rat chow powder. All animals were kept on free access to diet and water fed for six consecutive weeks. Animals' body weight and general health were carefully monitored during the whole experiment period. At end of the sixth week, all animals were sacrificed by decapitation. Liver tissues were dissected and weighed. Liver tissues were immediately dipped in liquid nitrogen for 1 min and then preserved at -75°C (Ultra-low freezer, Environmental Equipment, Cincinnati, Ohio, USA) till analysis.

Determination of nucleic acids and total protein levels in liver tissues: The method described by Bregman (1983) was used to estimate DNA and RNA levels in liver tissues (Bregman, 1983). Briefly, tissues were homogenized in ice-cold distilled water. The homogenates were then suspended in 10% ice-cold Trichloroacetic Acid (TCA). Pellets were extracted twice with 95% ethanol. The nucleic acids extract was treated either with diphenylamine or orcinolreagent for quantification of DNA and RNA levels, respectively. In addition, the modified Lowry method by Schacterle and Pollack (1973) was used to estimate levels of total protein in liver using bovine plasma albumin as a standard.

Determination of lipids contents of liver tissues: Folch *et al.* (1957) method was used to estimate total cholesterol and triglycerides levels in liver tissues

Table 1: Histopathological grading of liver injury

Type of damage	Degree of the damage	Score
Degeneration and intracellular accumulation	• None	0
	• ≤25% of hepatocytes	1
	• 25-50% of hepatocytes	2
	• 51-75% of hepatocytes	3
	• ≥75% of hepatocytes	4
Apoptosis/necrosis	• None	0
	• Unifocal	1
	• Multifocal	2
Inflammation	• Entire liver parenchyma	3
	• None	0
	• One focus of periportal inflammation per section	1
Regeneration	• 2-4 foci of periportal inflammation per section	2
	• ≥5 foci of periportal inflammation per section	3
	• None	0
	• ≤25% of liver parenchyma involved	1
Fibrosis	• 25-50% of liver parenchyma involved	2
	• 51-75% of liver parenchyma involved	3
	• ≥75% of liver parenchyma involved	4
	• None	0
	• ≤25% of liver parenchyma involved	1
	• 25-50% of liver parenchyma involved	2
	• 51-75% of liver parenchyma involved	3
	• ≥75% of liver parenchyma involved	4

(Folch *et al.*, 1957). Liver tissues were homogenized in 0.15 mol/L of ice-cold KCl (10% w/w) then lipids were extracted with chloroform: methanol (2:1). After the extraction and evaporation, tissue lipids were re-dissolved in isopropanol, and liver cholesterol and triglyceride levels were estimated enzymatically by commercially available kits (Human, Wiesbaden, Germany).

Histopathological examination of liver tissues: Liver tissues from all groups were fixed in 10% neutral buffered formalin, embedded in paraffin wax and sectioned at 3 μ m. Sections were then stained with Hematoxylin and Eosin (H&E) stain and placed in slides for light microscopic examination. Slides were evaluated by a histopathologist who was blinded to the treatment groups to avoid any kind of bias. Histopathological grading was performed according to Table 1. The degree of the hepatotoxicity was considered according to the total score of liver histopathological grading where; (≤ 3) classified as no hepatotoxicity, (4-7) classified as mild hepatotoxicity, (8-11) classified as moderate hepatotoxicity and (≥ 12) classified as severe hepatotoxicity.

Statistical analysis: All data were expressed as mean \pm Standard Deviation (S.D.). Data were statistically analyzed using one-way ANOVA followed by Student-Newman-Keuls multiple comparisons test. The differences were considered statistically significant at $p < 0.05$. Correlation coefficient was determined by linear regression analysis. Graph Pad prism program (version 5) was used as analyzing software.

RESULTS

HCD administration for 6 weeks significantly ($p < 0.01$) elevated liver weight as compared to control group. Administration of RT and AA alone or in combination significantly ($p < 0.05$) inhibited this elevation as compared to HCD fed animals (Fig. 1).

Hepatic DNA, RNA and total protein levels were significantly ($p < 0.01$, $p < 0.05$ and $p < 0.001$,

respectively) decreased in HCD group as compared to control group (Fig. 2). RT and/or AA administration to HCD fed rats significantly ($p < 0.05$) inhibited the reduction in hepatic DNA levels as compared to HCD fed rats. Furthermore, combining both RT and AA along with HCD significantly ($p < 0.05$) ameliorated the decrease in hepatic RNA levels as compared to HCD group. There were no significant effects of both vitamins treatment on the reduced level of hepatic total protein (Fig. 2).

HCD supplementation elevated concentrations of hepatic TC and TG significantly ($p < 0.001$) as compared to control group. Feeding of the animals with RT and AA alone or in combination along with HCD significantly ($p < 0.001$) inhibited hepatic TC and TG accumulation as compared to HCD group (Fig. 3).

Histopathological assessment of liver sections from control animals revealed normal looking hepatocytes. Nearly, there was no degenerative, regenerative, necrosis, fibrosis, foci of periportal and lobular inflammatory cell infiltrates. Histopathological diagnosis was no hepatotoxicity (Table 2 and Fig. 4A). On the other hand, HCD group liver section showed signs of degeneration and intracellular accumulation of inflammatory infiltrates. Also, there were scattered foci of steatohepatosis along with swollen epithelial cells associated with scattered foci of periportal to lobular inflammatory cell infiltrates. Histopathological diagnosis was moderated degree of hepatotoxicity (Table 2 and Fig. 4B). Liver sections from RT+HCD and AA+HCD groups showed a histopathological diagnosis of mild degree of hepatotoxicity. There was a mild degree of lipids accumulation in hepatic tissues with little degenerative cells and inflammatory cell infiltrates in RT+HCD and AA+HCD group (Table 2 and Fig. 4C and D). Finally, hepatocytes from HCD+RT+AA group were benign in looking, separated by congested central veins. Lobular lymphocytic infiltrate were noticed in few areas with no regenerating nodules or fibrosis. Histopathological diagnosis was mild degree hepatotoxicity (Table 2 and Fig. 4E).

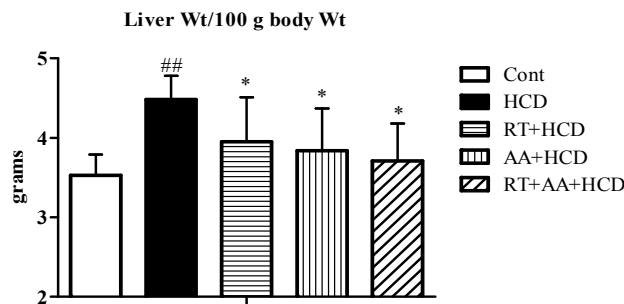


Fig. 1: Effects of Rutin (RT) and/or Ascorbic Acid (AA) supplementations for 6 consecutive weeks on animals liver weights per 100 g body weight in normal and High-Cholesterol Diet (HCD) fed rats
Data were expressed as Mean \pm S.D. and analyzed using one-way ANOVA followed by Student Newman-Keuls method as post hoc test; Six rats were used in each group; ###: $p < 0.01$ control vs HCD group; *: $p < 0.05$ HCD vs vitamins treated groups

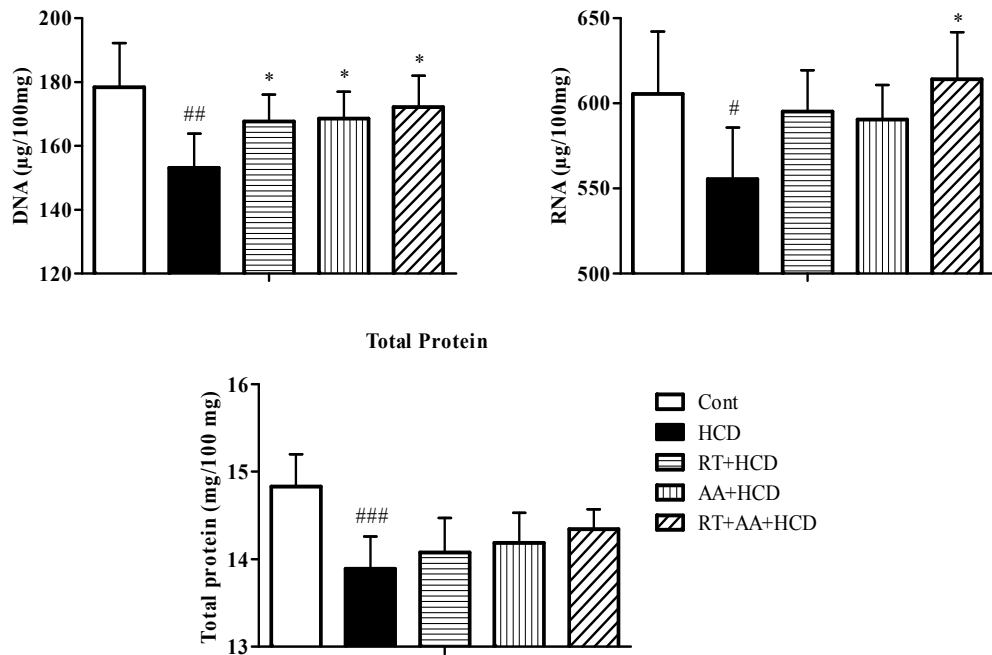


Fig. 2: Effects of Rutin (RT) and/or Ascorbic Acid (AA) supplementations for 6 consecutive weeks on nucleic acids and total protein levels in normal and High-Cholesterol Diet (HCD) fed rats
Data were expressed as Mean±S.D. and analyzed using one-way ANOVA followed by Student Newman-Keuls method as post hoc test; Six rats were used in each group; #: p<0.05, ##: p<0.01 and ###: p<0.001 control vs HCD group; *: p<0.05 HCD vs vitamins treated groups

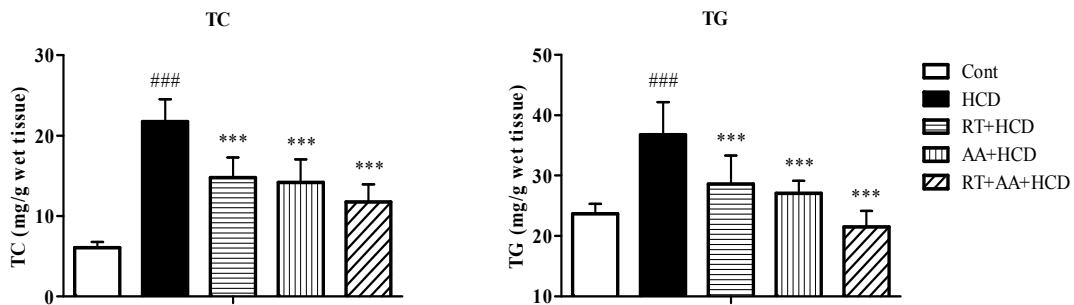
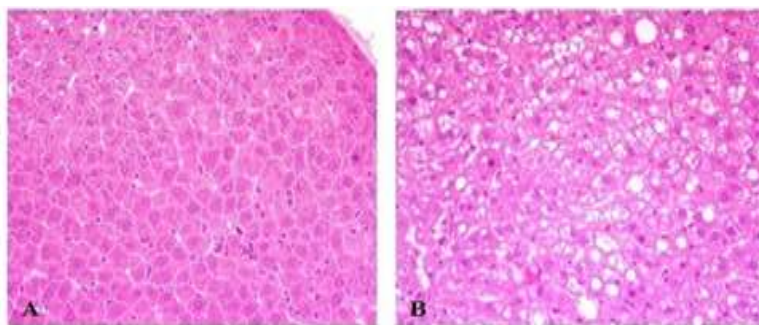


Fig. 3: Effects of Rutin (RT) and/or Ascorbic Acid (AA) supplementations for 6 consecutive weeks on hepatic Total Cholesterol (TC) and Triglycerides (TG) levels in normal and High-Cholesterol Diet (HCD) fed rats
Data were expressed as Mean±S.D. and analyzed using one-way ANOVA followed by Student Newman-Keuls method as post hoc test; Six rats were used in each group; ###: p<0.001 control vs HCD group; ***: p<0.001 HCD vs vitamins treated groups



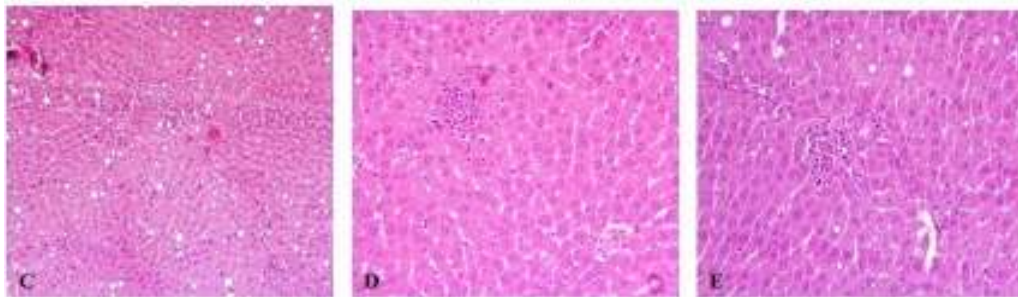


Fig. 4: Histopathological sections from liver tissues showing (A) normal looking hepatocytes in control group, (B) scattered foci of steatohepatosis of liver hepatocytes with widely ballooning degeneration of liver hepatocytes affecting about 75% of liver cells associated with scattered partial and lobular tract inflammatory cells infiltrate of about 4 foci in HCD group, (C and D) mild degree of hepatic fatty accumulation with little degenerative cells and inflammatory cell infiltrates in RT+HCD and AA+HCD group, (E) benign looking hepatocytes separated with few dilated, congested central veins, with little degenerative cells and inflammatory cell infiltrates in RT+AA+HCD group

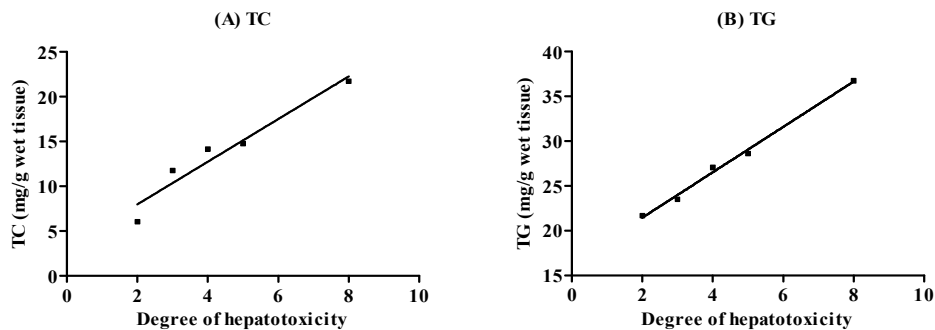


Fig. 5: Analysis of the correlation coefficients between the degree of hepatotoxicity and hepatic, (A) Total Cholesterol (TC), (B) Triglycerides (TG) levels in normal and High-Cholesterol Diet (HCD) fed rats
Correlation coefficient was determined by linear regression analysis; A significant positive correlation was observed in both cases ($r^2 = 0.9365$ and 0.9942 respectively, $p < 0.05$)

Table 2: Histopathological scoring after Rutin (RT) and/or Ascorbic Acid (AA) treatments in High-Cholesterol Diet (HCD) fed rats following 6 weeks of supplementation

Groups	Degeneration and intracellular accumulation	Apoptosis/necrosis	Inflammation	Regeneration	Fibrosis	Total score	Degree of hepatotoxicity
Cont	1	0	1	0	0	2	No
HCD	4	2	3	0	0	9	Moderate
RT+HCD	2	1	2	0	0	5	Mild
AA+HCD	2	1	1	0	0	4	Mild
RT+AA+HCD	1	0	2	0	0	3	No

As shown in Fig. 5 (A and B), There was a significant positive correlation between the hepatic degree of HCD induced toxicity and hepatic content of TC and TG ($r^2 = 0.9365$ and 0.9942 respectively, $p < 0.05$).

DISCUSSION

In the present study, the protective role of Rutin (RT) and/or Ascorbic Acid (AA) on hypercholesterolemia induced hepatic lipids deposition and toxicity was investigated in male Wistar albino rats. HCD supplementation for six consecutive weeks resulted in a significant hepatocellular injury and accumulation of triglycerides and total cholesterol.

Moreover, concurrent supplementation of RT and/or AA with HCD significantly attenuated hepatic damage and lipids deposition as compared to HCD alone group. Results of histopathological investigation have confirmed these findings where hepatic fibrosis and fat accumulation were found at lesser extent in all vitamins supplemented HCD animals. Moreover, results of this study revealed a strong positive correlation between hepatic lipids accumulation and HCD induced hepatotoxicity.

Studies indicated that HCD can significantly induce hypercholesterolemia, which eventually can lead to hepatic damage and fatty liver (Ferreira *et al.*, 2012; Hirako *et al.*, 2011; Park *et al.*, 2002; Wang *et al.*, 2011). In the present study, animals supplemented with

HCD alone for six weeks had an elevated liver body weights ratio as compared to control animals. These findings are in accordance with the results from other investigators (Balkan *et al.*, 2004; Hahn-Obercyger *et al.*, 2009; Park *et al.*, 2002; Yiu *et al.*, 2011). Lipid compositions of cellular membranes as well as the extracellular matrix were reported to be more prone to free radical generation after HCD feeding (Scheuer *et al.*, 2000). In the present study, the observed significant reduction in the concentrations of DNA, RNA and total protein in hepatic tissues of HCD supplemented animals is a clear indication for cytotoxicity and cellular damage induced by HCD. Experimentally, HCD feeding to animals was found to increase the hepatic lipids concentrations in several studies (Kobayashi *et al.*, 2012a, 2012b). Similarly, there was a significant deposition of hepatic lipids such as total cholesterol and triglycerides following 6 consecutive weeks of HCD supplementation to the animals in the current study. Moreover, HCD feeding for six consecutive weeks resulted in a moderate degree of hepatotoxicity as demonstrated by the histopathological investigation. We suggest that the reported signs of hepatic degeneration and steatohepatosis along with cellular ballooning had resulted from lipids accumulation in the liver of HCD fed animals.

Rutin is one of the flavonoids glycoside known as vitamin-P, which is widely accepted as physiologic antioxidants. Flavonoids are now believed to have a strong potential to protect against the many degenerative diseases linked to free radical-related tissue damage due to their capacity that protect critical macromolecules, such as chromosomal DNA, structural proteins and enzymes and membrane lipids (Dreosti, 2000; Rice-Evans *et al.*, 1996). Rutin has been reported to exhibit multiple pharmacological activities including anti-inflammatory, vasoactive and membrane lipid peroxidation inhibitory properties (Ihme *et al.*, 1996; Lindahl and Tagesson, 1997; Lopez-Revuelta *et al.*, 2006; Park *et al.*, 2002). Vitamin C (ascorbic acid) is recognized for its effective ability to prevent and control various diseases including allergic rhinitis (Thornhill and Kelly, 2000), diabetes (Anderson *et al.*, 2006), heart disease (Ling *et al.*, 2002) and cancer (Enwonwu and Meeks, 1995). In the present study, RT and AA supplementation significantly prevented hypercholesterolemia induced liver injury. We believe that these effects are through the additive hepatoprotective effects of both vitamins. These findings are in accordance with other investigations, where both RT and AA were found to prevent hepatotoxicity and hepatic injury in different animal models (Abhilash *et al.*, 2012; Banerjee *et al.*, 2009; Janbaz *et al.*, 2002; Rana *et al.*, 2010; Shenbagam and Nalini, 2011). Both RT and AA are well recognized to

protect against free radicals induced tissue damage through several biological processes in many extracellular and intracellular reactions (Mahmoud, 2011; Ozkaya *et al.*, 2011). Measurements of hepatic DNA and RNA levels showed that RT and/or AA can attenuate HCD induced cytotoxic damage in liver tissues of the animals. ROS induced-cytotoxicity harmfully affects unsaturated fatty acids, which has been implicated in the pathogenesis of various diseases (Mahmoud, 2011). The cytoprotective effects of RT, as one of the phenolic flavonoids, and AA are also well established (Negre-Salvayre *et al.*, 1995; Passoni and Coelho, 2008). These cytoprotective effects are deemed to be through the ability to reduction of free radicals production, which is expected to powerfully protect cellular membranes and components.

Several studies demonstrated that both RT and AA have lipid lowering properties (Devbhuti *et al.*, 2011; Fernandes *et al.*, 2010; Mahmoudabadi *et al.*, 2011; Syed *et al.*, 2011; Ziaee *et al.*, 2009). Interestingly, the influence of the flavonoids on the endogenous regulation of cholesterol biosynthesis has been discussed in several previous studies (Attaway and Buslig, 1998; Borradaile *et al.*, 1999; Havsteen, 2002). In the current, study we investigated both single and combined ameliorative effects of the well known antioxidants RT and AA on the hepatocellular damage as well as fats deposition induced by HCD supplementation for 6 consecutive weeks to male Wistar rats. Biochemical measurement of hepatic concentration of total cholesterol and triglycerides revealed that both RT and AA either alone or in combination can significantly inhibit HCD induced hepatic lipids accumulation. On the other hand, several studies have suggested the potential improvement in the protective properties of dietary supplements and vitamins after their combination (Khan *et al.*, 2012; Rozanowska *et al.*, 2012). Qureshi *et al.* (2012) found that combining several dietary supplements can reduce cardiovascular risk factors in humans (Qureshi *et al.*, 2012). Moreover, vitamin E was found to enhance protective effects of ascorbate on light-induced toxicity to retinal pigment epithelial cells (Rozanowska *et al.*, 2012). According to the histopathological findings in the current study, supplementation of either RT or AA along with HCD resulted in mild degree of hepatotoxicity as compared to HCD fed group. However, combining both vitamins with HCD significantly ameliorated hepatocellular ballooning and steatohepatosis. Moreover, the degree of HCD induced hepatotoxicity was found to be positively correlated with hepatic total cholesterol and triglyceride concentrations. Therefore, we believe that the hepatoprotective properties reported in the present study may be due to the ability of RT and AA to inhibit hepatic lipids accumulation, which seems to be augmented by both vitamins combination.

ACKNOWLEDGMENT

The authors extend their appreciation to the Deanship of Scientific Research at King Saud University for funding the work through the research group project No RGP-VPP-179.

REFERENCES

- Abhilash, P.A., R. Harikrishnan and M. Indira, 2012. Ascorbic acid supplementation down-regulates the alcohol induced oxidative stress, hepatic stellate cell activation, cytotoxicity and mRNA levels of selected fibrotic genes in guinea pigs. *Free. Radic. Res.*, 46: 204-213.
- Anderson, R.A., L.M. Evans, G.R. Ellis, N. Khan, K. Morris, S.K. Jackson, A. Rees, M.J. Lewis and M.P. Frenneaux, 2006. Prolonged deterioration of endothelial dysfunction in response to postprandial lipaemia is attenuated by vitamin C in Type 2 diabetes. *Diabet. Med.* 23: 258-264.
- Arendt, B.M. and J.P. Allard, 2011. Effect of atorvastatin, vitamin E and C on nonalcoholic fatty liver disease: Is the combination required? *Am. J. Gastroenterol.*, 106: 78-80.
- Assy, N., 2011. Nutritional recommendations for patients with non-alcoholic fatty liver diseases. *World. J. Gastroenterol.*, 17: 3375-3376.
- Attaway, J.A. and B.S. Buslig, 1998. Antithrombogenic and antiatherogenic effects of citrus flavonoids. Contributions of Ralph C. Robbins. *Adv. Exp. Med. Biol.*, 439: 165-173.
- Balkan, J., S. Dogru-Abbasoglu, G. Aykac-Toker and M. Uysal, 2004. Serum pro-oxidant-antioxidant balance and low-density lipoprotein oxidation in healthy subjects with different cholesterol levels. *Clin. Exp. Med.*, 3: 237-242.
- Banerjee, P., S.S. Bhattacharyya, N. Bhattacharjee, S. Pathak, N. Boujedaini, P. Belon and A.R. Khuda-Bukhsh, 2009. Ascorbic acid combats arsenic-induced oxidative stress in mice liver. *Ecotoxicol. Environ. Saf.*, 72: 639-649.
- Borradaile, N.M., K.K. Carroll and E.M. Kurowska, 1999. Regulation of HepG2 cell apolipoprotein B metabolism by the citrus flavanones hesperetin and naringenin. *Lipids.*, 34: 591-598.
- Bregman, A., 1983. *Laboratory Investigation and Cell Biology*. John Wiley and Sons, New York.
- Browning, J.D. and J.D. Horton, 2004. Molecular mediators of hepatic steatosis and liver injury. *J. Clin. Invest.*, 114: 147-152.
- Choi, I., Y. Park, H. Choi and E.H. Lee, 2006. Anti-adipogenic activity of rutin in 3T3-L1 cells and mice fed with high-fat diet. *Biofactors*, 26: 273-281.
- Devbhuti, P., D. Sikdar, A. Saha and C. Sengupta, 2011. Protective effect of ascorbic acid on netilmicin-induced lipid profile and peroxidation parameters in rabbit blood plasma. *Acta. Pol. Pharm.*, 68: 15-22.
- Dreosti, I.E., 2000. Antioxidant polyphenols in tea, cocoa and wine. *Nutrition*, 16: 692-694.
- Dunn, W.A., G. Rettura, E. Seifter and S. Englard, 1984. Carnitine biosynthesis from gamma-butyrobetaine and from exogenous protein-bound 6-N-trimethyl-L-lysine by the perfused guinea pig liver. Effect of ascorbate deficiency on the in situ activity of gamma-butyrobetaine hydroxylase. *J. Biol. Chem.*, 259: 10764-10770.
- Enwonwu, C.O. and V.I. Meeks, 1995. Bionutrition and oral cancer in humans. *Crit. Rev. Oral. Biol. Med.*, 6: 5-17.
- Ersoz, G., F. Gunsar, Z. Karasu, S. Akay, Y. Batur and U.S. Akarca, 2005. Management of fatty liver disease with vitamin E and C compared to ursodeoxycholic acid treatment. *Turk. J. Gastroenterol.*, 16: 124-128.
- Farrell, G.C., N.C. Teoh and R.S. McCuskey, 2008. Hepatic microcirculation in fatty liver disease. *Anat. Rec. (Hoboken)*, 291: 684-692.
- Fernandes, A.A., E.L. Novelli, K. Okoshi, M.P. Okoshi, B.P. Di Muzio, J.F. Guimaraes and A. Fernandes Junior, 2010. Influence of rutin treatment on biochemical alterations in experimental diabetes. *Biomed. Pharmacother.*, 64: 214-219.
- Ferreira, A.O., A.P. Gollucke, J. Noguti, V.H. da Silva, E.T. Yamamura and D.A. Ribeiro, 2012. Grape juice concentrate modulates p16 expression in high fat diet-induced liver steatosis in Wistar rats. *Toxicol. Mech. Methods.*, 22: 218-224.
- Folch, J., M. Lees and G.H. Sloane Stanley, 1957. A simple method for the isolation and purification of total lipides from animal tissues. *J. Biol. Chem.*, 226: 497-509.
- Ha, T.Y., M. Otsuka and N. Arakawa, 1990. The effect of graded doses of ascorbic acid on the tissue carnitine and plasma lipid concentrations. *J. Nutr. Sci. Vitaminol. (Tokyo)*, 36: 227-234.
- Hahn-Obercyger, M., L. Graeve and Z. Madar, 2009. A high-cholesterol diet increases the association between caveolae and insulin receptors in rat liver. *J. Lipid. Res.*, 50: 98-107.
- Havsteen, B.H., 2002. The biochemistry and medical significance of the flavonoids. *Pharmacol. Ther.*, 96: 67-202.
- Hertog, M.G., E.J. Feskens, P.C. Hollman, M.B. Katan and D. Kromhout, 1993. Dietary antioxidant flavonoids and risk of coronary heart disease: The Zutphen elderly study. *Lancet*, 342: 1007-1011.
- Hirako, S., H.J. Kim, S. Shimizu, H. Chiba and A. Matsumoto, 2011. Low-dose fish oil consumption prevents hepatic lipid accumulation in high cholesterol diet fed mice. *J. Agric. Food. Chem.*, 59: 13353-13359.

- Ihme, N., H. Kiesewetter, F. Jung, K.H. Hoffmann, A. Birk, A. Muller and K.I. Grutzner, 1996. Leg oedema protection from a buckwheat herb tea in patients with chronic venous insufficiency: A single-centre, randomised, double-blind, placebo-controlled clinical trial. *Eur. J. Clin. Pharmacol.*, 50: 443-447.
- Janbaz, K.H., S.A. Saeed and A.H. Gilani, 2002. Protective effect of rutin on paracetamol- and CCl₄-induced hepatotoxicity in rodents. *Fitoterapia*, 73: 557-563.
- Khan, R.U., Z.U. Rahman, I. Javed and F. Muhammad, 2012. Effect of vitamins, probiotics and protein on semen traits in post-molt male broiler breeders. *Anim. Reprod. Sci.*, 135: 85-90.
- Kim, E.H., J.S. Bae, K.B. Hahm and J.Y. Cha, 2012. Endogenously synthesized n-3 polyunsaturated fatty acids in fat-1 mice ameliorate high-fat diet-induced non-alcoholic fatty liver disease. *Biochem. Pharmacol.*, 84(10): 1359-1365.
- Kobayashi, M., T. Harada, N. Takagi, K. Tsuzuki, M. Sugawara and M. Fukuda, 2012a. Effects of lactic acid-fermented soymilk on lipid metabolism-related gene expression in rat liver. *Biosci. Biotechnol. Biochem.*, 76: 19-24.
- Kobayashi, M., R. Hirahata, S. Egusa and M. Fukuda, 2012b. Hypocholesterolemic effects of lactic acid-fermented soymilk on rats fed a high cholesterol diet. *Nutrients*, 4: 1304-1316.
- Lee, M.K., Y.B. Park, S.S. Moon, S.H. Bok, D.J. Kim, T.Y. Ha, T.S. Jeong, K.S. Jeong and M.S. Choi, 2007. Hypocholesterolemic and antioxidant properties of 3-(4-hydroxyl) propanoic acid derivatives in high-cholesterol fed rats. *Chem. Biol. Interact.*, 170: 9-19.
- Lindahl, M. and C. Tagesson, 1997. Flavonoids as phospholipase A₂ inhibitors: Importance of their structure for selective inhibition of group II phospholipase A₂. *Inflammation*, 21: 347-356.
- Ling, L., S.P. Zhao, M. Gao, Q.C. Zhou, Y.L. Li and B. Xia, 2002. Vitamin C preserves endothelial function in patients with coronary heart disease after a high-fat meal. *Clin. Cardiol.*, 25: 219-224.
- Lopez-Revuelta, A., J.I. Sanchez-Gallego, A. Hernandez-Hernandez, J. Sanchez-Yague and M. Llanillo, 2006. Membrane cholesterol contents influence the protective effects of quercetin and rutin in erythrocytes damaged by oxidative stress. *Chem. Biol. Interact.*, 161: 79-91.
- Mahmoud, A.M., 2011. Influence of rutin on biochemical alterations in hyperammonemia in rats. *Exp. Toxicol. Pathol.*, 64(7-8): 783-789.
- Mahmoudabadi, M.M., M. Djalali, S.A. Djazayeri, S.A. Keshavarz, M.R. Eshraghian, A.A. Yaraghi, G. Askari, R. Ghiasvand and M. Zarei, 2011. Effects of eicosapentaenoic acid and vitamin C on glycemic indices, blood pressure and serum lipids in type 2 diabetic Iranian males. *J. Res. Med. Sci.*, 16(1): 361-367.
- Negre-Salvayre, A., L. Mabile, J. Delchambre and R. Salvayre, 1995. Alpha-tocopherol, ascorbic acid and rutin inhibit synergistically the copper-promoted LDL oxidation and the cytotoxicity of oxidized LDL to cultured endothelial cells. *Biol. Trace. Elem. Res.*, 47: 81-91.
- Nelson, P.J., R.E. Pruitt, L.L. Henderson, R. Jenness and L.M. Henderson, 1981. Effect of ascorbic acid deficiency on the in vivo synthesis of carnitine. *Biochim. Biophys. Acta.*, 672: 123-127.
- Oliveira, C.P., L.C. Gayotto, C. Tatai, B.I. Della Nina, E.S. Lima, D.S. Abdalla, F.P. Lopasso, F.R. Laurindo and F.J. Carrilho, 2003. Vitamin C and vitamin E in prevention of Nonalcoholic Fatty Liver Disease (NAFLD) in choline deficient diet fed rats. *Nutr. J.*, 2: 9.
- Ozkaya, D., M. Naziroglu, A. Armagan, A. Demirel, B.K. Koroglu, N. Colakoglu, A. Kukner and T.T. Sonmez, 2011. Dietary vitamin C and E modulates oxidative stress induced-kidney and lens injury in diabetic aged male rats through modulating glucose homeostasis and antioxidant systems. *Cell. Biochem. Funct.*, 29: 287-293.
- Park, S.Y., S.H. Bok, S.M. Jeon, Y.B. Park, S.J. Lee, T.S. Jeong and M.S. Choi, 2002. Effect of rutin and tannic acid supplements on cholesterol metabolism in rats. *Nutr. Res.*, 22: 283-295.
- Passoni, C.R. and C.A. Coelho, 2008. Ascorbic acid supplementation has a cytoprotective effect on secondary biliary cirrhosis: Experimental study in young rats. *J. Pediatr. Rio. J.*, 84: 522-528.
- Postic, C. and J. Girard, 2008. Contribution of de novo fatty acid synthesis to hepatic steatosis and insulin resistance: Lessons from genetically engineered mice. *J. Clin. Invest.*, 118: 829-838.
- Qureshi, A.A., D.A. Khan, W. Mahjabeen, C.J. Papan and N. Qureshi, 2012. Suppression of nitric oxide production and cardiovascular risk factors in healthy seniors and hypercholesterolemic subjects by a combination of polyphenols and vitamins. *J. Clin. Exp. Cardiol.*, S5: 8.
- Rana, T., A.K. Bera, S. Das, D. Pan, S. Bandyopadhyay, D. Bhattacharya, S. De and S.K. Das, 2010. Supplementation of ascorbic acid prevents oxidative damages in arsenic-loaded hepatic tissue of rat: An ex vivo study. *Hum. Exp. Toxicol.*, 29: 965-972.
- Rice-Evans, C.A., N.J. Miller and G. Paganga, 1996. Structure-antioxidant activity relationships of flavonoids and phenolic acids. *Free. Radic. Biol. Med.*, 20: 933-956.
- Rozanowska, M., L. Bakker, M.E. Boulton and B. Rozanowski, 2012. Concentration dependence of vitamin C in combinations with vitamin e and zeaxanthin on light-induced toxicity to retinal pigment epithelial cells. *Photochem. Photobiol.*, 88: 1408-1417.

- Schacterle, G.R. and R.L. Pollack, 1973. A simplified method for the quantitative assay of small amounts of protein in biologic material. *Anal. Biochem.*, 51: 654-655.
- Scheuer, H., W. Gwinner, J. Hohbach, E.F. Grone, R.P. Brandes, E. Malle, C.J. Olbricht, A.K. Walli and H.J. Grone, 2000. Oxidant stress in hyperlipidemia-induced renal damage. *Am. J. Physiol. Renal. Physiol.*, 278: 63-74.
- Shenbagam, M. and N. Nalini, 2011. Dose response effect of rutin a dietary antioxidant on alcohol-induced prooxidant and antioxidant imbalance-a histopathologic study. *Fundam. Clin. Pharmacol.*, 25: 493-502.
- Syed, N.I., S. Arshad, A.A. Syed, M. Ahmad, F.Z. Khan and B. Ahmad, 2011. A comparative study of antioxidant vitamins and simvastatin in hypercholesterolemia rabbits. *Pak. J. Pharm. Sci.*, 24: 479-484.
- Thornhill, S.M. and A.M. Kelly, 2000. Natural treatment of perennial allergic rhinitis. *Altern. Med. Rev.*, 5: 448-454.
- Tomofuji, T., T. Azuma, H. Kusano, T. Sanbe, D. Ekuni, N. Tamaki, T. Yamamoto and T. Watanabe, 2006. Oxidative damage of periodontal tissue in the rat periodontitis model: Effects of a high-cholesterol diet. *FEBS. Lett.*, 580: 3601-3604.
- Trauner, M., M. Arrese and M. Wagner, 2010. Fatty liver and lipotoxicity. *Biochim. Biophys. Acta.*, 1801: 299-310.
- Vasu, V.T., H. Modi, J.V. Thaikootathil and S. Gupta, 2005. Hypolipidaemic and antioxidant effect of *Enicostemma littorale* Blume aqueous extract in cholesterol fed rats. *J. Ethnopharmacol.*, 101: 277-282.
- Wang, X., J. Hasegawa, Y. Kitamura, Z. Wang, A. Matsuda, W. Shinoda, N. Miura and K. Kimura, 2011. Effects of hesperidin on the progression of hypercholesterolemia and fatty liver induced by high-cholesterol diet in rats. *J. Pharmacol. Sci.*, 117: 129-138.
- Yang, L., J.H. Chen, T. Xu, A.S. Zhou and H.K. Yang, 2012. Rice protein improves oxidative stress by regulating glutathione metabolism and attenuating oxidative damage to lipids and proteins in rats. *Life. Sci.*, 91: 389-394.
- Yiu, W.F., P.L. Kwan, C.Y. Wong, T.S. Kam, S.M. Chiu, S.W. Chan and R. Chan, 2011. Attenuation of fatty liver and prevention of hypercholesterolemia by extract of *curcuma longa* through regulating the expression of CYP7A1, LDL-receptor, HO-1 and HMG-CoA reductase. *J. Food. Sci.*, 76: 80-89.
- Ziaee, A., F. Zamansoltani, M. Nassiri-Asl and E. Abbasi, 2009. Effects of rutin on lipid profile in hypercholesterolaemic rats. *Basic. Clin. Pharmacol. Toxicol.*, 104: 253-258.