

Research Article

Morin a Flavonoid Exerts Antioxidant Potential in Streptozotocin-induced Hepatotoxicity

Osama A. Alkhamees

Department of Pharmacology, College of Medicine, Al Imam Mohammad Ibn Saud Islamic University,
P.O. Box 11623, Riyadh, Saudi Arabia, Tel.: 00966-500844476, Fax: 00966-14679014

Abstract: Although diabetic hepatopathy is potentially less common, it may be appropriate for addition to the list of target organ conditions related to diabetes. This study was designed to evaluate the hepatoprotective activity of morin in Streptozotocin (STZ)-induced diabetes rats. Morin (15 and 30 mg/kg/day) was treated to diabetic rats for five consecutive weeks. In serum, fasting glucose and Alkaline Phosphatase (ALP) levels were estimated and found significant increase in diabetic group as compared to controls. Nucleic acids, total protein, Malondialdehyde (MDA), Total Glutathione (T-GSH), Non-Protein Sulphydral (NP-SH) levels and Superoxide Dismutase (SOD) activity was measured in hepatic cells. Oxidative stress was confirmed by increasing MDA and decreasing T-SHG, NP-SH and nucleic acid levels and SOD activity in hepatic cells of diabetic rats. Morin treatment to diabetic rats significantly reduced the STZ-induced oxidative stress by following decrease MDA and increase T-GSH, DNA levels and increase SOD activity in hepatic cells respectively. These biochemical findings were matched with histopathological verifications. The findings obtained from this study indicate that morin exerts protection to STZ-induced diabetic rats against oxidative stress. This could be due to prevention or inhibition of lipid peroxidative system by its antioxidant and hepatoprotective effect. In conclusion, morin has been shown to possess antidiabetic effect in STZ-induced detoxication and antioxidant properties. But the exact underlying mechanism needs to be elucidated.

Keywords: Antioxidant, diabetes, hepatoprotective, morin, streptozotocin

INTRODUCTION

Diabetes Mellitus (DM) is one of the most prevalent chronic metabolic disorder and a major health problem around the world. The predictions on diabetes prevalence after 20 years denoted around half a billion adults will be registered as diabetic and that may go up to 8% of the whole world population (Shaw *et al.*, 2010). Numerous studies have reported that DM is associated with oxidative stress, leading to an increased production of Reactive Oxygen Species (ROS) where they formed as natural toxic byproducts of the normal metabolism of oxygen, including superoxide radical ($O_2^{\cdot-}$), hydrogen peroxide (H_2O_2) and hydroxyl radical (OH^{\cdot}) or diminution of antioxidant defense system (Vincent *et al.*, 2004). Inference of oxidative stress in the pathogenesis of diabetes mellitus is suggested not only by ROS generation but also due to non-enzymatic protein glycosylation, auto-oxidation of glucose; weaken antioxidant enzyme and formation of peroxides (Vincent *et al.*, 2004; Pari and Latha, 2005). Lipid Peroxidation (LPO) is a key marker of oxidative stress. It is a free radical-induced progression causing oxidative worsening of polyunsaturated fatty acids that eventually consequences in extensive membrane damage and dysfunction. The noteworthy extent of LPO products that was measured as Thiobarbituric

Acid Reactive Substances (TBARS) has been reported in diabetes (Pari and Latha, 2005; Rajasekaran *et al.*, 2005). Non-enzymatic and uncontrolled oxidation of biomolecules by ROS impairs the structural and functional integrity of DNA. ROS may play a major role as endogenous initiators and promoters of DNA damage and mutations that contribute to diabetes (Kim *et al.*, 2012). Cells typically defend themselves against ROS damage using enzymes such as superoxide dismutases, catalases, lactoperoxidases and glutathione peroxidases (Matough *et al.*, 2012). Streptozotocin (STZ) a well-known genotoxic agent, causing ROS generation and induce oxidative damage following by diabetic induction. It is frequently used in experimental diabetic studies in animals.

Morin is one of the naturally occurring bioflavonoids, originally isolated from members of the Moraceae family. It can be found in different herbs and fruits such as onion, seed weeds, mill (*Prunus dulcis*), fig (*Chlorophora tinctoria*), almond (*P. guajava* L.), red wine and Osage orange (Sreedharan *et al.*, 2009; Nandhakumar *et al.*, 2012). Morin exhibited several pharmacological properties including antioxidant (Prahalthan *et al.*, 2012; Merwid-Lad *et al.*, 2012), anti-inflammatory (Fang *et al.*, 2003), chemoprotective (Kawabata *et al.*, 1999), anticancer (Kuo *et al.*, 2007) and anti-promotion (Iwase *et al.*, 2001). Furthermore,

morin decreased the oxidative damage of cardiovascular cells (Wu *et al.*, 1994; Kok *et al.*, 2000), lung fibroblast cells (Zhang *et al.*, 2009), hepatocytes and neurons (Ishige *et al.*, 2001; Ibarretxe *et al.*, 2006). Studies have showed that morin administration to experimental animals even at higher concentration for prolonged period do not have any toxicity (Prahalthan *et al.*, 2012; Yugarani *et al.*, 1992). Aim of this study was to evaluate the effect of morin on lipid peroxidation and antioxidant status in STZ-induced experimental diabetic in male rats.

MATERIALS AND METHODS

Animals: Adult male Wistar albino rats, weighing 250-270 g were received from experimental Animal Care Center (College of Pharmacy, King Saud University, Riyadh). All animals were maintained under controlled conditions of temperature (22±1°C), humidity (50-55%) and light (12 h light/12 h dark cycle). They were acclimatized to the laboratory conditions for 7 days before the start of the experiment. Animals had free access to Purina rat chow (Manufactured by Grain Silos & Flour Mills Organization, Riyadh, Saudi Arabia) and drinking water. All experimental procedure including euthanasia was conducted in accordance with the National Institute of Health Guide for the Care and Use of Laboratory Animals, Institute for Laboratory Animal Research (NIH Publications No. 80-23; 1996) as well as Ethical Guidelines of the Experimental Animal Care Centre, College of Pharmacy, King Saud University (KSU), Riyadh, Kingdom Saudi Arabia (KSA).

Materials: Streptozotocin (N- [methyl nitroso carbamoyl] - α -D-glucosamine), Morin (3, 3', 5, 5', 7-pentahydroxyflavon) were purchased from Sigma Chemical Co., USA and Riedel-de Haën Co., USA respectively. All other chemicals used were of the highest analytical grade.

Experimental model of diabetes: Experimental diabetes was induced by a single dose of STZ (65 mg/kg, *i.p.*) in overnight fasted rats by dissolving in freshly prepared 5 mmol/L citrate buffer (pH 4.5). After Streptozotocin injection, the rats had free access to glucose solution (5%) for 24 h to avoid and/or attenuate subsequent inevitable hyperinsulinemia and hypoglycemic shock. Forty-eight h after the Streptozotocin injection, animals were fasted overnight and a drop of blood samples were analyzed for glucose levels (mg/dL) by using strips on glucometer (ACCUCHEK ACTIVE, Roche, Germany). Individual glucose levels reached above 250 mg/dL is considered as diabetic.

Experimental design: In control group, normal healthy rats were taken and used as vehicle. Diabetic-induced rats randomly divided into three groups (six rats in each

group); untreated diabetic group (vehicle), diabetic rats treated with low taken dose (15 mg/kg/day) of morin and treated with high taken dose (30 mg/kg/day) of morin. Vehicle and drug treatments were continued for five consecutive weeks. Weekly food-intake and water-intake were measured during 24 h. Weekly body weight of each animal was recorded on same day and time then finally calculated the weight increase during treatment. On end of the treatment, animals were fasted overnight, blood samples were obtained under light anesthesia and finally they were sacrificed. Whole liver of each rat was dissected, a small portion of it was dipped in liquid nitrogen for one minute then kept in freezer at -80°C till analysis. The blood samples were allowed to stand for 30 min at room temperature and then centrifuged at 3000 rpm for 10 min to separate the serum. Serum samples were kept in a freezer at -20°C till analysis. A cross-section of liver from each group was preserved in 10% formalin for histopathology.

Serum parameters: Serum glucose and alkaline phosphatase levels were estimated by using commercially available diagnostic kits (Randox Lab Limited, U.K. and Human GmbH, Germany).

Tissue parameters: Liver tissues were homogenized in 50 mM phosphate buffered saline (pH 7.4) by using a glass homogenizer (Omni International, Kennesaw, GA, USA). Half of the homogenates were centrifuged at 1000 g for 10 min at 4°C to separate nuclei and unbroken cells. The pellet was discarded and a portion of supernatant was again centrifuged at 12000 g for 20 min to obtain post-mitochondrial supernatant. In homogenate, MDA, T-GSH and NP-SH levels were estimated. In post-mitochondrial supernatant, SOD activity was measured.

Estimation of MDA levels in liver: A Thiobarbituric Acid Reactive Substances (TBARS) assay kit (Zepto Metrix) was used to measure the lipid peroxidation products, Malondialdehyde (MDA) equivalents. One hundred microliters of homogenate was mixed with 2.5 mL reaction buffer (provided by the kit) and heated at 95°C for 60 min. After the mixture had cooled, the absorbance of the supernatant was measured at 532 nm using a spectrophotometer. The lipid peroxidation products are expressed in terms of nmoles MDA/mg protein using molar extinction coefficient of MDA-thiobarbituric chromophore (1.56×10^5 M/cm).

Estimations of T-GSH and NP-SH levels in liver: The concentration of T-GSH was measured using the method described by Sedlak and Lindsay (1968). Homogenate was mixed with 0.2 M Tris buffer, pH 8.2 and 0.1 mL of 0.01 M Ellman's reagent, [5,5'-dithiobis-(2-nitro-benzoic acid)] (DTNB). Each sample tube was centrifuged at 3000 g at room temperature for 15 min.

The absorbance of the clear supernatants was measured using spectrophotometer at 412 nm in 1 cm quartz cells.

For NP-SH estimation, homogenate was mixed in 15.0 mL test tubes with 4.0 mL distilled H₂O and 1.0 mL of 50% Trichloroacetic Acid (TCA). The tubes were shaken intermittently for 10-15 min and centrifuged for 15 min at approximately 3000 g. Two ml of supernatant was mixed with 4.0 mL of 0.4 M Tris buffer, pH 8.9, 0.1 mL DTNB added and the sample shaken. The absorbance was read within 5 min of the addition of DTNB at 412 nm against a reagent blank with no homogenate.

Determination of nucleic acids and total protein levels in liver tissues: The method described by Bregman (1983) was used to estimate DNA and RNA levels in liver homogenate. Briefly, tissues were homogenized in ice-cold distilled water. The homogenates were then suspended in 10% ice-cold Trichloroacetic Acid (TCA). Pellets were extracted twice with 95% ethanol. The nucleic acids extract was treated either with diphenylamine or orcinolreagent for quantification of DNA and RNA levels, respectively. The modified Lowry method by Schacterle and Pollack (1973) was used to estimate levels of total protein in liver using bovine plasma albumin as a standard.

Estimations of SOD activity in liver: The activity of SOD in liver was estimated using the method described by Kono (1978) with the aid of nitroblue tetrazolium as the indicator. Superoxide anions are generated by the oxidation of hydroxylamine hydrochloride. The reduction of nitroblue tetrazolium to blue formazon mediated by superoxide anions was measured 560 nm under aerobic conditions. Addition of superoxide dismutase inhibits the reduction of nitroblue tetrazolium and the extent of inhibition is taken as a measure of enzyme activity. The SOD activity was expressed as units/mg protein.

Histopathological examination of liver tissues: Liver tissues were fixed in 10% neutral buffered formalin, embedded in paraffin wax and sectioned at 3 μm. Sections were then stained with Hematoxylin and Eosin (H&E) stain and placed in slides for light microscopic examination. Slides were evaluated by a histopathologist who was blinded to the treatment groups to avoid any kind of bias.

Statistical analysis: All data were expressed as mean±S.D. Data were statistically analyzed using one-way ANOVA followed by Student-Newman-Keuls multiple comparisons test. The differences were considered statistically significant at p<0.05. Graph Pad prism program (version 5) was used as analyzing software.

RESULTS

Mean initial body weights of all animals were same. In all diabetic groups, body weights were significantly (p<0.001) decreased as compared to control group (Fig. 1a). In correspondent to body weights, liver weights significantly (p<0.001) increased in all diabetic groups compared to control rats. Morin treatments with two different doses (15 and 30 mg/kg/day) to diabetic rats for five consecutive weeks neither corrected the body weights nor liver weights while compared to untreated diabetic rats (Fig. 1b).

Although the weight of diabetic rats significantly decreased but their food and water intake were significantly (p<0.001) more than normal control rats. Higher food and water intake trendy was found either in morin treated groups (Fig. 2a and b).

Blood analysis showed significant (p<0.001) elevation in both glucose and ALP levels in diabetic rats as compared to control animals. Only the higher dose of morin (30 mg/kg) significantly (p<0.01) inhibited the elevated glucose level in diabetic rats while compared to untreated diabetic rats. While both doses of morin (15 and 30 mg/kg) significantly (p<0.05 and p<0.01, respectively) reduced the increased levels of ALP as compared to STZ group (Fig. 3a and b).

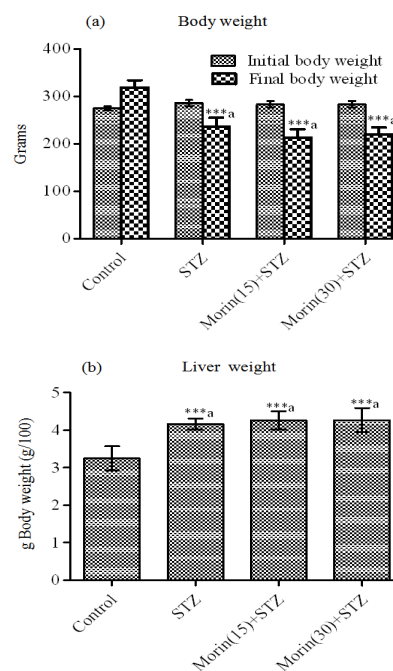


Fig. 1: Effect of morin on mean body and liver weights of diabetic rats

Data were expressed as Mean±S.D. and analyzed using one-way ANOVA followed by Student-Newman-Keuls multiple comparisons test; Six rats were used in each group; ^a: All the diabetic groups were compared with control; ^b: Morin treated groups were compared with STZ group; Statistical significance was considered as *p<0.05, **p<0.01 and ***p<0.001

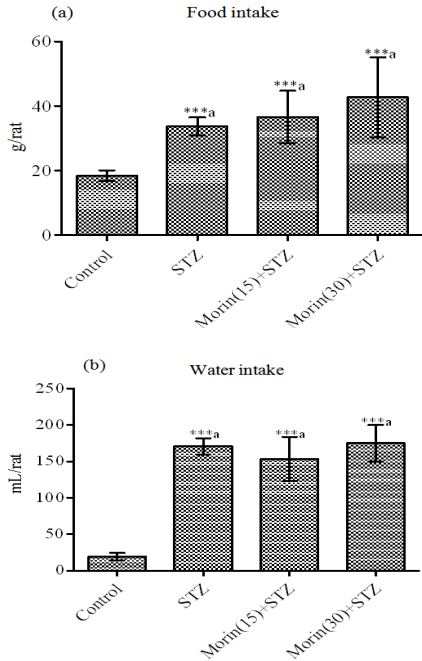


Fig. 2: Effect of morin on mean food and water intakes of diabetic rats

Data were expressed as Mean±S.D. and analyzed using one-way ANOVA followed by Student-Newman-Keuls multiple comparisons test; Six rats were used in each group; ^a: All the diabetic groups were compared with control; ^b: Morin treated groups were compared with STZ group; Statistical significance was considered as *p<0.05, **p<0.01 and ***p<0.001

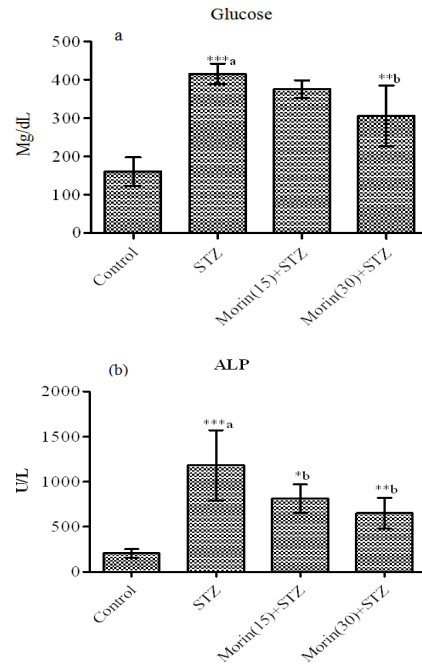


Fig. 3: Effect of morin on serum fasting glucose and ALP levels of diabetic rats

Data were expressed as Mean±S.D. and analyzed using one-way ANOVA followed by Student-Newman-Keuls multiple comparisons test; Six rats were used in each group; ^a: All the diabetic groups were compared with control; ^b: Morin treated groups were compared with STZ group; Statistical significance was considered as *p<0.05, **p<0.01 and ***p<0.001

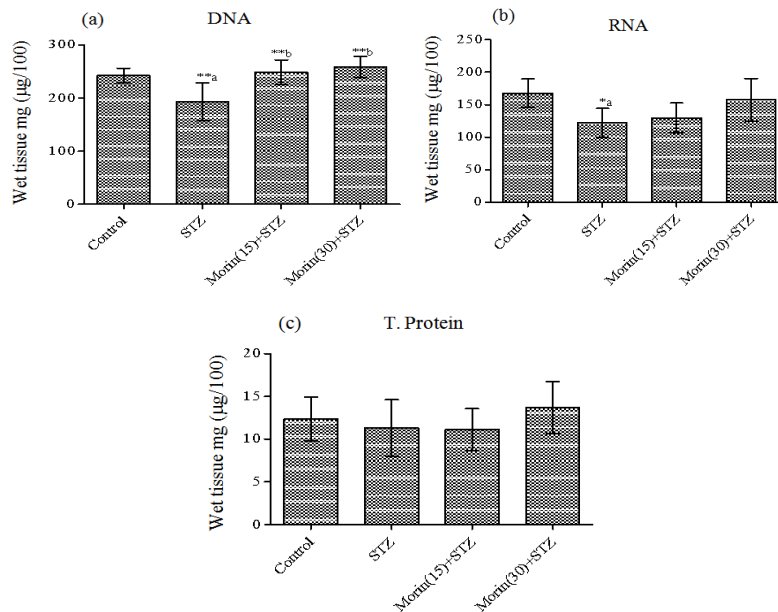


Fig. 4: Effect of morin on DNA, RNA and total protein levels of hepatic cells in diabetic rats

Data were expressed as Mean±S.D. and analyzed using one-way ANOVA followed by Student-Newman-Keuls multiple comparisons test; Six rats were used in each group; ^a: All the diabetic groups were compared with control; ^b: Morin treated groups were compared with STZ group; Statistical significance was considered as *p<0.05, **p<0.01 and ***p<0.001

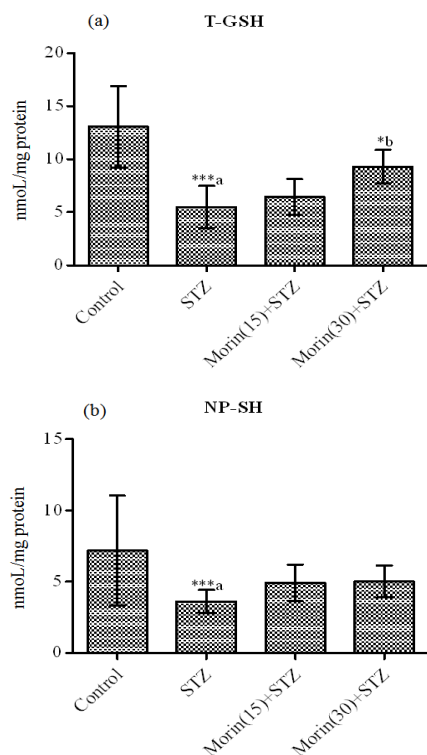


Fig. 5: Effect of morin on T-GSH and NP-SH levels of hepatic cells in diabetic rats

Data were expressed as Mean±S.D. and analyzed using one-way ANOVA followed by Student-Newman-Keuls multiple comparisons test; Six rats were used in each group; ^a: All the diabetic groups were compared with control; ^b: Morin treated groups were compared with STZ group; Statistical significance was considered as * $p < 0.05$, ** $p < 0.01$ and *** $p < 0.001$

There was a significant decrease in both DNA and RNA concentrations ($p < 0.01$ and $p < 0.05$, respectively) in STZ group as compared to controls animals (Fig. 4a and b). Although the hepatic total protein levels remained same in all the groups (Fig. 4c). A significant ($p < 0.01$) decrease was seen only in DNA levels after the morin treatments compared to STZ group (Fig. 4b).

Oxidative markers including T-GSH and NP-SH levels decreased significantly ($p < 0.001$) in hepatic cells of diabetic rats as compared to control rats (Fig. 5a and b). Morin (30 mg/kg/day) treatment to diabetic rats significantly ($p < 0.05$) elevated the T-GSH levels as compared to untreated diabetic rats (Fig. 5a).

In diabetic animals, hepatic MDA levels was significantly ($p < 0.001$) increased compared to control rats. Morin treatments with both the doses significantly ($p < 0.001$) reduced the elevated MDA levels as compared to untreated diabetic rats (Fig. 6A). Oxidative enzyme activity like SOD decreased significantly ($p < 0.05$) in hepatic cells of diabetic rats. Five consecutive weeks treatment of morin to diabetic rats, significantly enhanced the SOD activity as dose dependent manner (Fig. 6b).

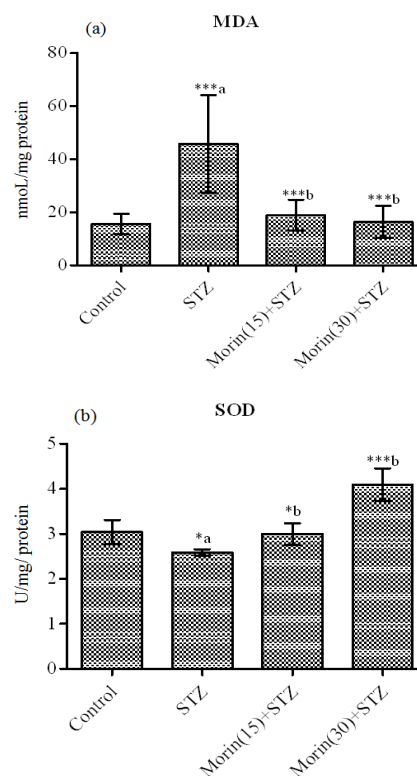


Fig. 6: Effect of morin on MDA levels and SOD activity of hepatic cells in diabetic rats

Data were expressed as Mean±S.D. and analyzed using one-way ANOVA followed by Student-Newman-Keuls multiple comparisons test; Six rats were used in each group; ^a: All the diabetic groups were compared with control; ^b: Morin treated groups were compared with STZ group; Statistical significance was considered as * $p < 0.05$, ** $p < 0.01$ and *** $p < 0.001$

Histopathological evaluation is depicted as follows: In control rat, normal and benign looking liver hepatocytes with normal looking central veins (Fig. 7A). In diabetic rat, liver hepatocytes showed dilated, congested central veins, few perivascular inflammatory cells infiltrate and some degenerative process with ballooning degeneration and also few cells with fatty degeneration with vacuolated hepatocytes and presence of occasionally binucleated cells (Fig. 7B). After morin (15 mg/kg/day) treatment to diabetic rats for five weeks, hepatocytes looked benign, arranged in trabecular pattern separated by blood sinusoids with centrally placed congested central veins. Few periportal inflammatory cells were notified (Fig. 7C). However, neither fibrosis nor degenerative changes were seen. Treatment with higher dose (30 mg/kg/day) to diabetic rats, the slide showed benign looking hepatocytes arranged in trabeculae separated by blood sinusoids with centrally placed congested dilated congested central veins (Fig. 7D).

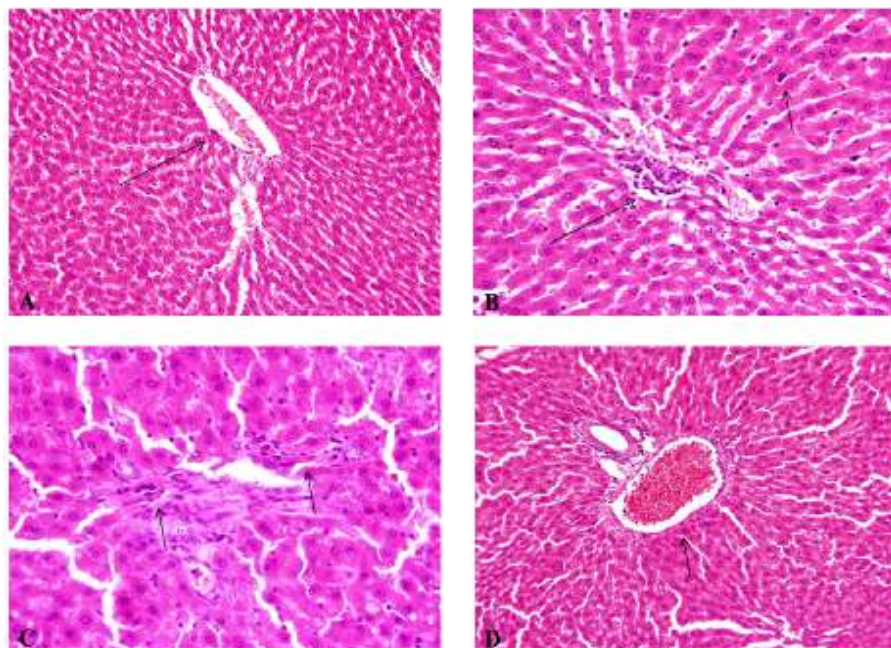


Fig. 7: (A) In control rat, normal and benign looking liver hepatocytes with normal looking central veins, (B) in diabetic rat, liver hepatocytes showed dilated, congested central veins, few perivascular inflammatory cells infiltrate and some degenerative process with ballooning degeneration and also few cells with fatty degeneration with vacuolated hepatocytes and presence of occasionally binucleated cells, (C) after morin (15 mg/kg/day) treatment to diabetic rats for five weeks, hepatocytes looked benign, arranged in trabecular pattern separated by blood sinusoids with centrally placed congested central veins. Few periportal inflammatory cells were notified. However, neither fibrosis nor degenerative changes were seen, (D) treatment with higher dose (30 mg/kg/day) to diabetic rats, the slide showed benign looking hepatocytes arranged in trabeculae separated by blood sinusoids with centrally placed congested dilated congested central veins

DISCUSSION

Several studies have shown an association between hyperglycemia and decreased body weight of diabetic animals (Zafar and Naqvi, 2010; Okon *et al.*, 2012). In the present study, also body weights of diabetic animals significantly ($p < 0.001$) decreased while compared to control rats. In contrast, liver weights in proportion to the body weight increased significantly. It could be attributed to increased triglyceride accumulation leading to enlarged liver which could be due to the increased influx of fatty acids into the liver induced by hypoinsulinemia and the low capacity of excretion of lipoprotein secretion from liver resulting from a deficiency of apolipoprotein B synthesis. Present finding of this study are in agreement with the findings of Habibuddin *et al.* (2008) and Lee *et al.* (2008). However, morin treatment to diabetic rats could not bring back these changes to normal.

The present data revealed that, serum fasting glucose levels significantly increased in STZ injected animals. It is widely accepted that administration of STZ damages the pancreatic β -cells and resulted diabetes by elevating glucose levels and diminishing insulin levels (Duhaiman, 1995). Morin treatment with higher taken dose (30 mg/kg) for 5 consecutive weeks significantly decreased the level of glucose. In an

earlier study, Vishnukumar *et al.* (2012) reported that, morin (50 mg/kg) treatment for 45 days decreased the glucose levels in STZ injected rats. This effect could be due to the regeneration of existing pancreatic β -cells in STZ-induced diabetic rats. Increased levels of enzymes such as ALP an indicator of cellular infiltration and functional disturbance of liver cell membranes (Drotman and Lawhorn, 1978). In addition, ALP is membrane bound and its alteration is likely to affect the membrane permeability and produce derangement in the transport of metabolites (Mehana *et al.*, 2012). In present study, serum ALP concentrations also significantly elevated in diabetic rats. Morin treatments significantly decreased the elevated ALP levels by showing its antioxidant nature. These results are in agreement with earlier study where morin treatment reduced ALP levels against doxorubicin-induced toxicity in rats (Parabathina *et al.*, 2011).

High glucose has been shown to increase ROS in many cell types in patients as well as experimental animals with diabetes due to combination of increased production of ROS along with decreased antioxidant function (Das and Sil, 2012; Bell and Allbright, 2007). Hence oxidative stress is a major contributor to the development of diabetic complications related to progression in liver (Meng and Cui, 2008). Present study showed decreased antioxidant enzymes activity

and the level of natural antioxidant GSH, with increased MDA as lipid peroxidation marker under high glucose stress. Morin, a flavonoid and a known antioxidant, was able to restore the activities of antioxidant enzymes, levels of GSH and MDA concentrations in hepatic cells. Decreased levels of antioxidants and decreased expression of Mn-SOD, Catalase, GPX and GSH level have been reported under hyperglycaemic state (Mokini *et al.*, 2010; Yu *et al.*, 2006; Meng and Cui, 2008). Excessive ROS generation can also be a causative factor for alteration in antioxidant enzymes activity (Bell and Allbright, 2007). Subash and Subramanian (2009) reported that, morin significantly enhanced the SOD and Catalase (CAT) activity in liver of hyperammonemic rats.

The biochemical findings obtained from this study indicates that morin exerts protection to STZ-induced diabetic rats against oxidative stress. This could be due to prevention or inhibition of lipid peroxidative system by its antioxidant and hepatoprotective effect. In summary, morin has been shown to possess antidiabetic effect in STZ-induced detoxication and antioxidant properties. But the exact mechanism is still unclear and further research is needed.

REFERENCES

- Bell, D.S. and E. Allbright, 2007. The multifaceted associations of hepatobiliary disease and diabetes. *Endocr. Pract.*, 13: 300-312.
- Bregman, A., 1983. *Laboratory Investigation and Cell Biology*. John Wiley and Sons, New York, pp: 51-60.
- Das, J. and P.C. Sil, 2012. Taurine ameliorates alloxan-induced diabetic renal injury, oxidative stress-related signaling pathways and apoptosis in rats. *Amino. Acids.*, 43(4): 1509-1523.
- Drotman, R. and G. Lawhorn, 1978. Serum enzymes as indicators of chemically induced liver damage. *Drug Chem. Toxicol.*, 1(2): 163-171.
- Duhaiman, A.S., 1995. Glycation of human lens proteins from diabetic and (non-diabetic) senile cataract patients. *Glycoconjugate. J.*, 12: 618-621.
- Fang, S.H., Y.C. Hou, W.C. Chang, S.L. Hsiu, P.D. Chao and B.L. Chiang, 2003. Morin sulfates/glucuronides exert anti-inflammatory activity on activated macrophages and decreased the incidence of septic shock. *Life. Sci.*, 74: 743-756.
- Habibuddin, M., H.A. Daghri, T. Humaira, M.S. Al-Qahtani and A.A. Hefzi, 2008. Antidiabetic effect of alcoholic extract of *Caralluma sinaica* L. on streptozotocin-induced diabetic rabbits. *J. Ethnopharmacol.*, 117(2): 215-220.
- Ibarretxe, G., M.V. Sanchez-Gomez, M.R. Campos-Esparza, E. Alberdi and C. Matute, 2006. Differential oxidative stress in oligodendrocytes and neurons after excitotoxic insults and protection by natural polyphenols. *GLIA*, 53: 201-211.
- Ishige, K., D. Schubert and Y. Sagara, 2001. Flavonoids protect neuronal cells from oxidative stress by three distinct mechanisms. *Free. Radic. Biol. Med.*, 30: 433-446.
- Iwase, Y., Y. Takemura, M. Ju-ichi, T. Mukainaka, E. Ichiishi, C. Ito, H. Furukawa, M. Yano, H. Tokuda and H. Nishino, 2001. Inhibitory effect of flavonoid derivatives on epstein-barr virus activation and two-stage carcinogenesis of skin tumors. *Cancer. Lett.*, 173: 105-109.
- Kawabata, K., T. Tanaka, S. Honjo, M. Kakumoto, A. Hara, H. Makita, N. Tatematsu, J. Ushida, H. Tsuda and H. Mori, 1999. Chemopreventive effect of dietary flavonoid morin on chemically induced rat tongue carcinogenesis. *Int. J. Cancer.*, 83: 381-386.
- Kim, J.J., R. Thiyagarajan and S.G. Kim, 2012. Protective effects of *Chrysanthemi flos* extract against streptozotocin-induced oxidative damage in diabetic mice. *J. Med. Plant. Res.*, 6(4): 622-630.
- Kok, L.D., Y.P. Wong, T.W. Wu, H.C. Chan, T.T. Kwok and K.P. Fung, 2000. Morin hydrate: A potential antioxidant in minimizing the free-radicals-mediated damage to cardiovascular cells by anti-tumor drugs. *Life. Sci.*, 67: 91-99.
- Kono, Y., 1978. Generation of superoxide radical during autooxidation of hydroxylamine and an assay for superoxide dismutase. *Arch. Biochem. Biophys.*, 186: 189-195.
- Kuo, H.M., L.S. Chang, Y.L. Lin, H.F. Lu, J.S. Yang, J.H. Lee and J.G. Chung, 2007. Morin inhibits the growth of human leukemia HL-60 cells via cell cycle arrest and induction of apoptosis through mitochondria dependent pathway. *Anticancer. Res.*, 27: 395-405.
- Lee, S.I., J.S. Kim, S.H. Oh, K.Y. Park, H.G. Lee and S.D. Kim, 2008. Antihyperglycemic effect of *Fomitopsis pinicola* extracts in streptozotocin-induced diabetic rats. *J. Med. Food.*, 11(3): 518-524.
- Matough, F.A., S.B. Budin, Z.A. Hamid, N. Alwahaibi and J. Mohamed, 2012. The role of oxidative stress and antioxidants in diabetic complications. *Sultan. Qaboos. Univ., Med. J.*, 12: 5-18.
- Mehana, E.E., A.R. Meki and K.M. Fazili, 2012. Ameliorated effects of green tea extract on lead induced liver toxicity in rats. *Exp. Toxicol. Pathol.*, 64(4): 291-295.
- Meng, L. and L. Cui, 2008. Inhibitory effects of crocetin on high glucose-induced apoptosis in cultured human umbilical vein endothelial cells and its mechanism. *Arch. Pharm. Res.*, 31: 357-363.
- Merwid-Lad, A., M. Trocha, E. Chlebda, T. Sozanski, J. Magdalan, D. Ksiadzyna, M. Kopacz, A. Kuzniar, D. Nowak and M. Piesniewska, 2012. Effects of morin-5'-sulfonic acid sodium salt (Na MSA) on cyclophosphamide-induced changes in oxido-redox state in rat liver and kidney. *Hum. Exp. Toxicol.*, 31: 812-819.

- Mokini, Z., M.L. Marcovecchio and F. Chiarelli, 2010. Molecular pathology of oxidative stress in diabetic angiopathy: Role of mitochondrial and cellular pathways. *Diabetes. Res. Clin. Pract.*, 87: 313-321.
- Nandhakumar, R., K. Salini and S.N. Devaraj, 2012. Morin augments anticarcinogenic and antiproliferative efficacy against 7, 12-dimethylbenz (a)-anthracene induced experimental mammary carcinogenesis. *Mol. Cell. Biochem.*, 364: 79-92.
- Okon, U.A., D.U. Owo, N.E. Udokang, J.A. Udobang and C.E. Ekpenyong, 2012. Oral administration of aqueous leaf extract of *Ocimum gratissimum* ameliorates polyphagia, polydipsia and weight loss in streptozotocin-induced diabetic rats. *Am. J. Med. and Med. Sci.*, 2(3): 45-49.
- Parabathina, R.K., E. Murlinath, G. Kishore and K.S. Somasekhara Rao, 2011. Effect of vitamin E, morin, rutin and quercetin against DOX induced oxidative stress. *Int. J. Appl. Biol. Pharma. Tech.*, 2(2): 399-408.
- Pari, L. and M. Latha, 2005. Antidiabetic effect of *Scoparia dulcis*: Effect on lipid peroxidation in streptozotocin diabetes. *Gen. Physiol. Biophys.*, 24: 13-26.
- Prahalathan, P., S. Kumar and B. Raja, 2012. Morin attenuates blood pressure and oxidative stress in deoxycorticosterone acetate-salt hypertensive rats: A biochemical and histopathological evaluation. *Metabolism.*, 61: 1087-1099.
- Rajasekaran, S., K. Sivagnanam and S. Subramanian, 2005. Antioxidant effect of *Aloe vera* gel extract in streptozotocin-induced diabetes in rats. *Pharmacol. Rep.*, 57: 90-96.
- Schacterle, G.R. and R.L. Pollack, 1973. A simplified method for the quantitative assay of small amounts of protein in biologic material. *Anal. Biochem.*, 51(2): 654-655.
- Sedlak, J. and R.H. Lindsay, 1968. Estimation of total, protein-bound and nonprotein sulfhydryl groups in tissue with Ellman's reagent. *Anal. Biochem.*, 25(1): 192-205.
- Shaw, J.E., R.A. Sicree and P.Z. Zimmet, 2010. Global estimates of the prevalence of diabetes for 2010 and 2030. *Diabetes. Res. Clin. Pract.*, 87: 4-14.
- Sreedharan, V., K.K. Venkatachalam and N. Namasivayam, 2009. Effect of morin on tissue lipid peroxidation and antioxidant status in 1, 2-dimethylhydrazine induced experimental colon carcinogenesis. *Invest. New. Drugs.*, 27: 21-30.
- Subash, S. and P. Subramanian, 2009. Morin a flavonoid exerts antioxidant potential in chronic hyperammonemic rats: A biochemical and histopathological study. *Mol. Cell. Biochem.*, 327: 153-161.
- Vincent, A.M., J.W. Russell, P. Low and E.L. Feldman, 2004. Oxidative stress in the pathogenesis of diabetic neuropathy. *Endocr. Rev.*, 25: 612-628.
- Vishnukumar, S., S.R. Stephan and S. Chandra, 2012. Antidiabetic and antihyperlipidemic effect of morin on lipids and lipoproteins in streptozotocin-induced diabetic rats. *Int. J. Pharm. Bio. Sci.*, 3: 577-585.
- Wu, T.W., L.H. Zeng, J. Wu and K.P. Fung, 1994. Morin: A wood pigment that protects three types of human cells in the cardiovascular system against oxyradical damage. *Biochem. Pharmacol.*, 47: 1099-1103.
- Yu, T., J.L. Robotham and Y. Yoon, 2006. Increased production of reactive oxygen species in hyperglycemic conditions requires dynamic change of mitochondrial morphology. *Proc. Natl. Acad. Sci.*, 103: 2653-2658.
- Yugarani, T., B.K. Tan, M. Teh and N.P. Das, 1992. Effects of polyphenolic natural products on the lipid profiles of rats fed high fat diets. *Lipids.*, 27: 181-186.
- Zafar, M. and S.N.H. Naqvi, 2010. Effects of STZ-Induced diabetes on the relative weights of kidney, liver and pancreas in albino rats: A comparative study. *Int. J. Morphol.*, 28(1): 135-142.
- Zhang, R., K.A. Kang, M.J. Piao, Y.H. Maeng, K.H. Lee, W.Y. Chang, H.J. You, J.S. Kim, S.S. Kang and J.W. Hyun, 2009. Cellular protection of morin against the oxidative stress induced by hydrogen peroxide. *Chem. Biol. Interact.*, 177: 21-27.