

## Research Article

### Effect of Thymoquinone and Omega-3 on Intestinal Ischemia/Reperfusion Induced Hepatic Dysfunction in Rats

<sup>1</sup>S.A. Kenawy, <sup>1</sup>M.E. El-Sayed, <sup>2</sup>A.S. Awad, <sup>3</sup>A.M. Fayez and <sup>3</sup>M.M. El-Naa

<sup>1</sup>Department of Pharmacology and Toxicology, Cairo University, Egypt

<sup>2</sup>Department of Pharmacology and Toxicology, Ahram Canadian University, Cairo, Egypt

<sup>3</sup>Department of Pharmacology and Toxicology, MSA University, Giza, Egypt

**Abstract:** Intestinal Ischemia-Reperfusion (I/R) is a complex phenomenon causing local and remote tissue destruction and multiple-organ dysfunction. The present study investigates the effect of thymoquinone and omega-3 on intestinal I/R-induced hepatic dysfunction. Sixty four Wistar albino rats were randomly allocated into four experimental groups: sham control, intestinal I/R control, thymoquinone (10 mg/kg) and omega-3 (300 mg/kg) pre-treated groups respectively. Intestinal I/R model were established by clamping the superior mesenteric artery for 30 min followed by 60 min reperfusion. Serum levels of aspartate Amino Transferase (AST), Alanine Aminotransferase (ALT) and Alkaline Phosphatase (ALP) were measured. Hepatic tissue contents of Malondialdehyde (MDA), reduced Glutathione (GSH), Myeloperoxidase (MPO) and Tumor Necrosis Factor alpha (TNF- $\alpha$ ) and Superoxide Dismutase (SOD) activity were measured. Apoptosis in hepatic tissue cells was determined by immunities to chemical analysis of caspase-3. Hepatic histopathological examination was carried out. Intestinal I/R elevated serum AST, ALT and ALP levels. In-addition, hepatic tissue SOD activity and GSH content were decreased, while MDA, MPO and TNF- $\alpha$  contents were increased. Pre-treatment with thymoquinone or omega-3 corrected the histopathological changes and serum AST, ALT, ALP levels as well as hepatic tissue activity of SOD and GSH contents. In-addition, hepatic tissue contents of MDA and MPO were decreased. Furthermore, immunohistochemical examination showed remarkable activation of caspase-3 activity in hepatic tissue after intestinal I/R, which were corrected by thymoquinone or omega-3 pre-treatment. The protective potential of thymoquinone and omega-3 on hepatic dysfunction could be attributed to the known antioxidant, antiapoptotic and anti-inflammatory effects of test drugs.

**Keywords:** Antiapoptotic, anti-inflammatory, antioxidant, intestinal ischemia/reperfusion, MPO, omega-3, thymoquinone

## INTRODUCTION

Ischemia and Reperfusion (I/R) is a pathological condition characterized by an initial restriction of blood supply to an organ followed by the subsequent restoration of perfusion and concomitant re-oxygenation (Yellon and Hausenloy, 2007). The absence of oxygen and nutrients from blood during the ischemic period and reperfusion results in inflammation and oxidative damage through the induction of oxidative stress. Surprisingly, restoration of blood flow and re-oxygenation is frequently associated with tissue injury and a profound inflammatory response called reperfusion injury (Takizawa *et al.*, 2011).

Intestinal I/R leads to systemic inflammation and multiple organ failure in clinical and laboratory settings (Santora *et al.*, 2010). Multiple organ dysfunction syndrome is mediated by complex mechanisms in which interactions between activated leukocytes and

endothelial cells play a central role (Olanders *et al.*, 2002).

I/R injury also including production of Reactive Oxygen Species (ROS), inflammatory cell infiltration and cytokine production (Paterno and Longo, 2008). Increased oxidative stress and inhibition of cellular antioxidant defence mechanisms are associated with apoptotic cell death (Hayes and McLellan, 1999). Malondialdehyde (MDA) is one of the final products of lipid peroxidation. MDA can be found in both tissue and blood and its concentration is directly proportional to the cell damage caused by free radicals (Halliwell and Gutteridge, 1990). Antioxidant enzymes, including reduced Glutathione (GSH) and Superoxide Dismutase (SOD), protect tissues from reperfusion injury by destroying ROS (Deshmukh *et al.*, 1997).

One of the main orchestrators of I/R injury is the proinflammatory cytokine Tumor Necrosis Factor (TNF- $\alpha$ ) (Pascher and Klupp, 2005). TNF- $\alpha$  promotes leukocyte infiltration, induces cell death and activates

an inflammatory cascade that results in further production of cytokines and chemokines (Ciesielski and Modzelewski, 1995; Esposito *et al.*, 2007).

Pharmacologic modulation of TNF- $\alpha$  production is a promising strategy in the prevention of I/R injury (Camara-Lemarroy *et al.*, 2010). I/R activate various programs of cell death, which can be categorized as necrosis, apoptosis or autophagy-associated cell death.

Apoptosis induced by I/R involves an orchestrated caspase signaling cascade that induces a self-contained program of cell death, characterized by the shrinkage of the cell and its nucleus (Hotchkiss *et al.*, 2009).

Thymoquinone (TQ), a component of *Nigella sativa* is known to have broad anti-inflammatory activities and attenuates allergic inflammation. TQ attenuates the pro-inflammatory response mainly by modulating nuclear transactivation of NF- $\kappa$ B and TNF- $\alpha$  production (El Gazzar *et al.*, 2007).

Omega-3 fatty acid is one of the major constituents of fish oil. It has been shown that omega-3 has beneficial effects in multiple disease states that involve an inflammatory process. The effects of omega-3 were reported to be through modulation of inflammatory mediators such as TNF- $\alpha$  as well as inhibition of apoptotic marker; caspase-3 (El-Ansary *et al.*, 2011a). The present study is constructed in order to explore the effects of TQ or omega-3 on liver dysfunction induced by intestinal I/R in rats.

## MATERIALS AND METHODS

**Animals:** Adult male Wistar albino rats, weighing 150-180 g. Animals purchased from the National Institute of Ophthalmology, Cairo, Egypt. Animals were kept in the animal center under appropriate conditions of temperature, humidity and light. The study was carried out according to the approval of ethics committee for animal experimentation at faculty of pharmacy, Cairo University. Animals were fed standard pellet chow (El-Nasr Chemical Co., Cairo, Egypt) and were allowed water *ad libitum*.

**Drugs:** Thymoquinone (Sigma-Aldrich Co, USA) and Omega-3 (Metagenics, INC., Norway), were used in this study.

**Experimental design:** Rats were randomly allocated into 4 groups (16 rats each) as follows:

**Group 1:** Rats exposed to sham operation and served as sham control.

**Group 2:** Rats received distilled water orally for 14 days and then exposed to intestinal I/R operation and served as I/R control.

**Group 3:** Rats received thymoquinone (10 mg/kg) orally (Fouda *et al.*, 2008; Padhye *et al.*, 2008) for 14 days and then exposed to intestinal I/R operation.

**Group 4:** Rats received omega-3 (300 mg/kg) orally (Kavakli *et al.*, 2007) for 14 days and then exposed to intestinal I/R operation and served as reference standard.

**Induction of intestinal I/R:** I/R rat model was established according to the method described by (Cheng *et al.*, 2013). Clamping superior mesenteric artery for 30 min followed by reperfusion for 60 min. At the end of the experiment, blood samples were collected via the retro-orbital plexus under light anaesthesia (di-ethyl ether), serum was separated, for biochemical parameters. Animals were sacrificed by cervical dislocation, liver was rapidly isolated and washed with ice cold saline. Part of the liver was homogenized in phosphate buffer saline. The other part of the liver were embedded in 10% formalin for histopathological examination and immunohistochemical staining.

**Biochemical assay:** The serum levels of Aspartate Aminotransferase (AST), Alanine Aminotransferase (ALT) and Alkaline Phosphatase (ALP) were measured using kits supplied by Biodiagnostic, Egypt.

MDA and GSH content as well as SOD activity in hepatic tissue were determined spectrophotometrically using commercial kits supplied by Biodiagnostic, Egypt.

Hepatic tissue content of TNF- $\alpha$  and Myeloperoxidase (MPO) were measured by ELISA (AssayPro and Hycult Biotechnology, USA respectively).

**Histopathological examination:** Liver specimens were fixed in 10% formalin and embedded in paraffin. Tissue sections (4  $\mu$ m) were stained with Hematoxylin and Eosin (H&E). Immunohistochemistry for caspase-3 was performed in sections prepared from formalin-fixed, paraffin-embedded tissue using the avidin-biotin immunodetection complex method according to the manufacturer's instruction (Labvision, USA). Interpretation of results was done semiquantitatively by evaluating both intensity and distribution of positive cells. Hepatocyte cells showing cytoplasmic staining for caspase-3, The intensity of caspase-3 immunostaining was assessed as follows: none = 0, mild = 1, moderate = 2 and strong = 3. The immunohistochemical Histological score (H-score) was then calculated by multiplying the intensity by the percentage of liver cells showing positive staining for caspase-3, creating a range of possible scores of 0-300.

**Statistical analysis:** Results are expressed as means  $\pm$  Standard Error of Mean (S.E.M.). Comparisons between different groups were carried out by one-way Analysis of Variance (ANOVA) followed by the Tukey-Kramer test. The level of significance was set at  $p < 0.05$ . Graphpad software instat (version 2) was used to carry out statistical analysis.

## RESULTS

### Effect of TQ or omega-3 on ALT, AST and ALP:

Normal serum level of AST, ALT and ALP were 8.785, 18.75 U/mL and 53.142 IU/L, respectively. I/R resulted in significant increase to 84.125, 69.013 U/mL and 126.511 IU/L, respectively. Pre-treatment of TQ resulted in significant decrease to 17.750, 22.375 U/mL and 60.233 IU/L respectively, while treatment of omega-3 resulted in significant decrease to 28.375, 23.250 U/mL and 66.250 IU/L, respectively (Table 1).

### Effect of TQ or omega-3 on hepatic MDA, GSH and SOD:

Normal hepatic tissue content of MDA, GSH and SOD activity were 109.330 nmol/g, 457.221 mg/g.tissue and 93.147 U/mg.tissue, respectively. I/R resulted in significant increase of MDA content to 171.101 nmol/g.tissue and significant decrease of GSH content and SOD activity to 285.110 mg/g.tissue and 37.753 U/mg.tissue respectively. Pre-treatment of TQ or omega-3 significantly decreased MDA content to 114.207 and 111.233 nmol/g.tissue, significantly increased GSH content to 438.366 and 447.250 mg/g.tissue and increased SOD activity to 79.851 and 87.897 U/mg.tissue, respectively (Table 2).

Table 1: Effect of TQ or omega-3 on the serum level of AST, ALT and ALP in intestinal I/R rats

Groups	Parameters		
	AST unit/mL	ALT unit/mL	ALP IU/L
Sham control	8.785±1.086	18.750±1.750	53.142±2.539
I/R control	84.125 <sup>a</sup> ±7.691	69.013 <sup>a</sup> ±5.868	126.511 <sup>a</sup> ±6.582
Thymoquinone	17.750 <sup>b</sup> ±2.104	22.375 <sup>b</sup> ±2.203	60.233 <sup>b</sup> ±3.454
Omega-3	28.375 <sup>ab</sup> ±2.620	23.250 <sup>b</sup> ±2.624	66.250 <sup>b</sup> ±3.612

Thymoquinone (10 mg/kg; P.O.) or omega-3 (300 mg/kg; P.O.) was administered for 14 days before I/R; Data are presented as the mean±S.E.M.; a: Significantly different from sham control at p<0.05, b: Significantly different from I/R control at p<0.05; Statistical analysis was carried out by one way Analysis of Variance (ANOVA) followed by Tukey-kramer test

Table 2: Effect of TQ or omega-3 on hepatic MDA and GSH contents and SOD activity in intestinal I/R in rats

Groups	Parameters (hepatic)		
	MDA nmol/g.tissue	GSH mg/g.tissue	SOD U/mg.tissue
Sham control	109.330±8.750	457.221±19.711	93.147±8.250
I/R control	171.101 <sup>a</sup> ±15.751	285.110 <sup>a</sup> ±23.696	37.753 <sup>a</sup> ±3.110
Thymoquinone	114.207 <sup>b</sup> ±8.368	438.366 <sup>b</sup> ±33.854	79.851 <sup>b</sup> ±6.749
Omega-3	111.233 <sup>b</sup> ±10.258	447.250 <sup>b</sup> ±38.542	87.897 <sup>b</sup> ±8.102

Thymoquinone (10 mg/kg; P.O.) or omega-3 (300 mg/kg; P.O.) was administered for 14 days before I/R; Data are presented as the mean±S.E.M.; a: Significantly different from sham control at p<0.05; b: Significantly different from I/R control at p<0.05; Statistical analysis was carried out by one way Analysis of Variance (ANOVA) followed by Tukey-kramer test

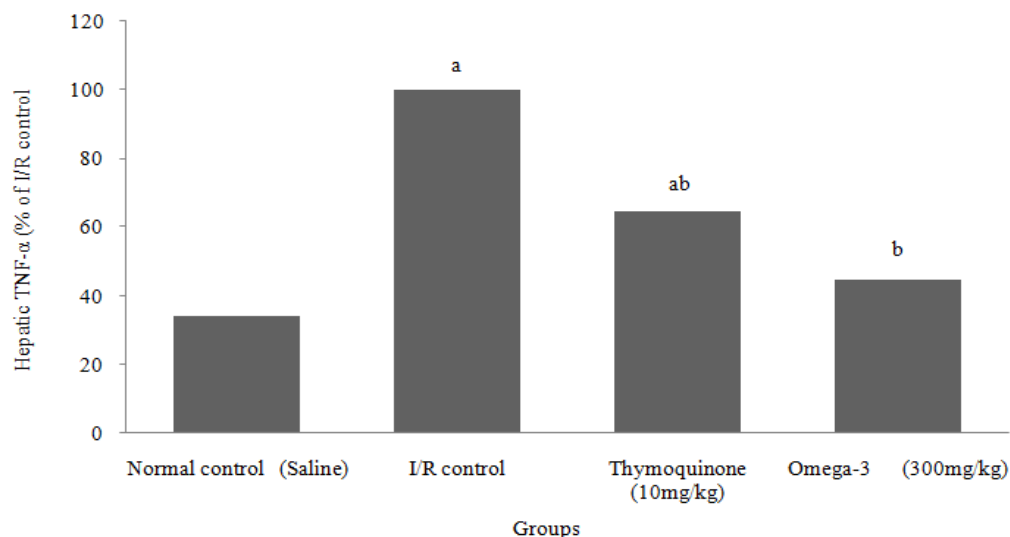


Fig. 1: Effect of TQ or omega-3 on hepatic content of TNF-α in intestinal I/R in rats

Thymoquinone (10 mg/kg; P.O.) as well as omega-3 (300 mg/kg; P.O.) was administered for 14 days before I/R; a: significantly different from normal control at p<0.05; b: Significantly different from I/R control at p<0.05; Statistical analysis was carried out by one way Analysis of Variance (ANOVA) followed by Tukey-kramer test for multiple comparisons

**Effect of TQ or omega-3 on hepatic TNF- $\alpha$ :** The normal value of hepatic tissue content of TNF- $\alpha$  was 72.380 pg/mg.tissue I/R resulted in significant increase to 211.649 pg/mg.tissue. Pre-treatment with TQ or omega-3 before I/R resulted in significant decrease to (64.626%) and (44.867%) respectively of I/R control value (Fig. 1).

**Effect of TQ or omega-3 on hepatic MPO:** The normal value of hepatic tissue content of MPO was 33.200 U/mg.tissue. I/R resulted in significant increase to 87.250 U/mg.tissue. Pre-treatment with TQ or omega-3 before I/R resulted in significant decrease to (68.401%) and (52.149%), respectively of I/R control value (Fig. 2).

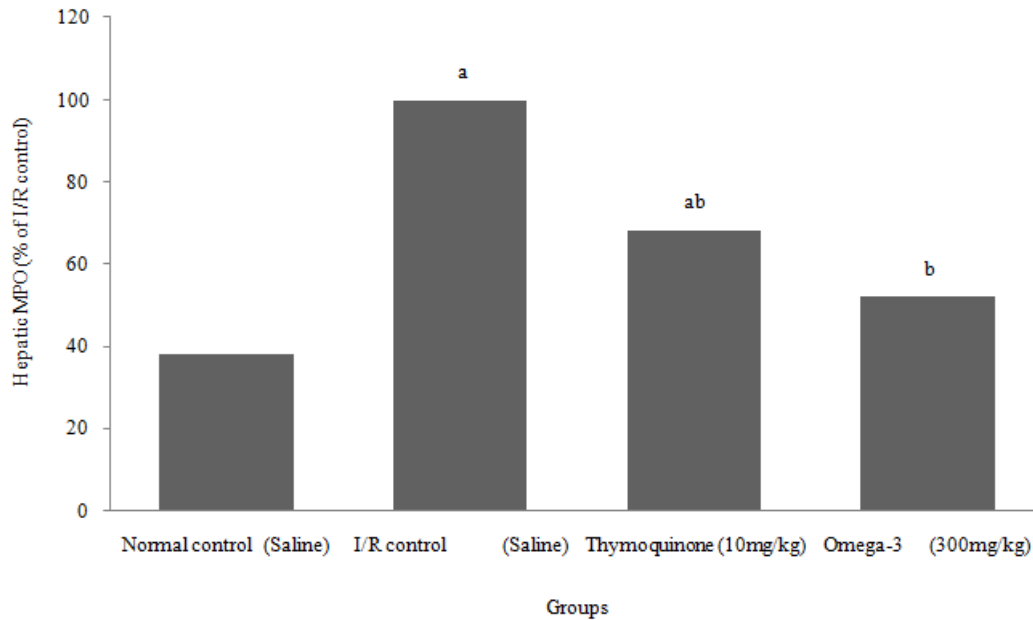


Fig. 2: Effect of TQ or omega-3 on hepatic content of MPO in intestinal I/R in rats Thymoquinone (10 mg/kg; P.O.) as well as omega-3 (300 mg/kg; P.O.) was administered for 14 days before I/R; a: Significantly different from normal control at  $p < 0.05$ ; b: Significantly different from I/R control at  $p < 0.05$ ; Statistical analysis was carried out by one way Analysis of Variance (ANOVA) followed by Tukey-kramer test for multiple comparisons

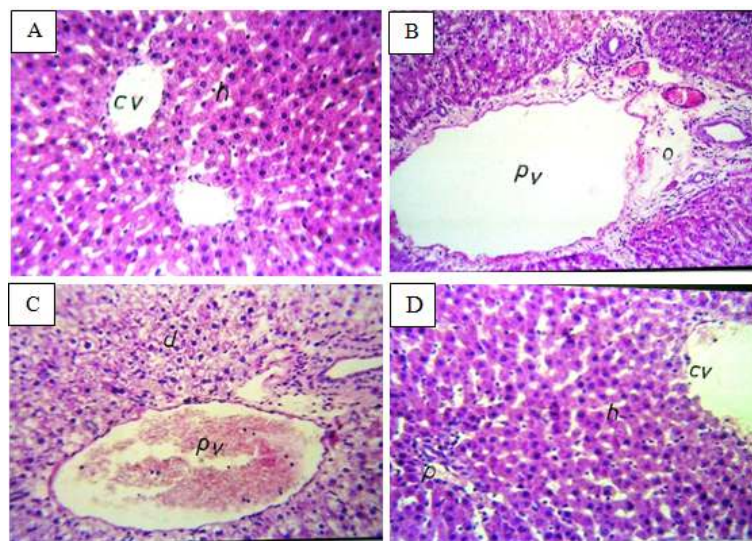


Fig. 3: Hepatic histological findings of sham control group showed normal hepatocytes (A) those from I/R control group (B) showed strong degeneration and congestion in the hepatocytes with dilatation in the portal vein. Those treated with thymoquinone (C) showed minor degeneration in hepatocytes and dilatation in the portal vein (pv); Those treated with omega-3 (D) showed normal hepatocytes and dilatation in the central vein




Fig. 4: Hepatic immunohistochemical staining of caspase-3 in sham control group was moderately positive in 30% of hepatocytes (E) those from I/R control group, caspase-3 was strongly positive in 40% of hepatocytes (F) those treated with thymoquinone caspase-3 was moderately positive in 40% of hepatocytes (G) those treated with omega-3 caspase-3 was moderately positive in 40% of hepatocytes (H)

**Effect of TQ or omega-3 on hepatic histopathological finding:** Rats subjected to I/R showed strong degeneration and congestion in the hepatocytes with dilatation in the portal vein. Rats treated with TQ showed minor degeneration in hepatocytes and dilatation in the portal vein. Rats treated with omega-3 showed normal hepatocytes and dilatation in the central vein (Fig. 3).

**Effect of TQ or omega-3 on hepatic immunohistochemical staining of caspase-3:** Immunohistochemical staining of caspase-3 in sham control group was moderately positive in 30% of hepatocytes (H-Score = 60). While it was strongly positive in 40% of hepatocytes (H-Score = 120) in rats subjected to I/R. Rats treated with TQ and omega-3 showed moderate staining of caspase-3 in 40% of hepatocytes (H-Score = 80; Fig. 4).

## DISCUSSION

Intestinal I/R is considered to be a grave and triggering event in development of local and distant organ dysfunction (Zhao *et al.*, 2010), which involves liver diseases (Sasaki and Joh, 2007).

In the present study; intestinal I/R-induced hepatic failure confirmed biochemically by increasing in the hepatic enzymes AST, ALT and ALP as a measure of hepatic function. The elevation of liver enzymes is accepted as the most sensitive indexes of acute hepatic injury (Zhang *et al.*, 2006). These results are in agreement with Li *et al.* (2008) and Sheth *et al.* (2011). Who reported that I/R significantly increased the

transaminase levels as compared with the sham operated group.

In support of our result histopathological examination showed strong degeneration and congestion in the hepatocytes in intestinal I/R rats which confirm the destructive effect of I/R on liver. The injury most likely due to the sudden reduction of the portal blood flow after the occlusion of the mesenteric artery followed by reperfusion, which increases the inflammation and oxidative damage in the liver. The significant reduction reported in the present study in the serum levels of AST, ALT and ALP of the thymoquinone and omega-3 treated groups confirm their cytoprotective effects of these drugs. Moreover thymoquinone showed a marked improve in the hepatocytes structure as well as omega-3 showed a normal histopathological result. This may be due to the direct protective effect of the drugs on the hepatocytes in addition to their anti-oxidant effect. TQ effect was in agreement with Daba and Abdel-Rahman (1998) who reported that TQ significantly protected isolated hepatocytes from tertbutylhydroperoxide induced toxicity and restores the levels of ALT and ALP. Omega-3 effect was in agreement with Meganathan *et al.* (2011) who reported that Omega-3-Fatty acids lowering AST, ALT and ALP levels, beside its anti-inflammatory effect due to decrease the production of pro-inflammatory cytokines.

In the present study, hepatic tissue content of TNF- $\alpha$  was significantly elevated in the intestinal I/R control group as compared to the sham-operated rats in agreement with Yang *et al.* (2001). Among the various cytokines, TNF- $\alpha$  has emerged as a key factor in assorted liver diseases (Hsu *et al.*, 2010).

Reperfusion of the ischemic intestine results in intestinal mucosal barrier impairment, leading to endotoxemia that triggers a deleterious cascade including the production of ROS and further activates the intestinal macrophages and Kupffer Cells (KCs) (Towfigh *et al.*, 2000). Activation of KCs, upregulates the production of inflammatory mediators including interleukin-1b, interleukin-6, tumor necrosis factor- $\alpha$  and platelet activating factor (Giakoustidis *et al.*, 2006).

In the current study, thymoquinone and omega-3 markedly decreased hepatic tissue content of TNF- $\alpha$ . This is in accordance with Tekeoglu *et al.* (2006) who reported the anti-inflammatory effects of TQ on experimentally-induced arthritis in rats is associated with decreased levels of TNF- $\alpha$ . Salem (2005) attributed this to its antioxidant and anti-inflammatory properties. Omega-3 effect was in agreement with Skuladottir *et al.* (2007) who refer the anti-inflammatory effect of omega-3 due to the significant reduction in the levels of IL-6 and TNF- $\alpha$ .

The obtained data revealed that intestinal I/R resulted in a marked decrease in hepatic tissue content of GSH and the activity of SOD along with increased tissue content of LPO and MPO. Zhao *et al.* (2010) reported that the activity of SOD in the liver tissue decreased after intestinal I/R and stated that hepatic tissue content of GSH significantly decreased in the intestinal I/R group. A growing body of evidence indicates that oxidative stress plays an important role in the pathogenesis of many clinical conditions (Cross *et al.*, 1987). These changes were significantly ameliorated by TQ and omega-3 concurrent treatment. Omega-3 administration could cause its beneficial effects by its known anti-inflammatory properties through displacement of arachidonic acid from the cellular membrane, shifting of prostaglandin E2 and leukotriene B4 production (Beyazit *et al.*, 2010).

A very valuable and more selective tool to identify apoptotic cells in solid tissues may be the use of antibodies that specifically detect the cleaved (active) subunits of caspases-3, because activation of these enzymes constitutes a key molecular event during the process of apoptosis. In fact, the utility of this approach has been proven in previous studies by other groups (Tanaka *et al.*, 2000; Gamonal *et al.*, 2001). The present data showed that caspase-3, in rat liver was strongly activated in 40% of hepatocytes after intestinal I/R, compared to moderate activation in 30% of hepatocytes in sham control rats. This result are in agreement with Giakoustidis *et al.* (2006) and El Gazzar *et al.* (2007), who supposed that activated caspase-3 was widely expressed in the I/R group, although a very limited amount was detected in the sham operation animals. This activation of caspase-3 may explain the hepatic injury caused after the intestinal I/R. Thymoquinone administration in this study reduced apoptosis through

decreasing the activation of caspase-3. This is in agreement with Fouada *et al.* (2008) who assumed that apoptosis and proliferative reactions are reduced by thymoquinone. On the other hand Xuan *et al.* (2010) believed that TQ is known to confer protection against tumor growth due to stimulation of tumor cell apoptosis. Administration of omega-3 in the present study also reduced caspase-3. This is in agreement with El-Ansary *et al.* (2011b). This reduction in caspase-3 may be attributed to the powerful antioxidant effect of omega-3.

As a quinone, TQ can be reduced by a variety of reductases to yield semiquinone (one reduction) or thymohydroquinone (two reductions). While the latter molecule is reported to have antioxidant effects (El-Najjar *et al.*, 2010). TQ has potent superoxide anion scavenging abilities and inhibits iron-dependent microsomal lipid peroxidation (Badary *et al.*, 2003). While the effect of omega-3 may be due to their anti-inflammatory effect (Beltz *et al.*, 2007). The mechanisms include that omega-3 fatty acids decrease the production of pro-inflammatory cytokines, such as TNF- $\alpha$  (Song *et al.*, 2009).

## CONCLUSION

In conclusion, TQ and omega 3 have potential antifibrotic effect beside its anti-inflammatory and antioxidant activity via the protection of hepatic dysfunction induced by intestinal ischemia reperfusion.

## REFERENCES

- Badary, O.A., R.A. Taha, A.M. Gamal el-Din and M.H. Abdel-Wahab, 2003. Thymoquinone is a potent superoxide anion scavenger. *Drug Chem. Toxicol.*, 26: 87-98.
- Beltz, B.S., M.F. Tlusty, J.L. Benton and D.C. Sandeman, 2007. Omega-3 fatty acids upregulate adult neurogenesis. *Neurosci. Lett.*, 415: 154-158.
- Beyazit, Y., T. Purnak and M. Kekilli 2010. Role of nitric oxide in the treatment of non-alcoholic fatty liver by omega-3 fatty acids. *Aliment. Pharm. Ther.*, 32: 303-304.
- Camara-Lemarroy, C.R., F.J. Guzman-de la Garza, G. Alarcon-Galvan, P. Cordero-Perez, L.E. Munoz-Espinosa and N.E. Fernandez-Garza 2010. Effects of thalidomide and pentoxifylline over local and remote organ injury after intestinal ischemia/reperfusion. *Transplant P.*, 42(5): 1624-1626.
- Cheng, C.H., H.C. Lin, I.R. Lai and H.S. Lai, 2013. Ischemic postconditioning attenuate reperfusion injury of small intestine: Impact of mitochondrial permeability transition. *Transplantation*, 95: 559-565.



- Ciesielski, L. and B. Modzelewski, 1995. Pathogenesis and treatment of multiorgan failure dysfunction syndrome in shock. *Rocz Akad. Med. Bialymst.*, 40: 13-24.
- Cross, C.E., B. Halliwell, E.T. Borish, W.A. Pryor, B.N. Ames, R.L. Saul, J.M. McCord and D. Harman, 1987. Oxygen radicals and human disease. *Ann. Intern. Med.*, 107(4): 526-545.
- Daba, M.H. and M.S. Abdel-Rahman 1998. Hepatoprotective activity of thymoquinone in isolated rat hepatocytes. *Toxicol. Lett.*, 95: 23-29.
- Deshmukh, D.R., O. Mirochnitchenko, V.S. Ghole, D. Agnese, P.C. Shah, M. Reddell, R.E. Brolin and M. Inouye, 1997. Intestinal ischemia and reperfusion injury in transgenic mice overexpressing copper-zinc superoxide dismutase. *Am. J. Physiol.*, 273: C1130-C1135.
- El-Ansary, A.K., S.K. Al-Daihan and A.R. El-Gezeery, 2011a. On the protective effect of omega-3 against propionic acid-induced neurotoxicity in rat pups. *Lipids Health Dis.*, 10: 142-151.
- El-Ansary, A.K., A.G. Bacha and L.Y. Al-Ayahdi, 2011b. Impaired plasma phospholipids and relative amounts of essential polyunsaturated fatty acids in autistic patients from Saudi Arabia. *Lipids Health Dis.*, 10: 63.
- El Gazzar, M.A., R. El Mezayen, M.R. Nicolls and S.C. Dreskin, 2007. Thymoquinone attenuates proinflammatory responses in lipopolysaccharide-activated mast cells by modulating NF-kappaB nuclear transactivation. *Biochim. Biophys. Acta*, 1770: 556-564.
- El-Najjar, N., M. Chatila, H. Moukadem, H. Vuorela, M. Ocker, M. Gandesiri, R. Schneider-Stock and H. Gali-Muhtasib, 2010. Reactive oxygen species mediate thymoquinone-induced apoptosis and activate ERK and JNK signaling. *Apoptosis*, 15(2): 183-195.
- Esposito, E., E. Mazzone, C. Muia, R. Meli, E. Sessa and S. Cuzzocrea, 2007. Splanchnic ischemia and reperfusion injury is reduced by genetic or pharmacological inhibition of TNF-alpha. *J. Leukocyte Biol.*, 81: 1032-1043.
- Fouda, A.M., M.H. Daba, G.M. Dahab and O.A. Sharaf El-Din, 2008. Thymoquinone ameliorates renal oxidative damage and proliferative response induced by mercuric chloride in rats. *Basic Clin. Pharmacol.*, 103: 109-118.
- Gamonal, J., A. Bascones, A. Acevedo, E. Blanco and A. Silva 2001. Apoptosis in chronic adult periodontitis analyzed by in situ DNA breaks, electron microscopy and immunohistochemistry. *J. Periodontol.*, 72: 517-525.
- Giakoustidis, A.E., D.E. Giakoustidis, S. Iliadis, G. Papageorgiou, K. Koliakou, N. Kontos *et al.*, 2006. Attenuation of intestinal ischemia/reperfusion induced liver and lung injury by intraperitoneal administration of (-)-epigallocatechin-3-gallate. *Free Radical Res.*, 40: 103-110.
- Hayes, J.D. and L.I. McLellan, 1999. Glutathione and glutathione-dependent enzymes represent a coordinately regulated defence against oxidative stress. *Free Radical Res.*, 31: 273-300.
- Hotchkiss, R.S., A. Strasser, J.E. McDunn and P.E. Swanson, 2009. Cell death. *New Engl. J. Med.*, 361: 1570-1583.
- Hsu, C.Y., F.Y. Lee, T.I. Huo, C.Y. Chan, H.C. Huang, H.C. Lin *et al.*, 2010. Lack of therapeutic effects of gabexate mesilate on the hepatic encephalopathy in rats with acute and chronic hepatic failure. *J. Gastroen. Hepatol.*, 25: 1321-1328.
- Kavakli, A., E. Kose, I. Kus, I. Zararsiz, N. Akpolat and M. Sarsilmaz, 2007. Protective effect of omega-3 fatty acids in a rat focal cerebral ischemia-reperfusion model. *Neurosciences (Riyadh)*, 12: 198-201.
- Li, J.Y., H.Z. Yin, X. Gu, Y. Zhou, W.H. Zhang and Y.M. Qin, 2008. Melatonin protects liver from intestine ischemia reperfusion injury in rats. *World J. Gastroenterol.*, 14: 7392-7396.
- Meganathan, M., K.M. Gopal, P. Sasikala, J. Mohan, N. Gowdhaman, K. Balamurugan *et al.*, 2011. Evaluation of hepatoprotective effect of omega 3-fatty acid against paracetamol induced liver injury in albino rats. *Global J. Pharmacol.*, 5: 50-53.
- Olanders, K., Z. Sun, A. Borjesson, M. Dib, E. Andersson, A. Lasso *et al.*, 2002. The effect of intestinal ischemia and reperfusion injury on ICAM-1 expression, endothelial barrier function, neutrophil tissue influx and protease inhibitor levels in rats. *Shock*, 18(1): 86-92.
- Padhye, S., S. Banerjee, A. Ahmad, R. Mohammad and F.H. Sarkar 2008. From here to eternity-the secret of Pharaohs: Therapeutic potential of black cumin seeds and beyond. *Cancer Ther.*, 6: 495-510.
- Pascher, A. and J. Klupp, 2005. Biologics in the treatment of transplant rejection and ischemia/reperfusion injury: New applications for TNFalpha inhibitors? *BioDrugs*, 19: 211-231.
- Paterno, F. and W.E. Longo, 2008. The etiology and pathogenesis of vascular disorders of the intestine. *Radiol. Clin. N. Am.*, 46: 877-885.
- Salem, M.L., 2005. Immunomodulatory and therapeutic properties of the *Nigella sativa* L. seed. *Int. Immunopharmacol.*, 5: 1749-1770.
- Santora, R.J., M.L. Lie, D.N. Grigoryev, O. Nasir, F.A. Moore and H.T. Hassoun, 2010. Therapeutic distant organ effects of regional hypothermia during mesenteric ischemia-reperfusion injury. *J. Vasc. Surg.*, 52: 1003-1014.
- Sasaki, M. and T. Joh, 2007. Oxidative stress and ischemia-reperfusion injury in gastrointestinal tract and antioxidant, protective agents. *J. Clin. Biochem. Nutr.*, 40: 1-12.

- Sheth, H., T. Hafez, G.K. Glantzounis, A.M. Seifalian, B. Fuller and B.R. Davidson, 2011. Glycine maintains mitochondrial activity and bile composition following warm liver ischemia-reperfusion injury. *J. Gastroen. Hepatol.*, 26: 194-200.
- Skuladottir, I.H., D.H. Petursdottir and I. Hardardottir, 2007. The effects of omega-3 polyunsaturated fatty acids on TNF- $\alpha$  and IL-10 secretion by murine peritoneal cells in vitro. *Lipids*, 42: 699-706.
- Song, C., X.Y. Zhang and M. Manku, 2009. Increased phospholipase A2 activity and inflammatory response but decreased nerve growth factor expression in the olfactory bulbectomized rat model of depression: Effects of chronic ethyl-eicosapentaenoate treatment. *J. Neurosci.*, 29: 14-22.
- Takizawa, Y., T. Kitazato, H. Kishimoto, M. Tomita and M. Hayashi, 2011. Effects of antioxidants on drug absorption in in vivo intestinal ischemia/reperfusion. *Eur. J. Drug. Metab. Ph.*, 35: 89-95.
- Tanaka, M., T. Miyazaki, S. Tanigaki, K. Kasai, K. Minegishi, K. Miyakoshi *et al.*, 2000. Participation of reactive oxygen species in PGF2 $\alpha$ -induced apoptosis in rat luteal cells. *J. Reprod. Fertil*, 120: 239-245.
- Tekeoglu, I., A. Dogan and L. Demiralp, 2006. Effects of thymoquinone (volatile oil of black cummin) on rheumatoid arthritis in rat models. *Phytother. Res.*, 20: 869-871.
- Towfigh, S., T. Heisler, D.A. Rigberg, O.J. Hines, J. Chu, D.W. McFadden *et al.*, 2000. Intestinal ischemia and the gut-liver axis: An in vitro model. *J. Surg. Res.*, 88: 160-164.
- Xuan, N.T., E. Shumilina, S.M. Qadri, F. Götz and F. Lang, 2010. Effect of thymoquinone on mouse dendritic cells. *Cell. Physiol. Biochem.*, 25(2-3): 307-314.
- Yang, Z.J., G. Bosco, A. Montante, X.I. Ou and E.M. Camporesi 2001. Hyperbaric O2 reduces intestinal ischemia-reperfusion-induced TNF- $\alpha$  production and lung neutrophil sequestration. *Eur. J. Appl. Physiol.*, 85: 96-103.
- Yellon, D.M. and D.J. Hausenloy, 2007. Myocardial reperfusion injury. *New Engl. J. Med.*, 357: 1121-1135.
- Zhang, W.H., J.Y. Li and Y. Zhou, 2006. Melatonin abates liver ischemia/reperfusion injury by improving the balance between nitric oxide and endothelin. *Hepatob. Pancreat. Dis.*, 5: 574-579.
- Zhao, H.D., F. Zhang, G. Shen, Y.B. Li, Y.H. Li, H.R. Jing *et al.*, 2010. Sulforaphane protects liver injury induced by intestinal ischemia reperfusion through Nrf2-ARE pathway. *World J. Gastroentero.*, 16: 3002-3010.