

## Research Article

### **Steroid Histochemical Study of the Testes of Adult Sudanese Chicken (*Gallus domesticus*) and Duck (*Anas platyrhynchos*)**

Salwa Ismail Abdelgader Elbajory

Faculty of Medical Laboratory Science, Omdurman Islamic University, Sudan

**Abstract:** In Sudan (Khartoum state), the material was collected during the winter and summer seasons. The aim of the study to show the steroid histochemical of the testis of adult Sudanese chicken (*Gallus domesticus*) and duck (*Anas platyrhynchos*). The adult chicken and duck testes were two bean-shaped, large and soft, the left testes was usually higher in position and larger in size than the right one. The histochemical localization of steroid enzymes was studied in the testis of adult chicken and duck.  $\Delta^5$ - $3\beta$  hydroxysteroid dehydrogenase and  $17\beta$ -hydroxysteroid dehydrogenase were demonstrated solely in the interstitial tissue and the seminiferous tubules and no qualitative difference was noticed between winter and summer material.

**Keywords:** Adult Sudanese, *Anas platyrhynchos*, chicken, duck, *Gallus domesticus*, steroid histochemical, testes

## INTRODUCTION

The aim of the study to show the steroid histochemical of the testes of adult Sudanese chicken (*Gallus domesticus*) and duck (*Anas platyrhynchos*). Great attention has been given to the study of the steroid histochemistry of testis from several species. The localization of a number of steroid enzymes was undertaken by Baillie and Griffiths (1964), Narbaitz and Kolodny (1964), Baillie *et al.* (1966), Hay and Deane (1966), Bara (1972, 1979), Tingari (1973), Bhagyashria and Nadkarri (1982), Schreiber *et al.* (1982) and Tetzlaff (1987).  $\Delta^5$ - $3\beta$  hydroxysteroid dehydrogenase and  $17\beta$ -hydroxysteroid dehydrogenase have been localized histochemically in the testis of the fowl embryo (Chieffi *et al.*, 1964). Search in the literature has shown no steroid histochemical data on testes of any of the avian species in Sudan.

## MATERIALS AND METHODS

In Sudan (Khartoum state), the material was collected during the winter and summer seasons from twelve mature male Hisex brown chickens and twelve mature male ducks. The birds were killed by dislocation of the neck vertebrae and samples of tissues were obtained from the testis were immediately fresh-frozen in liquid nitrogen and cut at a thickness of 16  $\mu$ m in a cryostat maintained at  $-20^\circ\text{C}$ . Sections were attached to

cover slips, allowed to dry by momentary thawing, covered with the incubating medium and transferred to a moist chamber at  $37^\circ\text{C}$  for 1 to 2 h.

The incubating medium was essentially the same as that obtained by Baillie *et al.* (1966).  $\text{NAD}^+$  was used as co-factor and nitro BT as the electron acceptor.  $3\beta$ -hydroxyandrost-5-en-17-one (DHA) and  $3\beta$ -hydroxypregn-5-en-20-one (pregnenolone) were used as substrate for detecting  $\Delta^5$ -hydroxysteroid dehydrogenase. Control sections were incubated in the medium lacking the substrate.

Following incubation, the sections were washed in buffer, rinsed in water, fixed for 10 min in 10% formalin, thoroughly washed and mounted in glycerine jelly.

## RESULTS

**Gross feature of the adrenal gland of adult chicken and duck:** The testes were two bean-shaped, large, white and soft with a rich vascular supply, lying ventral to the anterior lobes of the kidney. The mean weight of the left and right testes were 11.92 gm and 11.24 gm in chicken respectively and 9.60 gm and 8.88 gm in duck respectively. The long axis were parallel to each other. The left testes was usually higher in position and larger in size than the right one. The medial border of each testis was slightly concave (Fig. 1 and 2).

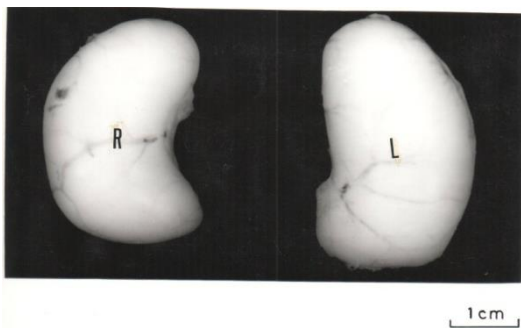


Fig. 1: The testis of the domestic fowl. R, right testis. L, left testis

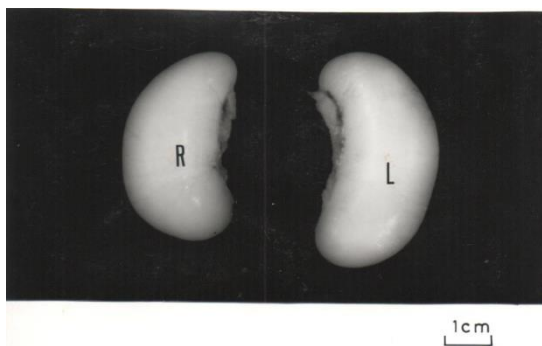

Fig. 2: The testis of the duck. R, right testis. L, left testis

Table 1: Summary of material investigated histochemically in the testis of adult Hisex brown chickens (summer and winter seasons)

Tissue	DHA	Pregnenolone	Testosterone
Interstitial tissue	+++	+++	+++
Seminiferous tubules	++	++	++

+++ = strong; ++ = moderate

**Steroid histochemical observations of the testis of adult chicken:**

The result of all material investigated were summarized in Table 1. The observations included the interstitial tissue and the seminiferous tubules. The staining reaction obtained was essentially the same for both summer and winter material utilized. All control sections showed a very weak staining reaction. This is assumed to be due the NAD<sup>+</sup>-dependent dehydrogenases oxidizing endogenous substrate still present in tissue section (Hay and Deane, 1966).

**$\Delta^5$ - $3\beta$  hydroxysteroid dehydrogenase:** Both DHA and pregnenolone gave the same pattern of distribution of the reaction when used as substrates. Positive formazan granules were seen in the basal part of the germinal epithelium of the seminiferous tubules. It was not possible to determine with certainty whether the activity was in sertoli cells, the germ cells or both. A positive reaction in the form of scattered granules was seen in the leyding cells and in the interstitial tissues (Fig. 3 and 4).

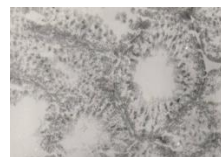

Fig. 3:  $\Delta^5$ - $3\beta$  hydroxysteroid dehydrogenase in fowl testis. Substrate DHA. Incubated with NAD<sup>+</sup>. X 100

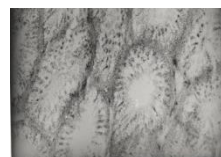


Fig. 4:  $\Delta^5$ - $3\beta$  hydroxysteroid dehydrogenase in fowl testis. Substrate pregnenolone. Incubated with NAD<sup>+</sup>. X 100

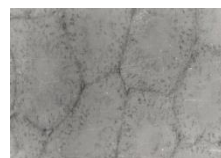

Fig. 5:  $17\beta$ -hydroxysteroid dehydrogenase in fowl testis. Substrate testosterone. Incubated with NAD<sup>+</sup>. X 100

Table 2: Summary of material investigated histochemically in the testis of adult duck (summer and winter seasons)

Tissue	DHA	Pregnenolone	Testosterone
Interstitial tissue	+++	+++	+++
Seminiferous tubules	++	++	++

+++ = strong; ++ = moderate

**$17\beta$ -hydroxysteroid dehydrogenase:** Testosterone gave the same pattern of distribution of the reaction as revealed by DHA and pregnenolone when used as substrates. Positive granules were seen in the basal part of the germinal epithelium of the seminiferous tubules. As indicated above, it was difficult to determine whether the activity was in the sertoli cells, the germ cells or both. A positive reaction of scattered granules was depicted in the leyding cells and interstitial tissue (Fig. 5).

**Steroid histochemical observations of the testis of adult duck:**

The summarization in Table 2 included the result of all material investigated during both winter and summer. A positive reaction was obtained in the interstitial tissue and as well as seminiferous tubules. All control sections showed a very weak staining reaction as explained above.

**$\Delta^5$ - $3\beta$  hydroxysteroid dehydrogenase:** The same pattern of distribution of the distribution of the reaction was given by using both DHA and pregnenolone as substrates. In the basal part of the germinal epithelium of the seminiferous tubules, positive formazan granules were seen. In the leyding cells and the interstitial tissue

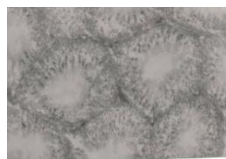

Fig. 6:  $\Delta^5$ -3 $\beta$  hydroxysteroid dehydrogenase in duck. Substrate DHA. Incubated with NAD<sup>+</sup>. X 100

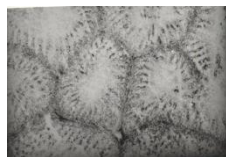

Fig. 7:  $\Delta^5$ -3 $\beta$  hydroxysteroid dehydrogenase in duck. Substrate pregnenolone. Incubated with NAD<sup>+</sup>. X 100




Fig. 8: 17 $\beta$ -hydroxysteroid dehydrogenase in fowl duck. Substrate testosterone. Incubated with NAD<sup>+</sup>. X 100

a positive reaction in the form of scattered granules was seen (Fig. 6 and 7).

**17 $\beta$ -hydroxysteroid dehydrogenase:** Testosterone gave the same pattern of distribution of the reaction as revealed by DHA and pregnenolone and similar to what has been obtained in chicken testis (Fig. 8).

## DISCUSSION

The activity of  $\Delta^5$ -3 $\beta$  hydroxysteroid dehydrogenase has been reported in leydig cells of mice (Naillie and Griffiths, 1964), ferrets (Galil and Deane, 1966), man (Baillie and Mack, 1966), horse, bulls and rams (Hay and Deane, 1966), guinea-pig (Bara, 1979), platyfish (Schreibman *et al.*, 1982) and Pekin drake (Tetzlaff, 1987). Maier (1965) reported that this enzyme was present in the testes of rats, cats, bats, mice, hamster, guinea-pigs, rabbits and dogs, but not in man and monkey. In the mouse testis, the activity of this enzyme was demonstrated in the connective tissue surrounding the rete testes (Baillie, 1961). In the fowl testis, the enzyme was detectable in the interstitial tissue and the seminiferous tubules, but it was found difficult to judge whether the reaction was in the sustentacular cells of sertoli, in the germ cells or in both (Tingari, 1973). Such finding are supported by the present observation on both chicken and duck testes and in which  $\Delta^5$ -3 $\beta$  hydroxysteroid dehydrogenase was localized in the interstitial tissue and seminiferous tubules of summer and winter material with the same

pattern of distribution. Since such results are essentially qualitative and based on visual observation, it would be difficult to ascertain if they represent the same grade of enzyme activity during summer and winter seasons. Accordingly a more precise quantitative work would be required before any definite conclusion could be drawn.

17 $\beta$ -hydroxysteroid dehydrogenase, on the other hand, was localized in interstitial cells and seminiferous tubules of chicken and duck in the summer and winter seasons with the same pattern of distribution. The quantitative finding have to be supplemented by actual enzymic as indicated above.

The activity of 17 $\beta$ -hydroxysteroid dehydrogenase was reported in the connective tissue surrounding the rete testis of mic (Baillie, 1961). Baillie and Mack (1966) reported the localization of this enzyme in the seminiferous tubules from puberty onwards and in leydig cells of the prepubertal and adult human testis. The enzyme was also found leydig cells of cats, dogs and monkeys (Baillie *et al.*, 1966). Tingari (1973) demonstrated the enzyme in the interstitial tissue and the seminiferous tubules, but was unable Hay and Deane (1966) were unable to demonstrate this enzyme in the testis of stallion, boar, ram and bull when testosterone was used as a substrate. Bara (1972) was unable to demonstrate the enzyme in the interstitial cells of stannius of pseudopleuronectesamericanus. Osman (1975) also was unable to demonstrate this enzyme in the testis of camel when testosterone and oestrodial were used as substrates.

The finding and interpretation reported in this study provide basic information and indicates that further investigation involving ultra-structure and immunohistochemistry would contribute to a better understanding of these organs and correlates structure and function of the testes.

## REFERENCES

- Baillie, A.H., 1961. Observations on the growth and histochemistry of the leydig tissue in the postnatal prepubertal mouse testis. *J. Anat.*, 95(Pt 3): 357-370.
- Baillie, A.H. and K. Griffiths, 1964. 3 $\beta$ -hydroxysteroid dehydrogenase activity in the mouse leydig cell. *J. Endocrinol.*, 29: 9-17.
- Baillie, A.H. and W.S. Mack, 1966. Hydroxysteroid dehydrogenase in normal and abnormal human testes. *J. Endocrinol.*, 35: 239-249.
- Baillie, A.H., M.M. Fergusson and D.M. Hart, 1966. *Developments in Steroid Histochemistry*. Academic Press, New York.
- Bara, G., 1972. Histochemistry of hydroxysteroid dehydrogenases in the testes, adrenocortical tissue and corpuscle of stannius of pseudopleuronectesamericanus. *Acta Histochem.*, 44: 333-347.

- Bara, G., 1979. The ultrastructural localization of the enzymes related to steroid hormone metabolism in the guinea-pig testis. *Histochem. J.*, 11(1): 51-71.
- Bhagyashria, S. and V. Nadkarri, 1982. Steroidogenic potential of the testis of columbalivia during the preincubation, incubation and uab feeding period of the reproductive cycle. *Curr. Sci. India*, 51: 407-409.
- Chieffi, G., H. Manelli, V. Botte and L. Mastrolia, 1964. Distribution of cholesterol and  $\Delta^5$ - $3\beta$  hydroxysteroid dehydrogenase in chick embryo gonad. *RicercaScientifica*, 5: 77-84.
- Galil, A.K.A. and H.W. Deane, 1966.  $\Delta^5$ - $3\beta$  hydroxysteroid dehydrogenase activity in the steroid hormone producing organ of the ferret (*Mustelaputonufuro*). *J. Reprod. Fertil.*, 11: 333-338.
- Hay, M.F. and H.W. Deane, 1966. Attempts to demonstrate  $3\beta$ - and  $17\beta$ -hydroxy-steroid dehydrogenases histochemically in the testes of the stallion, Boar, ram and bull. *J. Reprod. Fertil.*, 12: 551-560.
- Maier, D.M., 1965. Species variation in testicular  $\Delta^5$ - $3\beta$ -hydroxysteroid dehydrogenase activity: Absence of activity in primateleydig cells. *Endocrinology*, 76(3): 463-469.
- Narbaitz, R. and L. Kolodny, 1964.  $\Delta^5$ - $3\beta$ -hydroxysteroid dehydrogenase in differentiating chick gonads. *Z. Zellforsch. Mik. Ana.*, 63(5): 612-617.
- Osman, M.A., 1975. On the morphology and histochemistry of the testis of camel (*Camelus dromedarius*). M.V.Sc. Thesis, University of Khartoum.
- Schreibman, M.P., E.J. Benkowitz and R. van den Hurk, 1982. Histology and histochemistry of the testis and ovary of the platyfish, *Xiphophorus maculatus*, from birth to sexual maturity. *Cell Tissue Res.*, 224(1): 81-87.
- Tetzlaff, G., 1987. 3 beta hydroxysteroid dehydrogenases in testis and epididymis of Pekin drake *Anas platyrhynchos*. *Acta Histochem.*, 81(1): 19-34.
- Tingari, M.D., 1973. Histochemical localization of  $3\beta$ - and  $17\beta$ -hydroxysteroid dehydrogenases in the male reproductive tract of the domestic fowl (*Gallus domesticus*). *Histochem. J.*, 5(1): 57-65.