

Research Article

Efficacy of Ceftobiprole in Treating of Osteomyelitis Due to Methicillin Resistant *Staphylococcus aureus* Rabbits

¹Orooba M.S. Ibrahim, ¹Khalid I. Adwan and ²Serwa I. Saleh

¹Department of Physiology and Pharmacology,

²Department of Surgery, College of Veterinary Medicine, Baghdad University, Baghdad, Iraq

Abstract: The present study was carried out to investigate antibacterial activity of ceftobiprole and vancomycin *in-vitro* and *in-vivo* after inducing osteomyelitis in rabbit by administration of Methicillin Resistant *Staphylococcus Aureus* (MRSA). Part I, evaluation is done *in-vitro* by using hot plate method for appearance zone of inhibition and Minimum Inhibitory Concentration (MIC) against (MRSA). Antibacterial susceptibility test showed that the ceftobiprole was more effective than vancomycin. Part II, inducing osteomyelitis (40 mg/kg B.W) compared with treated with vancomycin at a dose of (30 mg/kg B.W) subcutaneously for 28 days. Ceftobiprole succeeded to treat osteomyelitis by absence methicillin resistant *staphylococcus aureus* in the infected rabbits and prevented infection compared with vancomycin and radiographic pictures explained normal bone anatomy and all features of osteomyelitis disappeared. These results indicate that ceftobiprole provided effective parenteral treatment of osteomyelitis in this rabbit model.

Keywords: Ceftobiprole, osteomyelitis, rabbit, *staphylococcus aureus*, vancomycin

INTRODUCTION

The treatment of acute and chronic orthopaedic infections is difficult and often requires prolonged antibiotic therapy and surgical treatment. Osteomyelitis is a serious infectious disease that, absent app in rabbit by administration of methicillin resistant *staphylococcus aureus* and treated with ceftobiprole at a dose of ropriatetherapy, can lead to chronic pain, septic arthritis, disabling joint destruction, abnormal bone remodeling, vascular compromise, amyloidosis and Marjolin's ulcers. Inflammatory reactions to the invading pathogen form an exudate that collects locally and compresses blood vessels, leading to osteonecrosis. Osteomyelitis is common in developing countries and their treatment may belong-standing and difficult. It is very important infection because people who are diabetic or who have had a recent trauma have an increased risk of developing osteomyelitis (Brady *et al.*, 2006). Trauma such as an injury or a wound provides an opportunity for bacteria to enter the body and cause an infection that may spread to the bones. Osteomyelitis occurs in both sexes, but is twice as common in males as in females. Osteomyelitis can occurs at all ages in both males and females. The rising proportion of methicillin-resistance among *staphylococcal* infections in hospitals and in the community has compromised the effectiveness of this antibiotic class for *staphylococci* and resulted in the increased use of vancomycin to treat

patients with these infections (McDonald, 2006). As a consequence, Vancomycin-Intermediate *S. Aureus* (VISA) continue to increase in prevalence and Vancomycin-Resistant *S. Aureus* (VRSA) strains have begun to appear (Robert *et al.*, 2006). Linezolid, an oxazolidinone antibiotic with a gram-positive antibacterial spectrum of activity including MRSA (Fung *et al.*, 2001), was introduced in 2000 to address the growing problem of MRSA, but safety concerns have limited its utility. Ceftobiprole, is a new cephalosporin that unlike currently marketed β -lactams, has high binding affinity for penicillin-binding protein 2a (PBP2a) resulting in potent *in vitro* and *in vivo* activity against MRSA (Fernandez *et al.*, 2007). The prodrug form of this agent, ceftobiprolemedocaril, has completed two Phase III clinical trials in which efficacy was demonstrated against a broad spectrum of bacteria, including MRSA (Noel *et al.*, 2008). Therefore, this study was presented to find new antibiotic effective in treating of osteomyelitis caused by MRSA, as well as avoiding resistance to antimicrobial drugs. These aims maybe accomplish by studying the *in-vitro* antibacterial activity of ceftobiprole, vancomycin and *in-vivo* throw treatment of experimentally osteomyelitis with MRSA.

MATERIALS AND METHODS

Test organisms: A *staphylococcus aureus* isolate was obtained from the College of Veterinary Medicine/

Corresponding Author: Orooba M.S. Ibrahim, Department of Physiology and Pharmacology, College of Veterinary Medicine, Baghdad University, Baghdad, Iraq

This work is licensed under a Creative Commons Attribution 4.0 International License (URL: <http://creativecommons.org/licenses/by/4.0/>).

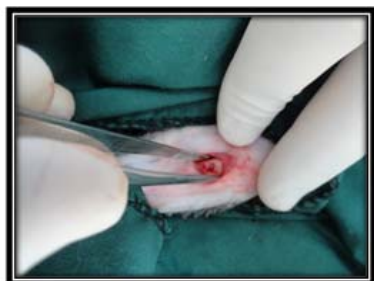

Fig. 1: Preparing rabbit

Department of zoonotic diseases/University of Baghdad. These isolates spp. were identified by studying morphological and some biochemical characteristics. The organisms were maintained on agar slants stocks and were subsequently sub cultured into newly prepared staph 110 agars and mannitol salt agar.

Determination of MIC: Minimum Inhibitory Concentration (MIC) was determined by using broth dilution assay method (Asghari *et al.*, 2006; NCCLS, 2000). In the tube dilution assay, standard bacterial suspension (1.5×10^8 cfu/mL) was added to the tubes containing 9 mL nutrient broth and different concentration of ceftobiprole and vancomycin, after 24 h incubation at 37°C , the tubes were examined for growth. The MIC of ceftobiprole and vancomycin was taken as the lowest concentration that showed no growth.

Antimicrobial susceptibility testing: Anti-microbial activity was checked by agar gel diffusion method. The cultures were grown in nutrient broth and incubated at 37°C , for 24 h. After incubation periods was over, 0.25 mL (1.5×10^8 cfu/mL) of culture was seeded in 25 mL molten Mueller Hinton agar butts, mixed and poured into sterile petri plates and allowed to solidify. The well was bored with 6 mm borer in seeded agar. 0.1 mL of each concentration of antibiotics was added in each well. Plates were kept at 10°C as a period of pre diffusion for 30 min. After it normalized to room temperature; the plates were incubated at 37°C for 24 h. Three replicates were carried out for each concentration of the (20) healthy male rabbit (local rabbits), their age ranged between 8-12 weeks, their weights ranged antibiotic after incubation period was over the zone of inhibition was measured with help of Hi-antibiotic zone scale.

Experimental animals: Twenty between 1.5-3 kg. were used to perform the experiment of the present study from (10/11/2011 to 10/2/2012). Rabbits were housed in plastic cages $90 \times 50 \times 70$ cm dimensions (5 rabbits /cage), placed in a special housing room belongs to the Department of Physiology and Pharmacology/ College of Veterinary Medicine for two weeks for

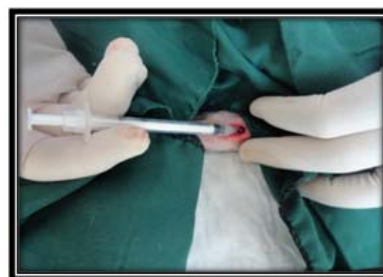

Fig. 2: Injection of bacterial suspension into tibia to induce osteomyelitis

adaptation. Standard rodent diet (Commercial feed pellets) and tap water were freely available.

Preparing the rabbits: After the adaptation period 2 weeks, the rabbits were anesthetized by intramuscular injection of 45 mg/kg of ketamine hydrochloride and 5.5 mg/kg of xylazine (Li-Yan *et al.*, 2008). The left hind limb was prepared surgically (by clipping the hair with electrical clipper, then about 30 g of hair removal cream (veet®) was applied for 3-5 min, after that removing the hair by gauze) from the stifle to the metatarsus (Fig. 1).

Inducing bone infection: After preparing the rabbit, incision about 2 cm in the upper medial aspect of the tibia, then subcutaneous structure was reflected bluntly to expose tibia bone exposed. A hole (1 mm) was made in the tibia by using dental drill, then 0.025 mL of bacterial suspension was injected intramedullary (Fig. 2). (After pilot study, the challenge dose which induced infection (acute infection) was 2.7×10^6 cfu/mL of MRSA suspension), a hole was filled with his to-wax, after that the skin was sutured with simple interrupted stitches using non absorbable suture (silk 2/0 USP, England). The infection was allowed to progress for 2 weeks and the animals were following up clinically for 14 day and watched for symptom of inflammation (Quinn *et al.*, 2004).

Experimental design: Twenty rabbit were divided equally into four groups, five rabbit in each group (treatment began after 28 days after inducing infection). Group (A): negative control, Group (B): positive control, Group (C): infected with MRSA and treated with Vancomycin 30 mg/kg B.W.S/C for 28 days and Group (D): infected with MRSA and treated with Ceftobiprole 40 mg/kg B.W. S/C for 28 days.

Body weight changes: Weight of the animals was measured and differences were assessed according to feed requirement and comparison between treated and control animals. These measurements were done a First week-Before inducing infection, after 28 days post infection and after 28 days post treatment.

Table 1: *In-vitro* antibacterial activity of ceftobiprole and vancomycin in different concentrations on MRSA (diameter of inhibition zone in mm)

Conc. µg/mL/Zone of Inhibition (mm)	2 µg/mL	4 µg/mL	6 µg/mL	8 µg/mL	10 µg/mL
Ceftobiprole	20.25±0.45Aa	22.125±0.12Ab	24.37±0.37Ac	25.75±0.32Ad	28.5±0.35Ae
Vancomycin	0.0±0.0.0 Be	13.37±0.23Bd	14.75±0.25Bc	16.125±0.23Bb	17.125±0.23Ba

Values represent mean ±S.E, Different capital letters mean significant ($p<0.05$) results between different groups; Different small letters mean significant ($p<0.05$) results between concentrations within group

Table 2: Morbidity and mortality rate of rabbits infected with Methicillin resistant *S. aureus* (MRSA) and treated with vancomycin and ceftobiprole

Period and Rates Group	Before infection		After 28 day post infection		After 28 day post treatment		Total mortality rates (%)
	Morbidity rate (%)	Mortality rate (%)	Morbidity rate (%)	Mortality rate (%)	Morbidity rate (%)	Mortality rate (%)	
Group A (-ve control)	0	0	0	0	0	0	0
Group B (+ve control)	0	0	100	60	100	0	60
Group (vancomycin 30 mg/kg)	0	0	100	20	0	0	20
Group (ceftobiprole 40 mg/kg)	0	0	100	0	0	0	0

Group no.= 5,0,+ve control: infected not treated group; -ve control: not infected not treated group; Group C, D: infected and treated groups with vancomycin and ceftobiprole, respectively

Clinical signs: Animals were continuously observed for clinical signs; Fever, bone pain, swelling and redness over the infection site, unusual movement, also any change in activity, behavior, death rate, chills and general illness or lack of energy of the animals were recorded weekly throughout the experiment.

Alkaline phosphatase test: Alkaline phosphatase kit that made by (Syrbio/France) was used to determine the concentration of serum alkaline phosphatase enzyme, according to the Ruben (2011).

Bone radiography: Radiographic examination was done for infected groups (B, C, D), osteomyelitis was confirmed radio graphically 28 day post infection, then treated with ceftobiprole and vancomycin, after that radiographic changes were detected every 2 weeks (mid of treatment, end of treatment) in groups C and D.

Statistical analysis: Data were analyzed statistically using the Microsoft Program (SPSS). Statistical analysis of data was performed on the basis of Two-Way Analysis of Variance (ANOVA) using a significant level of ($p<0.05$). Specific group differences were determined using Least Significant Differences (LSD) as described by Snedecor and Cochran (1973).

Re-isolation of bacteria: Re-isolation of bacteria performed to the scarified animals of infected groups (B, C and D). Bone marrow were swabbed with sterile cotton-tipped applicators and then streaked onto plates of mannitol salt.

RESULTS AND DISCUSSION

The microscopic appearance of *Staphylococcus aureus* is round and resembles that of a sphere (cocci). Because of the way the bacteria divide and multiply, it will appear in clusters or tetrads, gram-positive. Golden yellow to orange-pigmented colonies on Staph 110 agar and on blood agar, colonies appeared as golden yellow produces a zone of hemolysis surrounding the colony and it was non-motile. In addition to its microscopic appearance, *S. aureus* reacts to certain laboratory tests

very characteristically. All *staphylococci* produce the enzyme catalase when introduced to hydrogen peroxide. This test easily differentiates the *staphylococci* from the *streptococci*. It also produces the enzyme coagulase which allows the organism to produce a clot in rabbit plasma. This is a key test to differentiate *S. aureus* from other *staphylococci*. This description agrees with Subhankari *et al.* (2011) but *S. aureus* negative oxidase test.

Determination of MIC: The results of MIC estimated by tube dilution method showed that ceftobiprole relatively had low MIC (0.65 µg/mL) while for vancomycin is (2.0 µg/mL). The highest sensitivity was noticed with ceftobiprole and the lowest with vancomycin. This result is in agreement with Entenza *et al.* (2011) who showed The MICs of ceftobiprole and vancomycin for MRSA were 1 and 2 µg/mL, respectively.

Antimicrobial susceptibility testing: The size of inhibition zones were different according to concentration of the antibacterial agents, the size of inhibition zone proportionally increased with increasing of concentration of the agents, (Table 1). The results showed that MRSA was sensitive significantly ($p<0.05$) to ceftobiprole more than vancomycin in a dose dependent concentration. Ceftobiprole exerts its antibacterial effect by binding to PBP, inhibiting transpeptidation and formation of the bacterial cell wall, leading to cell lysis and death. The drug can bind to several different PBPs found in both Gram positive and Gram negative bacteria. Ceftobiprole rapidly binds and forms a stable inhibitory acyl complex with PBP 2' (PBP 2a) and PBP 2x, which provide activity against β -lactam resistant *staphylococci* and *streptococci* respectively. The stability of the enzyme complex, in combination with the long side chain that sits deep in the PBP 2'-binding pocket, enhances the stability of the bond and inhibition of the enzyme (Kisgen and Whitney, 2008; Bustos and Pozo, 2010). While Vancomycin inhibits transpeptidation by binding to D-alanyl-D-alanine residues of the bacterial cell wall,

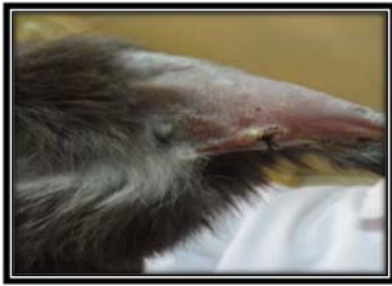

Fig. 3: Shows Site of operation ten days post infection with abscess formation

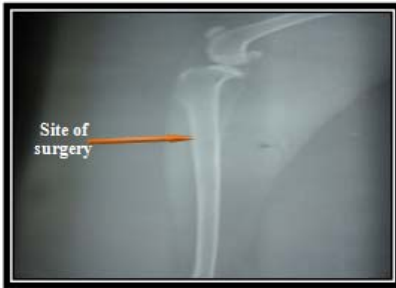

Fig. 4: Shows tibia 21 days post-surgery for -ve control rabbit

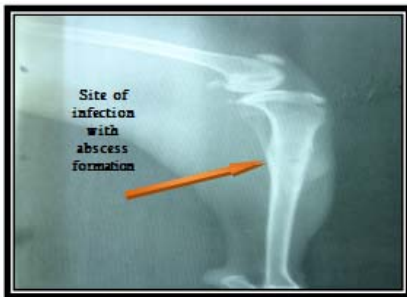

Fig. 5: Shows affected area 28 days post infection with MRSA

historically has been the treatment of choice for MRSA infections, but adverse effects, the need for intravenous access and growing resistance limit its use (Sharpe *et al.*, 2005).

Part II: Clinical Signs: All animals are healthy before induction of infection, 2 days after infection of animals (group B, C, D), were suffering from fever (40°C), with early symptoms of osteomyelitis swelling redness over the site of infection and recurring infections in the soft tissue above the bone and an open, draining wound caused when pus formed in the infected bone breaks through the surface of the skin (10 day post infection) (Fig. 3).

Morbidity (infection) rate was 100% in infected groups; the highest mortality rate was 60% in group B (+ve control) along the period of experiment, while 20% mortality rate was recorded in group C, while group D

did not show any mortality and did not lose any animal during the period of experiment as shown in (Table 2).

The changes in body weight gave an evidence of correlation between infection, kind of treatment and dose of treatment that used in different groups, Rabbits are particularly prone to gastrointestinal disturbances consequent to long-term antibiotic therapy, so all animals were monitored for changes in body weight. After 28 day of infection, there was significant decrease in body weight in all infected groups (Table 3). It can be concluded that loss of appetite is common manifestation of acute infectious illness and it is believed to contribute to the negative nitrogen balance and loss of body weight that is seen during infection. It seems that food intake should be voluntarily suppressed at time when metabolic rate can raise 10-13% for each degree centigrade rise in body temperature. The decrement in food intake in some of study groups is agreement with Patton *et al.*, (1987) that referred that suppression of food intake and anorexia commonly occur during infection. After 28 day of treatment of group C with vancomycin showed little increase ($p>0.05$) in body weight (from 1.40 to 1.50 kg) when compared with other group. Nearly all the rabbits treated with ceftobiprole exhibited symptoms of Gastro intestinal distress (decreased appetite, dehydration, diarrhea and/or weight loss) beginning 1 to 1.5 weeks after the commencement of antibiotic treatment (Li-Yan *et al.*, 2008). Similar result they found by Forrester (2002), they recorded the highest body weight loss happened in second period of infection with *staph. aureus*. Protein breakdown was elevated during the acute and chronic phases of infection, sepsis causes a severe and persistent loss of body protein, much of which originated from skeletal muscle.

Different levels of serum alkaline phosphatase in all infected rabbits are listed in (Table 4). There was a significant increase ($p<0.05$) in all groups. In bone, cells called osteoblasts produce alkaline phosphatase during the formation of bone. Bone damage, either by infection or inflammation, releases large amount of alkaline phosphatase into the blood stream (Ruben, 2011). The serum alkaline phosphatase values return to near normal values after 28 day of treatment with vancomycin (from 88.26 to 51.98 U/I) and ceftobiprole. The result of the current study was in agreement with (Gennari *et al.*, 2005) that showed an increased level of serum alkaline phosphatase in bone infection.

Bone radiography: After radiographic examination of tibia, -ve control (group A) showed normal bone anatomy in all period of experimental (show zero radiography) (Fig. 4), while +ve control (group B) did not show radio graphic changes after 14 day post infection but after 28 day post infection there was significant osteomyelitis by showing lytic center, dead bone (necrosis) with sclerosis in addition to grossly

Table 3: Weight change (in kg) of rabbit's infected with *S. Aureus* and treated with vancomycin and ceftobiprole

Group Period	Group A (-ve control)	Group B (+ve control)	Group C Vancomycin 30 mg/kg	Group D Ceftobiprole 40 mg/kg
Before infection	2.00±0.07B a	2.06±0.08A a	1.68±0.07A b	1.54±0.02A b
28 day post infection	2.300±0.05A a	1.76±0.08B b	1.40±0.07B c	1.24±0.02B c
28 day after treatment	2.36±0.06A a	1.44±0.07C b	1.50±0.05AB b	1.20±0.02B c

Value represent mean± S.E, Group no.= 5 , LSD = 0.1794 , Different small letters mean significant (p>0.05) results between periods, Different capital letters mean significant (p<0.05) results between groups, +ve control: infected not treated group, -ve control: not infected-not treated group

Table 4: Serum Alkaline phosphatase values (U/l) of rabbits infected with MRSA and treated with vancomycin and ceftobiprole

Group Period	Group A (-ve control)	Group B (+ve control)	Group C Vancomycin 30 mg/kg	Group D Ceftobiprole 40mg/kg
Before infection	43.56±4.40A a	39.44±3.47A a	41.42±2.48B a	35.33±0.46B a
28daypost infection	43.80±4.61A a	77.93±6.50B b	88.26±2.03A b	80.76±1.72A b
28 day post treatment	41.06±4.39A c	79.02±4.93B a	51.98±3.47B b	44.51±1.56B bc

Value represent mean± S.E; Group no. = 5; LSD = 10.599; Different small letters mean significant (p>0.05) results between periods; Different capital letters mean significant (p>0.05) results between groups; +ve control: infected not treated group; -ve control: not infected-not treated group

Table 5: Summary of radiographic pictures in different groups

Period group	Group A (-ve control)	Group B (+ve control)	Group C (vancomycin 30 mg/kg)	Group D (ceftobiprole 40 mg/kg)
14 day post infection	-ve	-ve	-ve	-ve
28 day post infection	-ve	++ve	++ve	++ve
14 day post treatment	-ve	++ve	+ve	+ve
28 day post treatment	-ve	++ve	+ve	-ve

-ve: Radiographic picture showed normal anatomical bone feature; ++ve: Radiographic picture showed area of osteolysis and area of osteoseclerosis; +ve : Some radiographical changes still existed and bone marrow has few infection

signs of osteomyelitis as swelling, redness over the infection site and abscess (Fig. 5) and the same of result was showed in other periods (mid and end of treatment). In group C, radiographic pictures did not show obvious changes in bone anatomy in 14 day post infection with MRSA, but there was a significant after 28 day post infection and in the mid of treatment with vancomycin 30 mg/kg B.W. In the end of treatment with vancomycin most features of osteomyelitis disappeared (Fig. 6). Wilson and Mader (1994) found that there are reduce in radiographic scores for MRSA-infected rabbits after 28 days treatment with vancomycin and linezolid. In group D, the same results with ceftobiprole 40 mg/kg B.W. as vancomycin. There was no changes in tibia in the first 14 days post infection with MRSA, but there was significant osteomyelitis (positive result) after 28 day post infection and in the mid of treatment with ceftobiprole. In the end of treatment (after 28 day of treatment) radiographic pictures explained normal bone anatomy and all features of osteomyelitis disappeared (Fig. 7) and this agreed with Yin *et al.* (2009) which showed that returned the bone to the normal state after treatment with ceftobiprole, vancomycin, with or without rifampicin. All results above showed in (Table 5).

It can be concluded that the diagnosis of osteomyelitis is more often based on radiographic evidence of bone lysis, production and necrosis. In osteomyelitis, the inflammatory changes may involved only soft tissues or soft tissues and periosteum. Some or all of these tissues, as well as marrow, are affected in osteomyelitis and their involvement (marrow) may cause bony changes that are more obvious than the initial soft-tissue inflammation (Cattcott, 1974). Necrosis of bone occurs when its capillaries are damages, it is likely that bacterial toxins are also capable of causing necrosis of bone through their effect on osteocytes. In

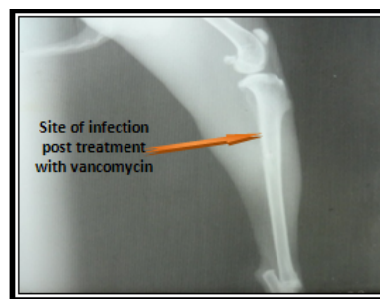


Fig. 6: Shows tibia 28 days post treatment with vancomycin

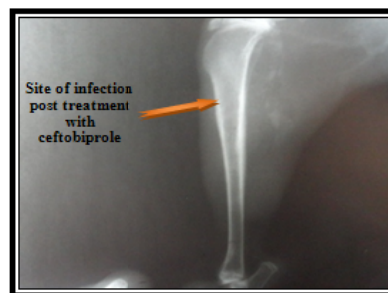


Fig. 7: Shows tibia 28 days post treatment with ceftobiprole

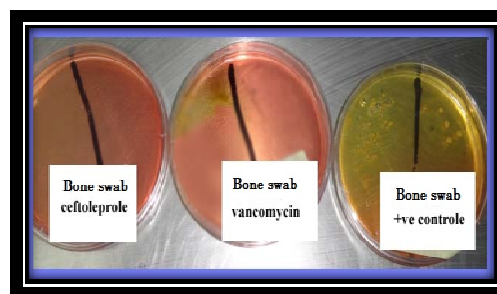


Fig. 8: Shows re-isolation of bacteria from marrow of the rabbits treated with ceftobiprole and vancomycin and +vecontrol group

later stages of osteomyelitis, necrotic bones or pieces of necrotic bone may be identified by new bone formation, by separation and sequestration and by their relative denseness (Kealy *et al.*, 2011). The radiographic changes in bone infection are lysis and production, which usually are equal in degree and the formation of sequestra. All these changes reflect the degree of infection (Catcott, 1974).

Re-isolation of bacteria: The results of re-isolation of bacteria of the rabbits treated with ancomycin and ceftobiprole (group C and D) (Fig. 8), showed absence of growth of *S. aureus* on mannitol salt agar. While group B (+ve control) showed presence of growth of *S. aureus* and this agreed with Yin *et al.* (2009).

REFERENCES

- Asghari, G., H. Nourallahi, S. Havaie and L. Issa, 2006. Antimicrobial activity of *Otostegiapersi* caBoiss extracts. RPS, 1: 53-58.
- Brady, B.A., J.G. Leid, J.W. Costerton and M.E. Shirtliff, 2006. Osteomyelitis: Clinical overview and mechanisms of infection persistence. Clin. Microbiol. Newslett., 28:65-72.
- Bustos, C. and J.L.D. Pozo, 2010. Emerging agents to combat complicated and resistant infections: Focus on ceftobiprole. Infect. Drug Resist., 3: 5-14.
- Catcott, E.J., 1974. Canine Surgery. 2nd Edn., pp: 917-920.
- Entenza, J.M., T.R. Veloso, J. Vouillamoz, M. Giddey, P. Majcherzyk and P. Moreillon, 2011. In Vivo synergism of ceftobiprole and vancomycin against experimental endocarditis due to vancomycin-intermediate *Staphylococcus aureus*. Antimicrob. Agent Chemother., 55(9): 39-77.
- Fernandez, J., J.J. Hilliard, J.L. Melton, D. Abbanat, R.K. Flamm and K.Bush, 2007. In Vivo activity of ceftobiprole in a pseudomonal murine skin infection model, abstr. 437. Abstr. Proceeding of the 45th Annual Meeting of the Infectious Diseases Society of America (IDSA), San Diego, CA.
- Fung, H.B., H.L. Kirschenbaum and B.O. Ojofeitimi, 2001. Linezolid: An oxazolidinone antimicrobial agent. Clin. Therap., 23:356-91.
- Li-Yan, Y., H.C. Jason, K.T. Jacob, S. Stuart and S.H. Anne, 2008. Efficacies of Ceftobiprole Medocaril and Comparators in a Rabbit Model of Osteomyelitis Due to Methicillin-Resistant *Staphylococcus aureus*. Antimicrob. Agents Chemother., Shapiro Anne Schmitt-Hoffmann, 52(5):1618-1622.
- Kealy, J.K., H. Callister and P.G. John, 2011. Diagnostic Radiography and Ultrasonography of Small Animals. 5th Edn., pp: 433-436.
- Kisgen, J. and D. Whitney, 2008. Ceftobiprole: A broad-spectrum cephalosporin with activity against Methicillin-Resistant *Staphylococcus aureus* (MRSA). PT, 33: 631-641.
- McDonald, L.C., 2006. Trends in antimicrobial resistance in health care associated pathogens and effect on treatment. Clin. Infect. Dis., 42(Suppl 2): S65-71.
- NCCLS, 2000. National Committee for Clinical Laboratory Standards. Approved Standard M7-A5: Methods for Dilution Antimicrobial Susceptibility Test for Bacteria that Grow Aerobically. 5th Edn., Wayne, P.A.
- Noel, G.J., R.S. Strauss, K. Amsler, M. Heep, R. Pypstra, *et al.*, 2008. Results of a double-blind, randomized trial of ceftobiprole treatment of complicated skin and skin structure infections caused by gram-positive bacteria. Antimicrob. Agents Chemother., 52: 37-44.
- Quinn, P.J., M.E. Carter, B. Markey and G.R. Carter, 2004. Clinical Veterinary Microbiology. Oxford and Philadelphia, Mosby. Edinburgh, London, New York, USA, pp: 21-63.
- Robert, J., R. Bismuth and V. Jarlier, 2006. Decreased susceptibility to glycopeptides in methicillin-resistant *Staphylococcus aureus*: A 20 year study in a large French teaching hospital, 1983-2002. J. Antimicrob. Chemoth., 57: 506-10.
- Ruben, N., 2011. Alkaline phosphatase and bone disease. Hospitalist and is the general editor of "Hospital Pediatrics". A Journal of the American Academy of Pediatrics.
- Sharpe, J.N., E.H. Shively, C. Hiram and J. Polk, 2005. Clinical and economic outcomes of oral linezolid versus intravenous vancomycin in the treatment of MRSA-complicated, lower-extremity skin and soft-tissue infections caused by methicillin-resistant *Staphylococcus aureus*. Am. J. Surg., 189(2005): 425-428.
- Snedecor, G.W. and W.G. Cochran, 1973. Statistical Methods. 6th Edn., Iowa State University Press, USA, pp: 238-248.
- Subhankari, P.C., K.M. Santanu and R. Somenath, 2011. Biochemical characters and antibiotic susceptibility of *Staphylococcus aureus* isolates. Asian Pac. J. Trop. Biomed. India, 1(3): 212-216.
- Wilson, K.J. and J.T. Mader, 1994. Radiographic changes in bone and serum of normal rabbits and those with osteomyelitis. Antimicrob. Agents Chemother., 25: 140-141.
- Yin, L.Y., L.F. Lazzarini, C.M. Stevens and J.H.Calhoun, 2009. Comparative evaluation of ceftobiprole and vancomycin, with and without rifampicin, in the treatment of methicillin-resistant *Staphylococcus aureus* experimental osteomyelitis in a rabbit model. J. Antimicrob. Chemother., 55: 995-1002.