

## Research Article

### Histomorphological Comparison of Proventriculus and Small Intestine of Heavy and Light Line Pre- and at Hatching

<sup>1</sup>Osama Nassir Wali and <sup>2</sup>Khalid K. Kadhim

<sup>1</sup>Department of Biology, Faculty of Science, University of Misan, Amarah,

<sup>2</sup>Department of Anatomy and Histology, Faculty of Veterinary Medicine, University of Baghdad, Jadriyah, Baghdad, Iraq

**Abstract:** Gross, histomorphometric and histochemical comparison of proventriculus and small intestinal segments were determined in heavy and light line at last day's incubation. Five embryos from each line were used at 16 day, 19 day and 21 day incubation. The weight of the proventriculus, yolk sac and weight in addition to the length of each separated straightened intestinal segments were recorded. Histological samples were stained with Harris Hematoxylin and Eosin, Masson's Trichrome stain for histological structures, combined Alcian blue-PAS and Aldehyde Fuschin-Alcian blue stain for mucin classification. The thickness of wall layers of these organs were determined, measurement of villus height, villus surface area and height of epithelial mucosa of each intestinal segments (duodenum, jejunum and ileum) were recorded. The relative weight of yolk sac, proventriculus, jejunum and ileum were significantly higher in heavy line. The relative length of intestine was not constant between breeds. However, the heavy line had longer jejunum and ileum at 16 day and 21 days incubation. Histologically, the well-developed proventricular glands and epithelial folds appeared since 16 day incubation in both breeds. The thicknesses of these glands was greater in heavy line. The duodenal of heavy line had dominantly longer villi with higher villus surface area, for jejunum was restricted at 21 days only. Similar pattern was found for epithelial height and number of goblet cells in intestinal mucosa. The histochemical observations showed presence of neutral and acidic mucin in intestinal epithelium with most mucous cells were had sulphated mucin. Intestinal development patterns were similar for both lines but growth was more rapid in heavyline than the light line.

**Keywords:** Goblet cell, heavy and light line, histochemical, histomorphometric, surface area, villi

## INTRODUCTION

The broilers are marketed much earlier than in the past, many earlier studies focused on the development of the Gastro-Intestinal Tract (GIT) during the post-hatching growth period to clarify the changes occurring in this tract during selection for fast growth (Lilja, 1983; Katanbaf *et al.*, 1988). In the held bird, the substrates for growth apparently originate from the yolk, indicating the high priority apportioned to intestinal growth in the post-hatch chick (Nitsan *et al.*, 1991). The morphological measurements can be used as additional criteria for evaluating development in chick intestine (Uni *et al.*, 1996). The proventricular mucosa is lined by simple cuboidal to columnar cells and both acid and neutral mucin reactions take place here (Selvan *et al.*, 2008). The mucosal surface area of the small intestine in chicken undergoes important changes during development which may determine the capacity to absorb nutrients (Mitjans *et al.*, 1997; Yamauchi and Tarachai, 2000). The villus surface area depends mainly on the villus height more than villus width (Sklan,

2001). The villi height, villi surface area is higher proximally and decline towards the terminal ileum of the chicken (Marchini *et al.*, 2011).

The surface area of the small intestine is significantly greater in heavy than the light line of chicken (Mitchell and Smith, 1991). It has been reported that differences in villus height and width can affect the body weight and performance; increased surface area available for nutrient absorption likely enhances growth and production (Schaefer *et al.*, 2006). These parameters are related to changes in intestinal function and may be suitable to assess villus function (Yamauchi and Tarachai, 2000; Maneewan and Yamauchi, 2003).

It is known that light breed chicken is characterized by a slow growth rate compared with heavy breed chicken that have rapid growth rate. However, to my knowledge there is a dearth of information relating to the digestive system at pre hatch period. Data can be compared, the commercial broiler chickens that have been consciously selected for high body weight with light breed of chicken to illustrate the effects of the

**Corresponding Author:** Khalid K. Kadhim, Department of Anatomy and Histology, Faculty of Veterinary Medicine, University of Baghdad, Jadriyah, Baghdad, Iraq

This work is licensed under a Creative Commons Attribution 4.0 International License (URL: <http://creativecommons.org/licenses/by/4.0/>).

artificial selection on the anatomical traits of the digestive organs. Therefore, our interest was to compare the histomorphology and the growth patterns of the proventriculus and the small intestinal segments at pre-hatching periods.

## MATERIALS AND METHODS

**Animals:** A total of 15 embryos from each heavy and light breed (Ross) were used in this study. The eggs of the both breeds are supplied from AL-Hadetha Company and incubated by a private hatchery (AL-Amal). Five embryos from each breed were used at 16 day, 19 day and 21 day incubation.

**Collection of tissue samples:** Each embryo was individually weighed. A mid-line incision was made to expose the digestive organs. The collected specimens were included the proventriculus, the small intestine (duodenum, jejunum and ileum) and the yolk sac. These organs were washed with saline solution to remove any other adhering debris. The small intestine was then divided into duodenum, jejunum and ileum, as the duodenum commences at the pyloric junction to the ligament of Treitz, while the jejunum extends from this ligament to the yolk stalk. The ileum extended from the later structure to the ileo-cecal-colonic junction, following the demarcation set by Geyra *et al.* (2001). The weight of the proventriculus, yolk sac and weight and length of each separated straightened intestinal segments were recorded.

**Histological and histochemical methods:** Samples were taken for histological examinations, including the cross section from the proventriculus and from the mid-point of each part of (duodenum, jejunum and ileum). Samples were fixed in 10% Neutral Buffered Formalin (NBF) for 24 h and processed using standard histological procedures. The organs were embedded vertically in paraffin wax (Baddeley *et al.*, 1986). Sections of 5  $\mu$ m thick were stained with Harris Hematoxylin and Eosin, Masson's Trichrome stain (Humason, 1972). Alcian blue, combined Alcian blue-PAS technique for acid and neutral mucins and Aldehyde Fuschin-Alcian blue stain for carboxylated and sulphated mucin (Totty, 2002).

**Measurement of villus height and villus surface area:** The villus height, villus width and villus surface area of duodenum were determined by selection of ten intact villi from the mid-point of duodenum under the dissection microscope (Kruss Ootronic, Germany) provided by camera, using fine needles to separate the villi. Specimens were mounted on microscopic slides with one drop of saline added to prevent dehydration and conformation of these villi. The villi were then

flattened forcefully with a cover-slip with the edges of the cover-slip being sealed with DePeX. The villi surface area was finally doubled, under the assumption that each villus consisted of two flat sheets that bent to meet each other only in the region of the villus perimeter (Smith *et al.*, 1990). The dimensions of villi in jejunum and ileum were obtained through the cross section of each small intestinal segment on the microscopical slide, following the procedure suggested by Iji *et al.* (2001). All the Images were uploaded into a computer by means of a digital camera (MEM 1300) through the microscope. The measurements have been carried out with image J (Java-based image processing program developed at the National Institutes of Health).

The data from each small intestinal segment for each bird were compared between breeds for villi height and villi surface area, epithelial cells height and number of goblet cells.

The measurements were taken individually for each intestinal segment. Both mean and standard deviation were calculated. The significance of the differences between the data from both lines was estimated with t test using SPSS version 20.

## RESULTS AND DISCUSSION

There were significantly different between the heavy and light breed in total body weight (Fig. 1), however, Dror *et al.* (1977) showed that heavy breed was 17% heavier than the light breed at 21 days incubation. In this study the relative yolk weight was higher at 16 d and 19 d for heavy line (Fig. 2A). Nitsan *et al.* (1991) suggests considerable complexity in relation to the need and use of this material during the embryonic periods in heavy line. It was hypothesized that these nutrients are used to develop the GIT during the embryonic period in preparation for the extreme changes required for consuming and assimilating

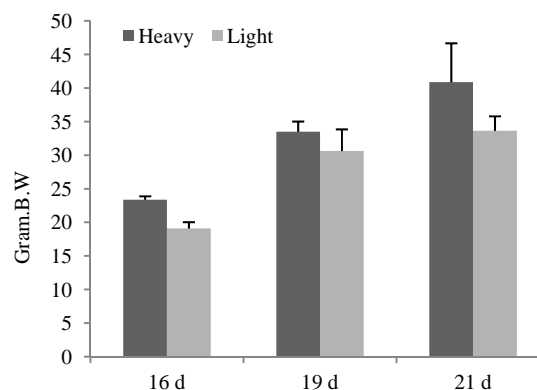


Fig. 1: The total body weight of heavy and light line, from 16 day to 21 day pre-hatch. Values are means  $\pm$  SD, N = 5. Star indicating significant differences ( $p < 0.05$ )

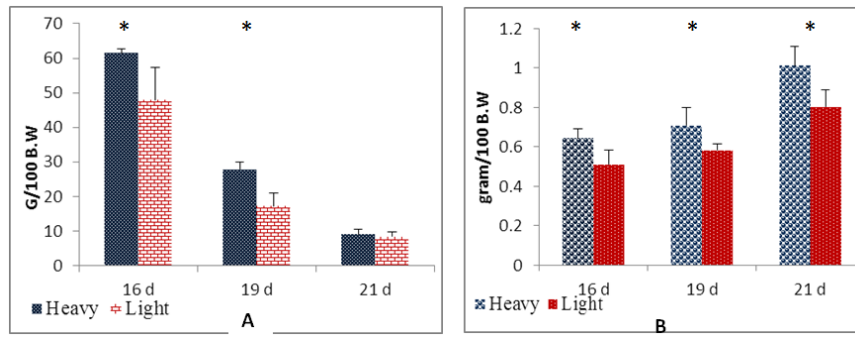


Fig. 2: The relative weights of the yolk sac, (A) Proventriculus, (B) of heavy and light line, from 16 day to 21 day pre-hatch. Values are means  $\pm$  SD, N = 5. Star indicating significant differences ( $p < 0.05$ )

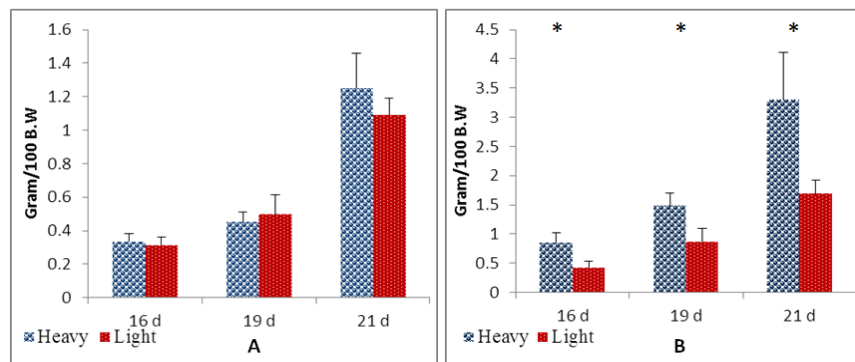


Fig. 3: The relative weight of Duodenum, (A) Jejunum and ileum, (B) of heavy and light line, from 16 day to 21 day pre-hatch. Values are means  $\pm$  SD, N = 5. Star indicating significant differences ( $p < 0.05$ )

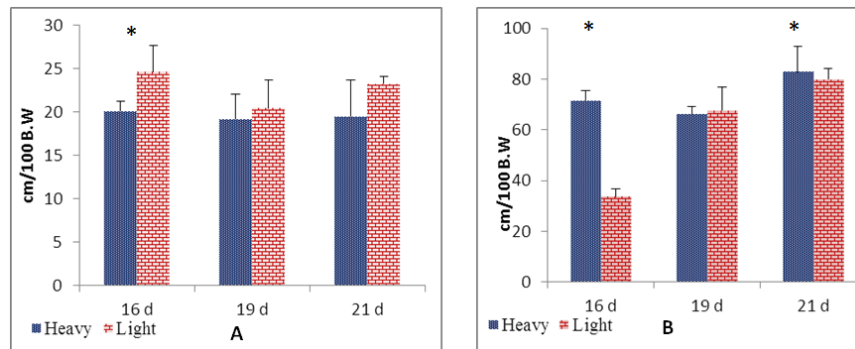


Fig. 4: The relative length of Duodenum, (A) Jejunum and ileum, (B) of heavy and light line, from 16 day to 21 day pre-hatch. Values are means  $\pm$  SD, N = 5. Star indicating significant differences ( $p < 0.05$ )

considerable amounts of food after hatch (Murakami *et al.*, 1992; Uni *et al.*, 1999). However, the vitelline residue is not affected by genetic background between heavy and light line according to Nir *et al.* (1993).

Regard to the relative proventriculus weight, the heavy line had values which were consistently higher than light line (Fig. 2B). These results are consistent with the thesis that growth is greater for supply than for demand organs in preparation for the subsequent period post-hatch (Lilja, 1983; Katanbaf *et al.*, 1988).

There was no difference in the relative duodenum weight between the two breeds, however, there was for

jejunum and ileum (Fig. 3A and B). The relative duodenum length showed greater value in 16 day for light line only, while for jejunum and ileum were greater in heavy line at this age and at 21 day (Fig. 4A and B). These results are constant with suggestion of Uni *et al.* (1999) that, the temporal increases in intestinal weights and lengths are not identical in the different segments, with the duodenum showing earlier rapid growth than either the jejunum or ileum.

**Microscopical results:** The histological structure of the proventriculus at 16 days incubation was characterized

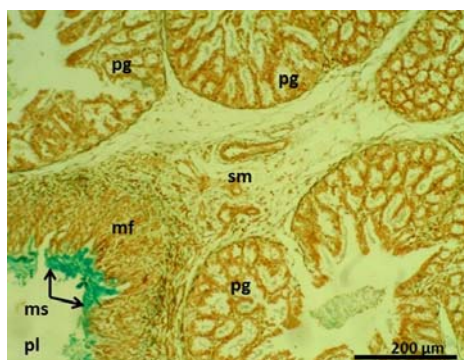


Fig. 5: The proventriculus of heavy line at 16 day incubation shown mucous secretion (ms) in the lumen (pl), the mucosal folds (mf), proventriculus glands (pg), submucosa (sm). Masson's Trichrome stain

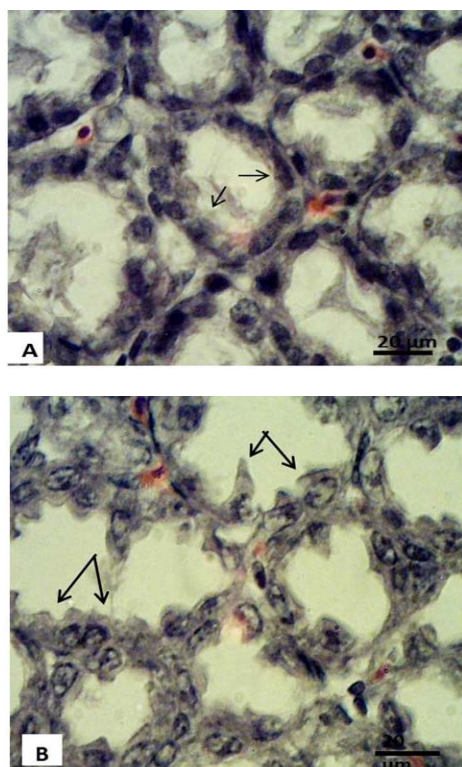


Fig. 6: The alveoli of glandular lobules of the proventriculus at, A) a 16 day incubation of light breed showing cuboidal cells (arrows), B) a 21 day incubation of light breed showing columnar glandular cells showing a dentate appearance (arrows). H & E stain

by presence of long mucosal folds (plicae) which appeared well developed for both breeds since this period and up. The mucous secretion of the epithelia lining these folds was very clear (Fig. 5). The well-developed compound tubuleoalveolar glands (proventriculus glands) were occupied large area of the stomach wall between the inner and outer layers of muscularis mucosa. The size and number of the gland lobules has increased with age. These data agreed with report of Attia (2008) in quail embryos. The

Table 1: Histomorphometric of the proventricular wall of the Heavy and Light lines from 16 day to 21 days incubation, means  $\pm$  SD, N = 5

Line		Age		
		16 day	19 day	21 day
P.G	Heavy	599 $\pm$ 69	795 $\pm$ 84*	803 $\pm$ 45*
	Light	588 $\pm$ 35	658 $\pm$ 78	664 $\pm$ 12
T.M	Heavy	93 $\pm$ 10	109 $\pm$ 15	132 $\pm$ 10*
	Light	83 $\pm$ 11	107 $\pm$ 15	110 $\pm$ 13

\*Superscripts within column at the same age were significantly different ( $p < 0.05$ ), P.G. Proventricular glands; T.M. Tunica muscularis

development of the embryonic proventriculus was done at 7 days of incubation in chicken and begins to branch at 10 days, it increase more up to 13 days (Martinez *et al.*, 1993).

At 16 day incubation, the cells lining the glandular alveoli, collecting tubules and excretory duct were cuboidal, the cells were increased with age to columnar with a dentate appearance and basal-located nucleus (Fig. 6). Ogunkoya and Cook (2009) also remarked that the lack of cytoplasmic organelles to stain along the lateral walls of these cells might have contributed to the dentate appearance observed by light microscopic. In our observations, the glandular mass and the muscular wall were increased while the septa of collagen and elastic connective tissue were decreased in the late incubation period.

In this study, in both breeds the *tunica muscularis* of the proventriculus consisting of thick inner circular and thin external longitudinal layer of smooth muscles. As reported by Khalid *et al.* (2011) in post-hatch chicks.

The histomorphometric observation of the proventricular wall showed no difference in the thickness of the proventricular gland between two lines at 16 day, but there was at 19 day and 21 day for heavy line (Table 1). Increase in the thickness of the proventriculus glands are important for producing of the gastric juice (Selvan *et al.*, 2008). This appears to have effect on the rapid growth rate of this breed.

The thickness of tunica muscularis of proventriculus showed no difference between lines at 16 day and 19 day, but it seemed greater for heavy line at 21 day (Table 1). The increase was on account the glandular layer thickness. This may mean the late incubation period is being prepared to face a new diet.

The four layers of the intestinal wall were clear since the 16 day in cubation in both breeds, although the intestinal crypts remained open up to 21 days.

The histological observation of the duodenal mucosa appeared that the heavy line possess longer villi and greater villus surface area all over the experiment (Fig. 7A and B). However, the jejunal villi were significantly longer with greater surface area in heavy line at 21 day only (Fig. 8A and B). In contrast to the

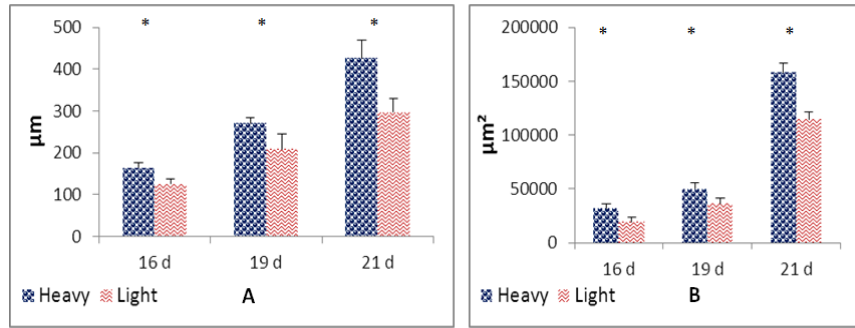


Fig. 7: The villus height, (A) and villus surface area, (B) of duodenum for the heavy and light breed from day 16 to day 21 pre-hatch. Values are means  $\pm$  SD. N = 5. Starsymbols indicating significant differences (P<0.05)

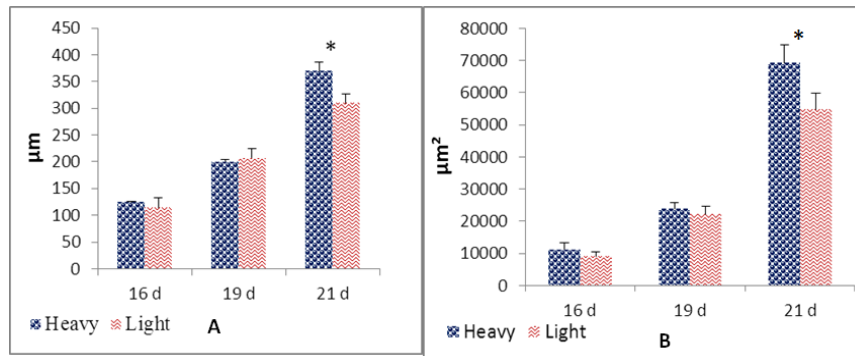


Fig. 8: The villus height, (A) and villus surface area, (B) of Jejunum for the heavy and light breed from day 16 to day 21 pre-hatch. Values are means  $\pm$  SD. N = 5. Starsymbols indicating significant differences (P<0.05)

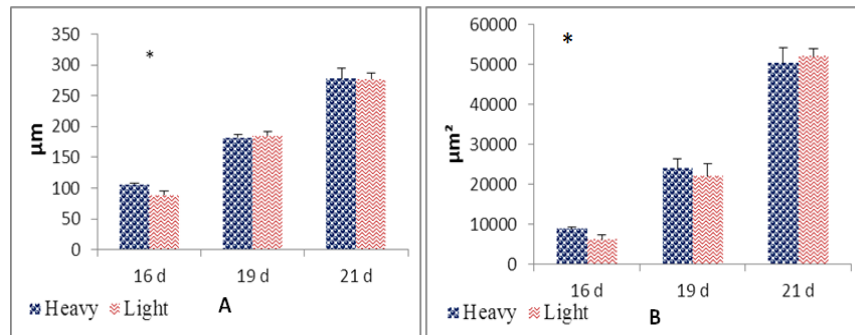


Fig. 9: The villus height, (A) and villus surface area, (B) of Ileum for the Heavy and Light breed from day 16 to day 21 pre-hatch. Values are means  $\pm$  SD. N = 5. Starsymbols indicating significant differences (P<0.05)

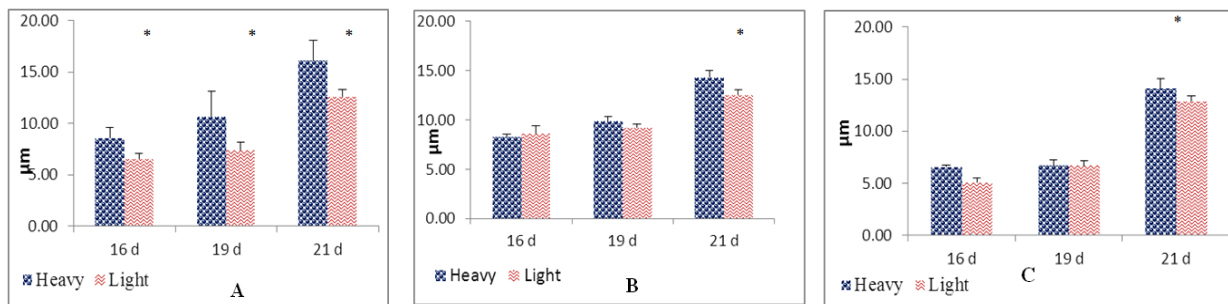


Fig. 10: Epithelial height of Duodenum, (A) Jejunum, (B) and Ileum, (C) for the heavy and light breed from day 16 to day 21 pre-hatch. Values are means  $\pm$  SD. N = 5. Starsymbols indicating significant differences (P<0.05)

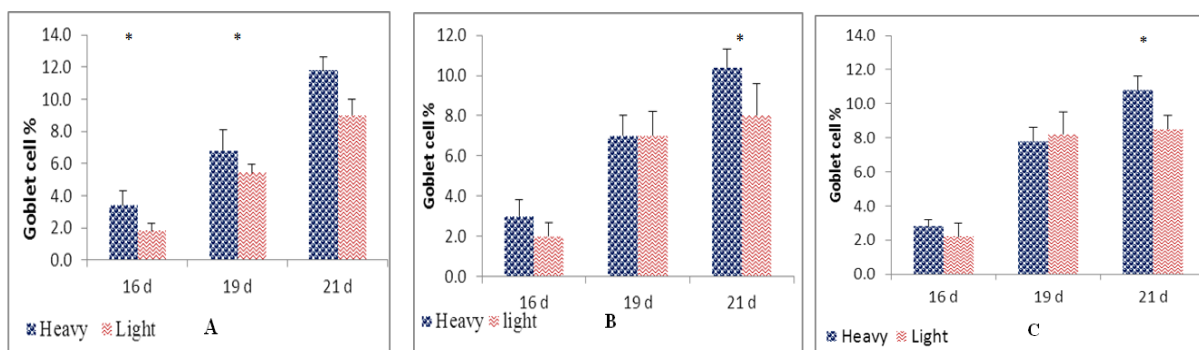


Fig. 11: Number of goblet cells (%) of Duodenum, (A) Jejunum, (B) and Ileum, (C) for the heavy and light breed from day 16 to day 21 pre-hatch. Values are means  $\pm$  SD. N = 5. Starsymbols indicating significant differences (P<0.05)

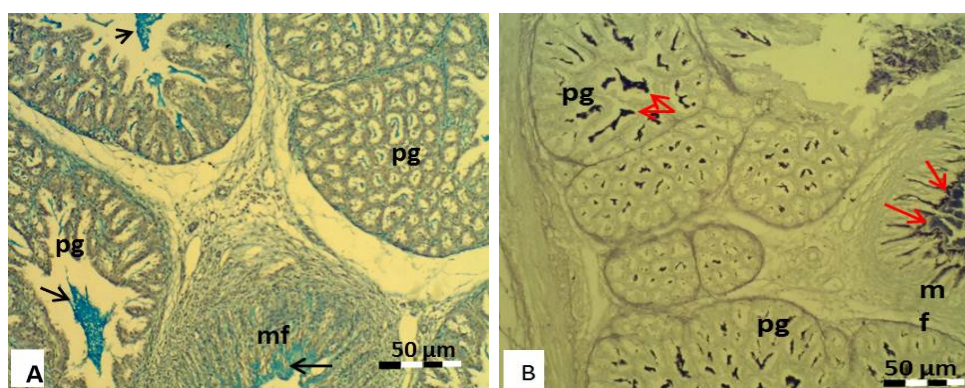


Fig. 12: The proventricular glands (pg) and mucosal folds (mf) at 16 day incubation of light breed showing, A) acid mucin reaction (arrows). Combined Alcian blue-PAS stain, B) sulphatedmucin reaction (arrows). Aldehyde Fuchsin-Alcian blue stain

ileum villi of the heavy line which were longer with greater villus surface area at 16 day only, then showed no difference later (Fig. 9A and B). It has been suggested that long villi result in an increase surface area capable of greater absorption of available nutrients (Schaefer *et al.*, 2006). Furthermore, Marchini *et al.* (2011) reported that the villus length in the duodenum increase earlier than in jejunum and ileum which its increase gradually.

The results of measuring the height of the intestinal epithelium have shown higher duodenal epithelium height in heavy line. However, this line showed no difference for jejunal and ileal epithelium than the light line except at 21 day (Fig. 10). Regard to these results, Uni *et al.* (2007) suggested that in the last week of incubation, intestinal growth appears not from cellular hypertrophy, its arise mainly from cellular hyperplasia.

The results of goblet cells count among the duodenal epithelium were greater in heavy line. However, this line did not show an increase in the number of goblet cells in jejunal and ileal epithelium than the light line except at 21 day (Fig. 11), Ding *et al.* (2011) reported that an increase in goblet cells number during the later incubation and at hatching could indicate the small intestine is preparing to receive food.

**Histochemical observations:** Our results on the presence of acid mucin secretion from the cells lining the proventricular folds not agreed with the reports of Shyla *et al.* (1992), that mucin showing only neutral reaction. However, Selvan *et al.* (2008) detected both acid and neutral mucin reactions in the cells lining the epithelium. This mucin forms a gel over the epithelial surface as a lubricant and protective barrier to physical damage by the luminal contents (Neutra and Forstner, 1987). Our results are similar to the findings of Selvan *et al.* (2008) who reported that the epithelium of proventricular glands shows a PAS-negative reaction for mucins, however, it's showed alcian positive secretion (Fig. 12A) with alcian blue-PAS stain and sulphated reaction (for both glands and cells lining the folds) after Aldehyde Fuchsin-Alcian blue stain (Fig. 12B). Totty (2002) reported that the strong acid mucin gives a PAS negative reaction while a variable reaction is achieved with Alcian blue stain.

The histochemical observations after Alcian blue-PAS reaction was performed for identification of neutral and acidic glycoconjugates in intestinal epithelium, most mucous cells were stained purple, indicating a combination of neutral and acid glycoconjugates, whereas some mucous cells were only

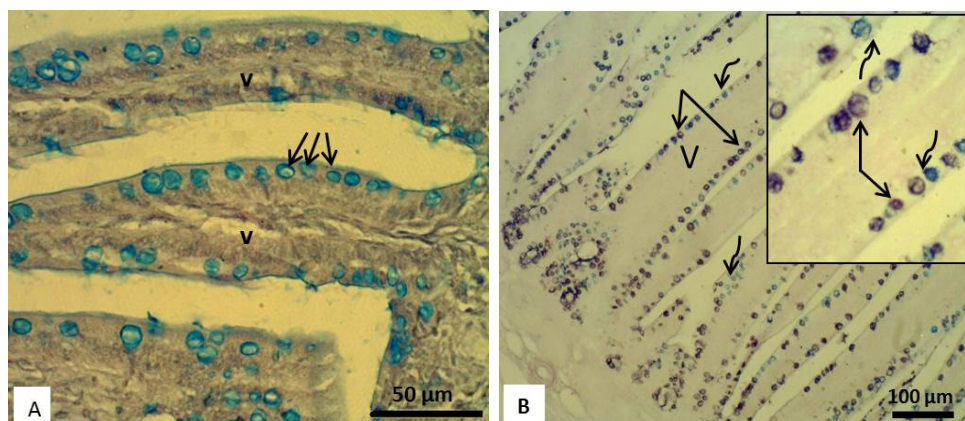


Fig. 13: The intestinal villi (v) at 21 day incubation showing, A) acid mucin reaction (arrows). Combined Alcian blue-PAS stain, B) Sulphatedmucin reaction (straight arrows) and carboxylatedmucin reaction (curved arrows). Aldehyde Fuchsin-Alcian blue stain

stained with blue (acidic glycoconjugates) (Fig. 13A), these results were constant for all intestinal segments and for both breeds all over the experiment.

For separating sulphated glycoconjugates from carboxylated one, the Aldehyde fuchsin-Alcian blue stain was performed, most mucous cells were strongly positive with Aldehyde fuchsin (sulphated glycoconjugates), although some mucous cells stained blue (carboxylated glycoconjugates) (Fig. 13B). Chikilian and De Speroni (1996) suggested that the glycoproteins play an important role not only in the protection of the intestinal epithelium but also in the initiation of the absorption process of some molecules. According to the findings of Ito (1964), these complex mucopolysaccharides in the small intestine could play some role in the hydrolytic process in the presence of enzymes involved in disaccharides digestion. Yamazaki *et al.* (1992) suggested that the acidic mucins play a fundamental role in protecting the cells against HCl during its passage and the layers of neutral mucin and acidic mucins in the surface coat is the safeguard against the HCl and digestive enzymes in the gastric lumen. However, the sulphated acid mucin in digestive tract may provide a resistance against bacteria (Kamble and Kamble, 2012). The conclusion of this study indicated that the intestinal development patterns were similar for both breeds but growth was more rapid in heavy line.

## REFERENCES

- Attia, H.F., 2008. Some morph histological studies on the proventriculus and small intestine of the chick during pre-hatching periods. *Minufiya Vet. J.*, 5(2): 441-453.
- Baddeley, A.J., H.J.G. Gundersen and L.M. Cruz-Orice, 1986. Estimation of surface area from vertical sections. *J. Microsc.*, 142: 259-276.
- Chikilian, M. and N.B. De Speroni, 1996. Comparative study of the digestive system of three species of Tinamou. I. *Crypturellus tataupa*, *Nothoprocta cinerascens* and *Nothura maculosa* (Aves: Tinamidae). *J. Morphol.*, 228: 77-88.
- Ding, B., A. Pirone, C. Lenzi, N. Xiaoming and A. Baglini, 2011. Histochemical features of the *Muscovy duck* small intestine during. *Tissue Cell.*, 43: 190-195.
- Dror, Y., I. Nir and Z. Nitsan, 1977. The relative growth of internal organs in light and heavy breeds. *Brit. Poultry Sci.*, 18: 493-496.
- Geyra, A., Z. Uni and D. Sklan, 2001. Enterocyte dynamics and mucosal development in the posthatch chick. *Poultry Sci.*, 80: 776-782.
- Humason, G.L., 1972. *Animal Tissue Techniques*. 3rd Edn., W.H. Freeman and Co., San Francisco, pp: 180-182.
- Iji, P.A., A. Saki and D.R. Tivey, 2001. Body and intestinal growth of broiler chicks on a commercial starter diet. 1. Intestinal weight and mucosal development. *Brit. Poultry Sci.*, 42: 505-513.
- Ito, S., 1964. The surface coating of enteric microvilli. *Anat. Rec.*, 148: 249-159.
- Kamble, N. and S. Kamble, 2012. Reactivity of digestive mucins in freshwater snail *Bellamya bengalensis* (1) against copper sulphate induction. *Asian J. Biol. Life Sci.*, 1: 208-212.
- Katanbaf, M.N., E.A. Dunnington and P.B. Siegel, 1988. Allomorphic relationships from hatching to 56 days in parental lines and F<sub>1</sub> crosses of chickens selected 27 generations for high or low body weight. *Growth Develop. Aging.*, 52: 11-22.
- Khalid, K.K., A.B.Z. Zuki, M.M. Noordin and S.M.A. Babjee, 2011. Histomorphology of the stomach, proventriculus and ventriculus of the red jungle fowl. *Anat. Histol. Embryol.*, 40: 226-233.
- Lilja, C., 1983. A comparative study of postnatal growth and organ development in some species of birds. *Growth*, 47: 317-339.

- Maneewan, B. and K. Yamauchi, 2003. Effects of semi-purified pellet diet on the chicken intestinal villus histology. *Poultry Sci.*, 40: 254-266.
- Marchini, C.F., P.L. Silva, M.R. Nascimento, M.E. Beletti, N.M. Silva and E.C. Guimarães, 2011. Body weight, intestinal morphometry and cell proliferation of broiler chickens submitted to cyclic heat stress. *Int. J. Poultry Sci.*, 10: 455-460.
- Martinez, A., J. Lopez and P. Sesma, 1993. Development of the diffuse endocrine cells in the chicken proventriculus. *Cell. Tissue Res.*, 271: 107-113.
- Mitchell, M.A. and M.W. Smith, 1991. The effects of genetic selection for increased growth rate on mucosal and muscle weights in the different regions of the small intestine of the domestic fowl (*Gallus domesticus*). *Comp. Biochem. Physiol.*, 99: 251-258.
- Mitjans, M., G. Barniol and R. Ferrer, 1997. Mucosal surface area in chicken small intestine during development. *Cell. Tissue Res.*, 290: 71-78.
- Murakami, H., Y. Akiba and M. Horiguchi, 1992. Growth and utilization of nutrients in newly hatched chicks with or without removal of residual yolk. *Growth Develop. Aging.*, 56: 75-84.
- Neutra, M.R. and J.F. Forstner, 1987. Gastrointestinal Mucous: Synthesis, Secretion and Function. In: Johanson, L.R. (Ed.), 2nd Edn., *Physiology of the Gastrointestinal Tract*. Raven Press, New York, pp: 975-1009.
- Nir, I., Z. Nitsan and M. Mahagna, 1993. Comparative growth and development of the digestive tract and of some enzymes in broiler and egg type chicks after hatching. *Brit. Poultry Sci.*, 34: 523-532.
- Nitsan, Z., G. Ben-Avraham, Z. Zoref and I. Nir, 1991. Growth and development of the digestive organs and some enzymes in broiler chicks after hatching. *Brit. Poultry Sci.*, 32: 515-523.
- Ogunkoya, Y.O. and R.D. Cook, 2009. Histomorphology of the proventriculus of three species of Australian passerines: *Lichmera indistincta*, *Zosterops lateralis* and *Poephila guttata*. *Anat. Histol. Embryol.*, 38: 246-253.
- Schaefer, C.M., C.M. Corsiglia, A. Mireles and E.A. Koutsos, 2006. Turkey breeder hen age affects growth and systemic and intestinal inflammatory responses in female poults examined at different ages post-hatch. *Poultry Sci.*, 85: 1755-1763.
- Selvan, P., S. Ushakumary and G. Ramesh, 2008. Studies on the histochemistry of the proventriculus and gizzard of post-hatch Guinea fowl (*Numida meleagris*). *Int. J. Poultry Sci.*, 7: 1112-1116.
- Shyla, P., P.A. Ommer and P. Lucy, 1992. Structure and post-natal development of the proventriculus in the duck. *Indian J. Poultry Sci.*, 27: 10-14.
- Sklan, D., 2001. Development of the digestive tract of poultry. *World. Poultry Sci.*, 57: 415-428.
- Smith, M.W., M.A. Mitchell and M.A. Peacock, 1990. Effects of genetic selection on growth rate and intestinal structure in the domestic fowl (*Gallus domesticus*). *Comp. Biochem. Physiol.*, 97: 57-63.
- Totty, B.A., 2002. Mucins. In: Bancroft, J.D. and M. Gamble, (Eds.), *Theory and Practice of Histological Techniques*. 5th Edn., Churchill Livingstone, New York, pp: 163-200.
- Uni, Z., Y. Noy and D. Sklan, 1996. Developmental parameters of the small intestine in heavy and light strain chicks pre and post-hatch. *Brit. Poultry Sci.*, 36: 63-71.
- Uni, Z., Y. Noy and D. Sklan, 1999. Posthatch development of small intestinal function in the poult. *Poultry Sci.*, 78: 215-222.
- Uni, Z., Y. Noy and D. Sklan, 2007. Development of the small intestine in heavy and light strain chicks before and after hatching. *Brit. Poultry Sci.*, 37: 63-71.
- Yamauchi, K. and P. Tarachai, 2000. Changes in intestinal villi, cell area and intracellular autophagic vacuoles related to intestinal function in chickens. *Brit. Poultry Sci.*, 41: 416-423.
- Yamazaki, Y., T. Ueda, Y. Kohli, N. Fujiki, Y. Imamura and M. Fukuda, 1992. Importance of acidic mucin secretions by foveolar and mucous neck cells of rat fundic mucosa as the defence mechanisms against HCl as revealed by fasting. *Eur. J. Histochem.*, 36: 161-76.