

Research Article

Toxicological Evaluation of Oral Administration of *Phoenix dactylifera* L. Fruit Extract on the Histology of the Liver and Kidney of Wistar Rats

¹Abel Nosereme Agbon, ²Helen Ochuko Kwanashie, ¹Wilson Oliver Hamman and ³S.J. Sambo

¹Department of Anatomy, Faculty of Medicine,

²Department of Pharmacology and Clinical Pharmacy, Faculty of Pharmaceutical Sciences,

³Department of Veterinary Pathology and Microbiology, Faculty of Veterinary Medicine,
Ahmadu Bello University, Zaria, Nigeria

Abstract: Various parts of *Phoenix dactylifera* (date palm) are used in traditional medicine to treat various disorders such as fever, abdominal troubles, etc., in different parts of the world. A preliminary phytochemical screening of the aqueous fruit extract of *Phoenix dactylifera* (AFPD) revealed the presence of alkaloids, tannins, saponins, flavonoids and carbohydrates. This study was designed to investigate the effects of oral administration of AFPD on the histology of the liver and kidney in Wistar rats. Thirty-nine Wistar rats were divided into two groups-control (three rats) and treatment (thirty-six rats). The animals in experimental group were further categorised for two phase study (eighteen rats divided into three groups; six rats/group for each phase). In the first phase, the three groups (A, B and C) were administered AFPD (10, 100 and 1000 mg/kg, oral, respectively). In the second phase, the three groups (D, E and F) were administered AFPD (1600, 2900 and 5000 mg/kg, oral, respectively). In both phases, after 24 h of AFPD administration, three rats of the six in each group were sacrificed and the other three sacrificed after 21 days. Histopathological examinations of liver and kidney sections of the experimental animals were compared with the control. No mortality or signs of toxicity was observed in the experimental animals upon administration of AFPD, even at doses as high as 5000 mg/kg, which was confirmed by mild pathological changes with remarkable recovery after 21 days. This result demonstrates that the LD₅₀ of AFPD is greater than 5000 mg/kg and is relatively safe.

Keywords: Histology, kidney, LD₅₀, liver, oral, *Phoenix dactylifera*, wistar rat

INTRODUCTION

Medicinal herbs are indispensable part of traditional medicine practiced all over the world due to easy access, low cost, least risk and low side effect profile (Sujith *et al.*, 2012). The cultural use of medicinal plants is wide spread in Africa (Ashafa and Olunu, 2011). The World Health Organization (WHO) estimates that up to 80% of the world's population relies on traditional medicinal system for some aspect of primary health care (Farnsworth *et al.*, 1985). The date palm (*Phoenix dactylifera* L.) is known to be one of the oldest cultivated trees in the world (Dowson, 1982; Abdulla, 2008). The date (*Phoenix dactylifera* L.) has been an important crop in arid and semiarid regions of the world. It has always played an important part in the economic and social lives of the people of these regions. The fruit of the date palm is well known as a staple food. It is composed of a fleshy pericarp and seed. Date palms have been cultivated in the Middle East over at least 6000 years ago (Copley *et al.*, 2001).

In fact, Muslims believe that "He who eats seven dates every morning will not be affected by poison or magic on the day heats them" (Miller *et al.*, 2003). Dates are widely used in traditional medicine for the treatment of various disorders e.g., memory disturbances, fever, inflammation, paralysis, loss of consciousness, nervous disorders (Nadkarni, 1976) and as a deterrent and astringent in intestinal troubles. It is also used in the treatment for sore throat, colds, bronchial asthma, to relieve fever, cystitis, gonorrhoea, edema, liver and abdominal troubles and to counteract alcohol intoxication (Barh and Mazumdar, 2008). Dates are a good source of energy, vitamins and a group of elements like phosphorus, iron, potassium and a significant amount of calcium (Abdel-Hafez *et al.*, 1980). Dates contain at least six vitamins including a small amount of vitamin C and vitamins B₁ (thiamine), B₂ (riboflavin), nicotinic acid (niacin) and vitamin A (Al-Shahib and Marshall, 2003). Recent studies indicate that the aqueous extracts of dates have potent antioxidant activity (Mansouri *et al.*, 2005). The

Corresponding Author: Abel Nosereme Agbon, Department of Anatomy, Faculty of Medicine, Ahmadu Bello University, Zaria, Nigeria

This work is licensed under a Creative Commons Attribution 4.0 International License (URL: <http://creativecommons.org/licenses/by/4.0/>).

antioxidant activity is attributed to the wide range of phenolic compounds in dates including p-coumaric, ferulic, sinapic acids, flavonoids and procyanidins (Gu *et al.*, 2003).

Considering the widespread use of this plant in the management of various ailments, this study was carried out to investigate the effect of aqueous fruit extract of *P. dactylifera* on the histology of the liver and kidney of Wistar rats.

MATERIALS AND METHODS

Plant sample collection and identification: *Phoenix dactylifera* fruits were obtained from a local Market in Zaria, Kaduna, Nigeria. Authenticated and deposited in the Herbarium Unit of the Department of Biological Sciences, Faculty of Sciences, Ahmadu Bello University, Zaria, Kaduna State, Nigeria with the Voucher Specimen Number of 7130.

Extraction of plant materials: Preparation of *Phoenix dactylifera* fruit extract was conducted in the Department of Pharmacognosy, Faculty of Pharmaceutical Sciences, Ahmadu Bello University, Zaria, Kaduna, Nigeria. The flesh of the dried *P. dactylifera* fruits were manually separated from the pits and pulverized into powder. About 650 g of the powder was soaked in 2 L of cold distil water. After 24 h, the solution was filtered and evaporated to dryness using H-H Digital Thermometer Water Bath (Mc Donald Scientific International-22050 Hz1.0A International Number) at 60°C. A yield of 21.28% of the extract was obtained.

Plant phytochemical screening: Phytochemical screening of aqueous fruit extract of *P. dactylifera* was conducted in the Department of Pharmacognosy, Faculty of Pharmaceutical Sciences, Ahmadu Bello University, Zaria, Kaduna, Nigeria. The method of Trease and Evans (1983) for phytochemical screening was adopted.

Experimental animals: Wistar rats of either sex (150-170 g), obtained from Pharmacology Animal House Center, Faculty of Pharmaceutical sciences, Ahmadu Bello University, Zaria, Kaduna, Nigeria, were housed in wired cages in the animal house of the Department of Human Anatomy, Faculty of Medicine, Ahmadu Bello University, Zaria and were acclimatized for two weeks prior to the commencement of the experiments. The animals were housed under standard laboratory condition, light and dark cycles of 12 h and were provided with standard rodent pellet diet and water *ad libitum*. The animals were categorized into control and treatment groups. Animals of treatment group were administered, in addition to feed and water, aqueous fruit extract of *P. dactylifera*.

Acute toxicity (LD₅₀) study: Acute toxicity study was carried out using a modified method of Lorke (1983). Thirty-nine Wistar rats were divided into two groups-control (three rats) and treatment (thirty-six rats). The animals in treatment group were further categorised for two phase study (eighteen rats for each phase). The animals in each phase were further sub-divided, randomly, into three groups of six rats each. In the first phase, the three groups (A, B and C) were administered aqueous fruit extract of *P. dactylifera* (10, 100 and 1000 mg/kg) by oral gavages respectively. In the second phase, the three groups (D, E and F) were administered aqueous fruit extract of *P. dactylifera* (1600, 2900 and 5000 mg/kg) by oral gavages, respectively. In both phases, after 24 h of aqueous fruit extract of *P. dactylifera* administration, three rats of the six in each group were randomly selected and sacrificed and the other three (rats) sacrificed after 21 days of aqueous fruit extract of *P. dactylifera* administration. The rats were observed for signs of toxicity and mortality for 24 h and then weighed daily for 21 days. Histopathological examinations of liver and kidney sections of the experimental animals were compared with the control.

Histopathology: The organs, liver and kidney, of all the animals were fixed in 10% buffered formalin in labeled bottles. Tissues were processed routinely and embedded in paraffin wax. Sections of 5 μ thickness were cut, stained with haematoxylin and eosin and examined under the light microscope.

Data analysis: Results obtained were analysed using the statistical soft ware, Statistical Package for Social Scientist (SPSS *version* 18.0) and Microsoft Office Excel 2007 for chart. Significant difference among means of the groups was determined using one way ANOVA with LSD post hoc test for significance. Paired *t*-test was also employed for the comparisons of means as appropriate. Values were considered significant when $p < 0.05$.

RESULTS

Phytochemical analysis: Phytochemical analysis of the aqueous fruit extract of *P. dactylifera* produced positive reaction for each of the following secondary metabolites: alkaloids, tannins, saponins, glycosides, cardiac glycoside, flavonoids and carbohydrates. However, a negative reaction was obtained for Anthraquinone.

Physical observation: During 21 days period of observation, after the administration of the aqueous extract of *P. dactylifera* fruit, all the experimental animals (Wistar rats) were observed to exhibit normal physical activity and significantly ($p < 0.01$) gained

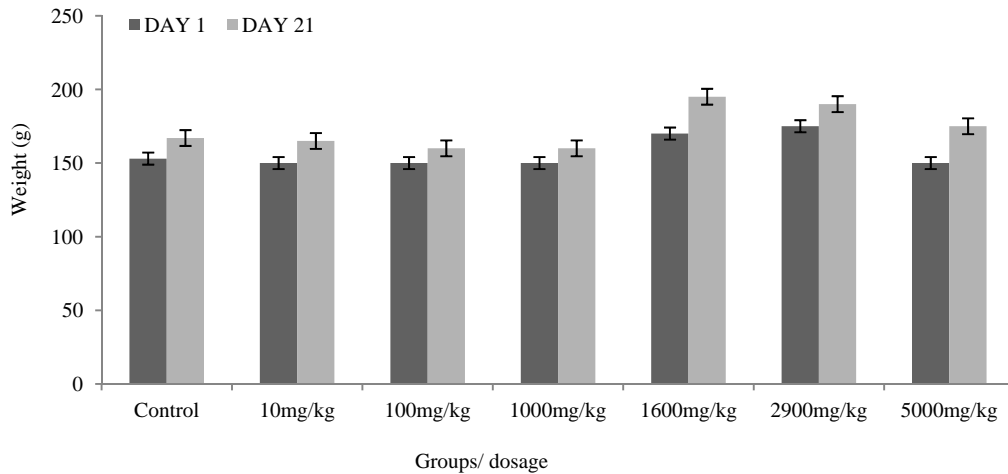


Fig. 1: Weight comparison of acute toxicity (LD₅₀) study Wistar rats orally administered aqueous fruit extract of *P. dactylifera* before (day 1) and after (day 21) the experimental period. One way ANOVA; LSD *post hoc* ($p < 0.000$) when compared with the control; Paired sample *t*- test for means ($p < 0.01$).

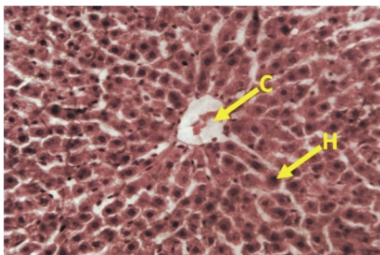


Fig. 2: Section of the liver of Wistar rat control (untreated) group showing normal histology of the liver: Central vein (C); Hepatocyte (H). H and E stain (Mag×250)

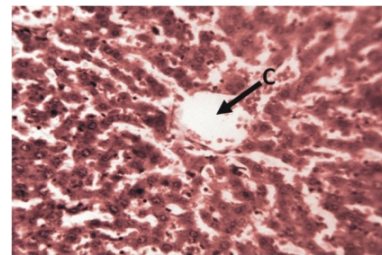


Fig. 4: Section of the liver of Wistar rat sacrificed 21 days after the administration of 10 mg/kg AFPD showing normal histoarchitecture of the liver: Central vein (C). H and E stain (Mag×250)

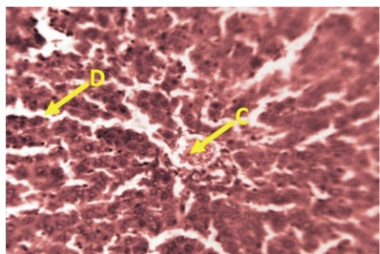


Fig. 3: Section of the liver of Wistar rat sacrificed 24 h after the administration of 10 mg/kg AFPD showing mild histoarchitectural distortion of the liver: Central vein (C); Sinusoidal dilatation (D). H and E stain (Mag×250).

weight when compared to their weights at the commencement ('day 1') of the experiment and, remarkably ($p < 0.000$) increased in weight when final ('day 21') weights were compared with that of the control (Fig. 1).

Acute toxicity (LD₅₀) test: There was no mortality observed in the experimental animals upon oral administration of aqueous fruit extract of *P. dactylifera*,

even at doses as high as 5000 mg/kg, signifying that the LD₅₀ was greater than 5000 mg/kg. Aqueous fruit extract of *P. dactylifera* did not produce any major clinical signs of toxicity, neither food nor water intake was found to be reduced in experimental animals during 21 days of observation period.

Histopathological examination: Histological examination of the liver and kidney organs were performed in both control and treatment groups. Normal histoarchitecture of the liver and kidney tissue sections were observed in the control. Histopathology of the experimental group revealed the following microscopic observations: the liver sections, after 24 h of aqueous fruit extract of *P. dactylifera* administration, showed mild histoarchitectural distortion such as sinusoidal dilatation and congestion, especially in the 10 and 1600 mg/kg aqueous fruit extract of *P. dactylifera* treated groups, which was normalized 21 days later. The kidney sections showed normal renal corpuscles and renal tubules. Pathological examination of tissues indicated that there were no detectable abnormalities

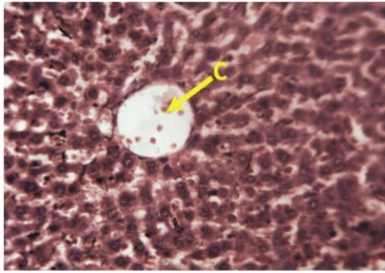


Fig. 5: Section of the liver of Wistar rat sacrificed 24 h after the administration of 100 mg/kg AFPD showing normal histoarchitecture of the liver: Central vein (C). H and E stain (Mag×250)

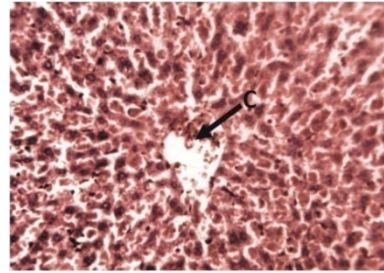


Fig. 9: Section of the liver of Wistar rat sacrificed 24 h after the administration of 1600 mg/kg AFPD showing mild histoarchitecture distortion of the liver: Central vein congestion (C). H and E stain (Mag×250)

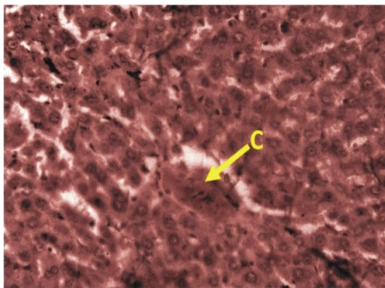


Fig. 6: Section of the liver of Wistar rat sacrificed 21 days after the administration of 100 mg/kg AFPD showing normal histoarchitecture of the liver: Central vein (C). H and E stain (Mag×250)

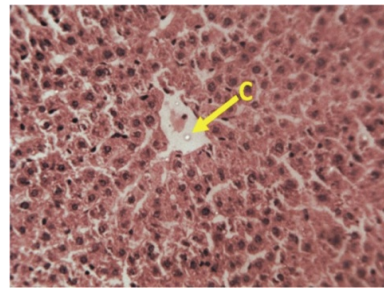


Fig. 10: Section of the liver of Wistar rat sacrificed 21 days after the administration of 1600 mg/kg AFPD showing normal histoarchitecture of the liver: Central vein (C). H and E stain (Mag×250)

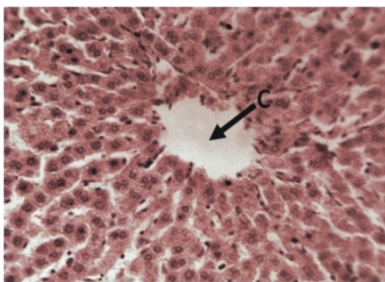


Fig. 7: Section of the liver of Wistar rat sacrificed 24 h after the administration of 1000 mg/kg AFPD showing normal histoarchitecture of the liver: Central vein (C). H and E stain (Mag×250)

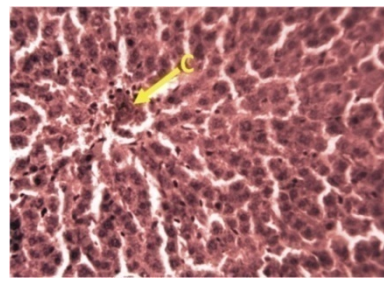


Fig. 11: Section of the liver of Wistar rat sacrificed 24 h after the administration of 2900 mg/kg AFPD showing normal histoarchitecture of the liver: Central vein (C). H and E stain (Mag×250)

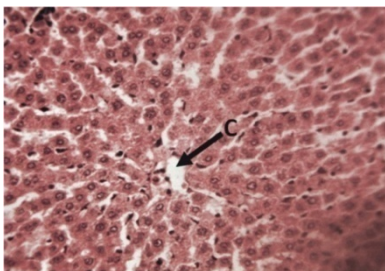


Fig. 8: Section of the liver of Wistar rat sacrificed 21 days after the administration of 1000 mg/kg AFPD showing normal histoarchitecture of the liver: Central vein (C). H and E stain (Mag×250)

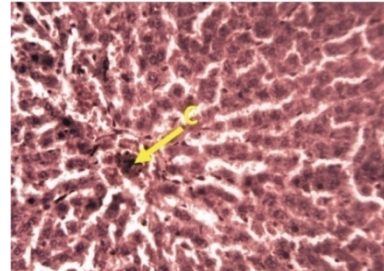


Fig. 12: Section of the liver of Wistar rat sacrificed 21 days after the administration of 2900 mg/kg AFPD showing normal histoarchitecture of the liver: Central vein (C). H and E stain (Mag×250)

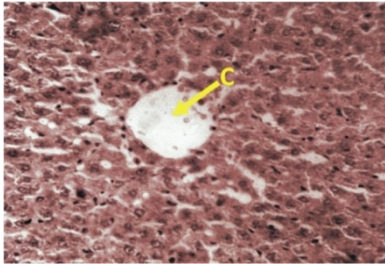


Fig. 13: Section of the liver of Wistar rat sacrificed 24 h after the administration of 5000 mg/kg AFPD showing normal histoarchitecture of the liver: Central vein (C). H and E stain (Mag×250)

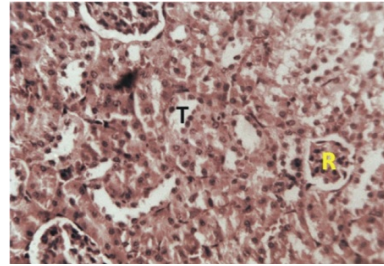


Fig. 17: Section of the kidney of Wistar rat sacrificed 21 days after the administration of 10 mg/kg AFPD showing normal histoarchitecture of the kidney: Renal corpuscle (R); Renal tubule (T). H and E stain (Mag×250)

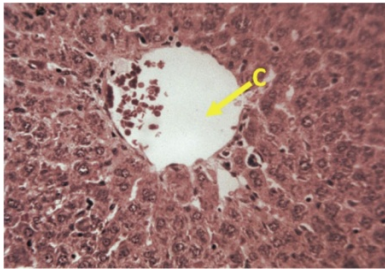


Fig. 14: Section of the liver of Wistar rat sacrificed 21 days after the administration of 5000 mg/kg AFPD showing normal histoarchitecture of the liver: Central vein (C). H and E stain (Mag×250)

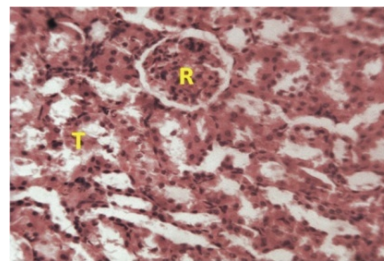


Fig. 18: Section of the kidney of Wistar rat sacrificed 24 h after the administration of 100 mg/kg AFPD showing normal histoarchitecture of the kidney: Renal corpuscle (R); Renal tubule (T). H and E stain (Mag×250)

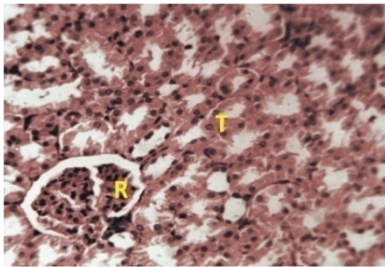


Fig. 15: Section of the kidney of Wistar rat control (untreated) group showing normal histology of the kidney: Renal corpuscle (R); Renal tubule (T). H and E stain (Mag×250)

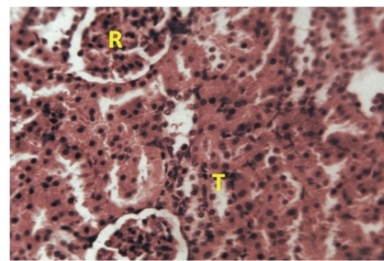


Fig. 19: Section of the kidney of Wistar rat sacrificed 21 days after the administration of 100 mg/kg AFPD showing normal histoarchitecture of the kidney: Renal corpuscle (R); Renal tubule (T). H and E stain (Mag×250)

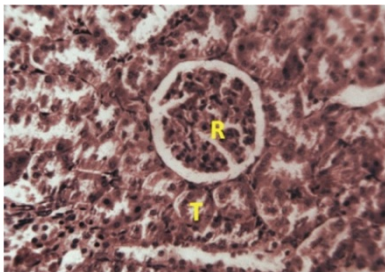


Fig. 16: Section of the kidney of Wistar rat sacrificed 24 h after the administration of 10 mg/kg AFPD showing normal histoarchitecture of the kidney: Renal corpuscle (R); Renal tubule (T). H and E stain (Mag×250)

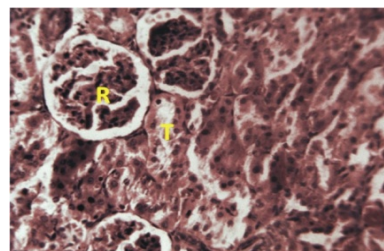


Fig. 20: Section of the kidney of Wistar rat sacrificed 24 h after the administration of 1000 mg/kg AFPD showing normal histoarchitecture of the kidney: Renal corpuscle (R); Renal tubule (T). H and E stain (Mag×250)

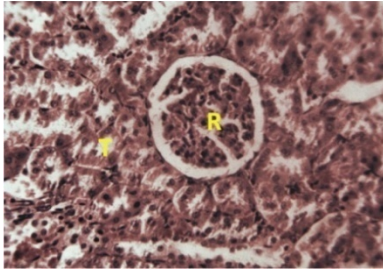


Fig. 21: Section of the kidney of Wistar rat sacrificed 21 days after the administration of 1000 mg/kg AFPD showing normal histoarchitecture of the kidney: Renal corpuscle (R); Renal tubule (T). H and E stain (Mag×250)

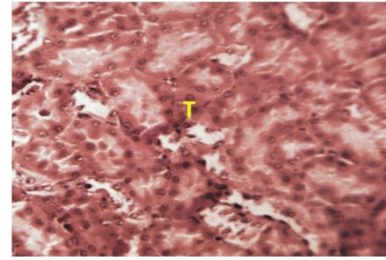


Fig. 25: Section of the kidney of Wistar rat sacrificed 21 days after the administration of 2900 mg/kg AFPD showing normal histoarchitecture of the kidney: Renal corpuscle (R); Renal tubule (T). H and E stain (Mag×250)

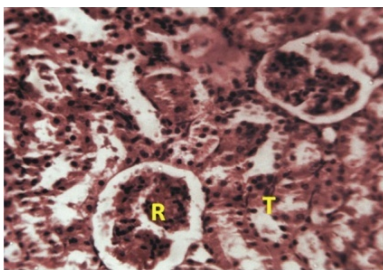


Fig. 22: Section of the kidney of Wistar rat sacrificed 24 h after the administration of 1600 mg/kg AFPD showing normal histoarchitecture of the kidney: Renal corpuscle (R); Renal tubule (T). H and E stain (Mag×250)

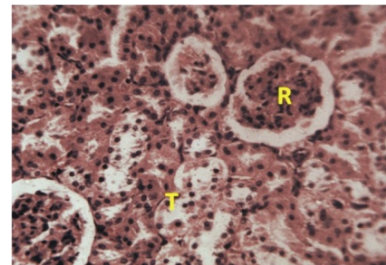


Fig. 26: Section of the kidney of Wistar rat sacrificed 24 h after the administration of 5000 mg/kg AFPD showing normal histoarchitecture of the kidney: Renal corpuscle (R); Renal tubule (T). H and E stain (Mag×250)

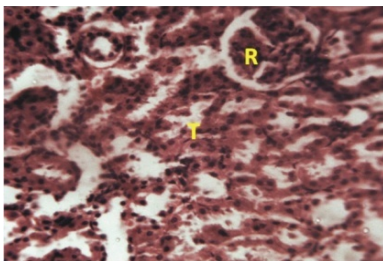


Fig. 23: Section of the kidney of Wistar rat sacrificed 21 days after the administration of 1600 mg/kg AFPD showing normal histoarchitecture of the kidney: Renal corpuscle (R); Renal tubule (T). H and E stain (Mag×250)

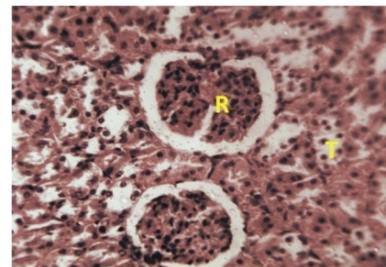


Fig. 27: Section of the kidney of Wistar rat sacrificed 21 days after the administration of 5000 mg/kg AFPD showing normal histoarchitecture of the kidney: Renal corpuscle (R); Renal tubule (T). H and E stain (Mag×250)

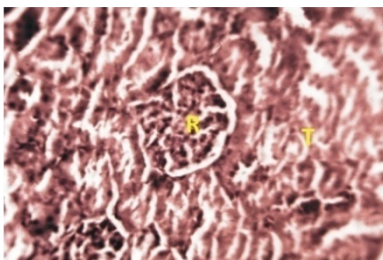


Fig. 24: Section of the kidney of Wistar rat sacrificed 24 h after the administration of 2900 mg/kg AFPD showing normal histoarchitecture of the kidney: Renal corpuscle (R); Renal tubule (T). H and E stain (Mag×250)

after 24 h and 21 days of aqueous fruit extract of *P. dactylifera* administration (Fig. 2 to 27).

DISCUSSION

Phytochemical screening of aqueous fruit extract of *P. dactylifera* in this study, revealed the presence of alkaloids, glycosides, cardiac glycoside, tannins, saponins, flavonoids and carbohydrates which have all been reported to possess antioxidant and disease preventing activities (Tella and Ojo, 2005; Toma *et al.*, 2009; Manalisha and Chandra, 2012). This result is in accordance to the reports of Dowson (1982) and Biglari

et al. (2008) on whole plant (*P. dactylifera*) and Ammar *et al.* (2009) on seed of the plant phytochemicals.

Result from the body weights of the treated groups suggests that aqueous fruit extract of *P. dactylifera* administration had no effect on the normal growth of the Wistar rats (Sujith *et al.*, 2012) change in body weight have been used as an indicator of adverse effect of drugs and chemicals (Mukinda and Syce, 2007).

The extract was well tolerated by the animals when administered orally, no sign of acute toxicity like restlessness or seizures were observed over the period of observation. The absence of death in the groups of Wistar rats treated with the extract, even at 5000 mg/kg body weight suggests that the extract is practically non-toxic acutely and is safe in Wistar rats (Matsumura, 1975; Tijani *et al.*, 2008). Histological analysis of internal organs, liver and kidney, revealed that there were no treatment related histopathological findings following oral administration of aqueous fruit extract of *P. dactylifera* after 24 h and 21 days. This result further supports the non-toxic effect of the extract in Wistar rats.

CONCLUSION

No mortality or signs of toxicity was observed in the experimental animals upon administration of aqueous fruit extract of *P. dactylifera*, even at doses as high as 5000 mg/kg, which was confirmed by mild pathological changes in the liver tissue sections with remarkable recovery after 21 days. This result demonstrates that the LD₅₀ of aqueous fruit extract of *P. dactylifera* is greater than 5000 mg/kg and is relatively safe and is a potential source of useful drug. Further studies are ongoing to investigate the effect of other solvents extracts of *P. dactylifera* on Wistar rats.

ACKNOWLEDGMENT

I wish to acknowledge Mr. Peter S. Akpulu and Mr. Jibrin Danladi for technical support and the Department of Human Anatomy, Faculty of Medicine, Ahmadu Bello University, Zaria for providing the facilities to conduct this study.

REFERENCES

- Abdel-Hafez, G.M., A. Fouad-Shalaby and I. Akhal, 1980. Chemical composition of 15 varieties of dates grown in Saudi Arabia. Proceeding of 4th Symposium on Biological Aspects of Saudi Arabia, pp: 89-91.
- Abdulla, Y.A., 2008. Possible anti-diarrhoeal effect of the date palm (*Phoenix dactylifera* L) spathe aqueous extract in rats. Sci. J. King Faisal Univ., Basic Appl. Sci., 9(1 1429H): 131-137.
- Al-Shahib, W. and R.J. Marshall, 2003. The fruit of the date palm: Its possible use as the best food for the future. Int. J. Food Sci. Nutr., 54: 247-259.
- Ammar, N.M., S.Y. Al-Okbi, D.A. Mohamed and L.T. Abou El-Kassem, 2009. Antioxidant and estrogen like activity of the seed of *Phoenix dactylifera* L. palm growing in Egyptian oases. Rep. Opinion, 1(3): 1-8.
- Ashafa, A.O.T and O.O. Olunu, 2011. Toxicological evaluation of ethanolic root extract of *Morinda lucida* (L.) Benth. (Rubiaceae) in male wistar rats. J. Nat. Pharm., 2(2): 108-114.
- Barh, D. and B.C. Mazumdar, 2008. Comparative nutritive values of palm saps before and after their partial fermentation and effective use of wild date (*Phoenix sylvestris* Roxb.) sap in treatment of anemia. Res. J. Med. Sci., 3: 173-176.
- Biglari, F., F.M.A. Abbas and M.E. Azhar, 2008. Antioxidant activity and phenolic content of various date palms (*Phoenix dactylifera*) fruits from Iran. Food Chem., 107: 1636-1641.
- Copley, M.S., P.J. Rose, A. Clampham, D.N. Edwards, M.C. Horton and R.P. Evershed, 2001. Detection of palm fruit lipids in archaeological pottery from Qasr Ibrim, Egyptian Nubia. Proceedings of the Royal Society, London, 268: 593-597.
- Dowson, V.H.W., 1982. Date Production and Protection. FAO Plant Production and Protection Paper No. 35. Food and Agriculture Organization of the United Nations, Rome, Italy.
- Farnsworth, N.R., O.O. Akerele, A.S. Bingel, D.D. Soejarta and Z. Eno, 1985. Medicinal plants in therapy. Bull. World Health Organ., 63: 965-981.
- Gu, L., M.A. Kelm, J.F. Hammerstone, G. Beecher, J. Holden, D. Haytowitz and R.L. Prior, 2003. Screening of foods containing proanthocyanidins and their structural characterization using LCMS/MS and thiolytic degradation. J. Agr. Food Chem., 51: 7513-7521.
- Lorke, D., 1983. A New approach to practical acute toxicity testing. Arch. Toxicol., 54: 275-287.
- Manalisha, D. and K.J. Chandra, 2012. Preliminary phytochemical analysis and acute oral toxicity study of *Mucuna pruriens* Linn. in albino mice. Int. Res. J. Pharm., 3(2): 181-183.
- Mansouri, A., G. Embarek, E. Kokkalou and P. Kefalas, 2005. Phenolic profile and antioxidant activity of the Algerian ripe date palm fruit (*Phoenix dactylifera*). Food Chem., 89: 411-420.
- Matsumura, F., 1975. Toxicology of Insecticides. Plenum Press, New York, pp: 24-26.
- Miller, C.J., E.V. Dunn and I.B. Hashim, 2003. The glycaemic index of dates and date/yoghurt mixed meals. Are dates the candy that grows on trees? Eur. J. Clin. Nutr., 57: 427-430.
- Mukinda, J.T. and J.A. Syce, 2007. Acute and chronic toxicity of the aqueous extract of *Artemisia afra* in rodents. J. Ethnopharmacol., 112: 138-144.

- Nadkarni, K.M., 1976. *Indian Materia Medica*. 13th Edn., Vol. 1, Popular Prakashan, Mumbai, 1: 1175-1181.
- Sujith, K., R. Darwin and V. Suba, 2012. Toxicological evaluation of ethanolic extract of *Anacyclus pyrethrum* albino wistar rats. *Asian Pac. J. Trop. Dis.*, 2(6): 437-441.
- Tella, I.O. and O.O. Ojo, 2005. Hepatoprotective effects of *Azadiractha indica*, *Tamarindus indica* and *Eucalyptus camaldulensis* on paracetamol induced-hepatotoxicity in rats. *J. Sustain. Dev. Agric. Environ.*, (In press).
- Tijani, A.Y., M.O. Uguru and O.A Salawu, 2008. Anti-pyretic, anti-inflammatory and anti-diarrhoeal properties of *Faidherbia albida* in rats. *Afr. J. Biotechnol.*, 7(6): 696-700.
- Toma, I., Y. Karumi and M.A. Geidam, 2009. Phytochemical screening and toxicity studies of the aqueous extract of the pods pulp of *Cassia sieberiana* DC. (*Cassia Kotchiana Oliv.*). *Afr. J. Pure Appl. Chem.*, 3(2): 026-030.
- Trease, G.E and E.C. Evans, 1983. *Pharmacognosy*. 12th Edn., Bailliere Tindal, London, pp: 185.