

Research Article

Image Segmentation Technology Application in Diabetic Retinopathy Analysis

¹Jin-Yuan Wu, ²Guo-Dong You, ¹Feng-Yuan Sun, ¹Dong-Run Tang and ¹Tong Wu

¹Department of Ophthalmology, Tianjin First Center Hospital, Tianjin, China

²College of Electronic Information and Automation, Tianjin University of Science and Technology, Tianjin, China

Abstract: Selection of clinical image of the fundus and fundus fluoresce in angiography (fundus fluoresce in angiography, FFA) image as the research object, using image segmentation method on diabetic retinopathy (Diabetic Retinopathy, DR) vascular processing and analysis, in order to improve clinical diagnostic accuracy and efficiency. The experimental results show that image processing and analysis methods for normal retinal images and image segmentation are relatively complete vascular lesions and the image of the fundus and fundus fluoresce in angiography (Fundus Fluoresce in Angiography FFA) images as compared to the more detailed and clear, precision is improved obviously. As the eye fundus blood vessel lesions in the early discovery, early diagnosis and further therapy provides a new theoretical basis.

Keywords: Diabetes, image diagnosis, retinal vascular, segmentation

INTRODUCTION

As reference (Li, 2007), the number of world's adult diabetic reaches two hundred forty-six million; this number will be more than three hundred and eighty million as expected until 2025. And the number for Chinese diabetic has reached forty million, which takes up 16% of the world's diabetic and ranks the second for the prevalence. With the deepening of diabetes researches, medical scientists have found that diabetic retinopathy turning into the most serious ocular micro vascular complications is one of the world's major causes of blindness and its incidence is related to diabetes' duration, genetic factors and glycemic control conditions. World Health Organization reports that, the risk of diabetic blindness is 25 times higher than the non-diabetic patients. Medical experts point out that through the early diagnosis and general check for fundus' periodicity, almost 90% of the blindness or visual impairment caused by diabetes can be avoided completely (Li, 2007).

Diabetic Retinopathy (DR) is one of the serious complications of diabetes (Li, 2007). Now, we mainly rely on fundus image and fundus fluoresces in angiography images to do clinical diagnosis and staging (Zhang, 1997; Wang *et al.*, 2005, 2006; Wang and Li, 2003; Zhang and Liu, 2002). Image Processing is an interdisciplinary technology which contains math, computer and information technology (Yao and Chen, 2010; Zhang, 2005; Yang *et al.*, 2005; Li, 2009) and analyzing and processing on retinal blood vessels can help the qualitative analysis and quantitative

measurement for retinopathy and distinguish the normal and abnormal ones, thus, it increased the advantages of fundus examination greatly.

Combined with a group of patients with diabetic retinopathy fundus and Fundus Fluoresce in Angiography (FFA) images for Tianjin First Central Hospital's ophthalmology, this study uses the retinal images as the objects and combines information and medical technology and uses modern Image Processing Technology to process and analyze fundus image and to increase the efficiency and precision of clinical diagnosis, which provides further theoretical foundation for the further treatment of diabetic retinopathy.

PROCESSING METHOD OF DIABETIC RETINOPATHY VASCULAR IMAGE

Literature (Chaudhuri *et al.*, 1989) showed that vessel width gradually changed, curvature was small and the Gauss curve to approximate expression for the cross section of intensity profile in the retinal fundus images in. This study used the matched filtering method of the literature (Chaudhuri *et al.*, 1989) and the vascular segment for monospaced straight segments, the retinal vessel image to enhance the pretreatment to enhance vascular image effect.

The main vessel segmentation: After the retinal vascular images are enhanced and pretreated, its main blood vessel must be extracted. In this study, the method based on the optimal entropy (Huang and Zhang, 2006) is used to extract enhanced better main

blood vessels in retinal images. And the image gray value range is set to $\{0, 1, 1, L-1\}$, segmentation threshold is set to t , the target O and background B obey different probability distribution, i.e:

$$O: \frac{P_0}{P_t}, \frac{P_1}{P_t}, \dots, \frac{P_t}{P_t} \quad (1)$$

$$B: \frac{P_{t+1}}{1-P_t}, \frac{P_{t+2}}{1-P_t}, \dots, \frac{P_{L-1}}{1-P_t} \quad (2)$$

Type of, $P_t = \sum_{i=0}^t p_i$, $p = n_i/(N \times M)$, the pixel number of the gray value i is n_i , the size of the image is $N \times M$.

By Shannon entropy concept, the probability distribution related to entropy of goals O and background B are respectively defined:

$$H(O) = \ln P_t + \frac{H_t}{P_t} \quad (3)$$

$$H(B) = \ln(1-P_t) + \frac{H_{L-1}-H_t}{1-P_t} \quad (4)$$

Type of, $H_t = -\sum_{i=1}^t (p_i \ln p_i)$, $H_{L-1} = -\sum_{i=1}^{L-1} (p_i \ln p_i)$, according to Kapur guidelines for the definition of function:

$$\psi(t) = H(O) + H(B) = \ln P_t(1-P_t) + \frac{H_t}{P_t} + \frac{H_{L-1}-H_t}{1-P_t} \quad (5)$$

When $\psi(t)$ achieves to the maximum value, the gray level t is the optimal threshold value t^* i.e., $t^* = \max_{0 \leq t < L-1} \psi(t)$

Transition region extractionL: On the retinal vessel image enhancement, small diameter or low-contrast vascular changes are small and the gray changes basically in the target O between and background B. If using the traditional global thresholding method, it could be recognized as background (Otsu, 1979; Chaudhuri *et al.*, 1989; Li, 2009) and they usually will not be segmented. In view of this, the double threshold transition region extraction method combines a distributed genetic algorithm with the Otsu method and uses its resistance to early, fast convergence and Otsu optimal threshold extraction ability for the enhanced vascular image segmentation, segmentation of the final vessel (Otsu, 1979; Chaudhuri *et al.*, 1989; Li *et al.*, 2009).

- **Otsu dual threshold method:** Assuming a threshold value for t_1 and t_2 and the image gray value is set for the background C_0 , transition zone C_1 and target C_2 . They correspond to the probability

of the occurrence of Otsu (1979) can be expressed as:

$$W_0 = \Pr(C_0) = \sum_{i=0}^{t_1} p_i \quad (6)$$

$$W_1 = \Pr(C_1) = \sum_{i=t_1+1}^{t_2} p_i \quad (7)$$

$$W_2 = \Pr(C_2) = \sum_{i=t_2+1}^{L-1} p_i = 1 - W_0 - W_1 \quad (8)$$

And the corresponding average gray value of U_0 , U_1 , U_2 , respectively are:

$$U_0 = \sum_{i=0}^{t_1} \frac{ip_i}{W_0} \quad (9)$$

$$U_1 = \sum_{i=t_1+1}^{t_2} \frac{ip_i}{W_1} \quad (10)$$

$$U_2 = \sum_{i=t_2+1}^{L-1} \frac{ip_i}{W_2} = \frac{U_T - W_0 U_0 - W_1 U_1}{W_2} \quad (11)$$

U_T = The overall mean gray value and the

$$U_T = \sum_{i=0}^{L-1} i p_i$$

Cluster variance among C_0 , C_1 and C_2 can be expressed as:

$$\sigma^B(t_1, t_2) = W_0(U_0 - U_T)^2 + W_1(U_1 - U_T)^2 + W_2(U_2 - U_T)^2 \quad (12)$$

When it reached the maximum value, the threshold t_1 and t_2 are the demand for the optimal segmentation threshold, expressed as T_1 and T_2 :

$$\sigma^B(t_1, t_2) = \text{Arg} \left\{ \max_{1 \leq t_1 < t_2 < L-1} [\sigma^B(t_1, t_2)] \right\} \quad (13)$$

The pixel between T_1 and T_2 in image gray value is to extract the transition zone.

- **Transition region extraction based on distributed genetic algorithm:** Distributed genetic algorithm in parallel genetic algorithm divides population into several group, at the same time independently operates genetic. Compared with the simple genetic algorithm, it can overcome the “early” and quickly find the global optimal solution (Fan *et al.*, 2002). Migration strategy of parallel genetic algorithm is the introduction of a new genetic operator. It makes the population progeny carrying other populations of excellent individual

through the migrates method. One can keep the population diversity in genetic inbreeding coefficient, avoid harm; on the other hand can accelerate better individual in the group communication, improve the convergence speed and accuracy, compared with single population need only a small amount of calculation can reach the same performance (Fan *et al.*, 2002).

Distributed genetic algorithm based on migration strategy is Otsu transition region extraction. This is actually to find the optimal threshold in Otsu T_1 and T_2 by distributed genetic algorithm multi population evolution. The algorithm combining process and implementation steps are as follows:

- **To initialize the population:** Because Otsu solving two parameters are the threshold of t_1 and t_2 and its range for the image gray 0~255 integers, the initial population uses binary coding mode, with randomly generated 16 binary string to initialize the chromosome, among the top 8 t_1 , the after 8 t_2 . In the evolutionary process, population number N_p remained unchanged, in each population size (chromosome number) N_c remain unchanged.
- **Calculating the degree of adaptation:** Fitness is used to assess each chromosome performance. This chromosome representation is to be solving threshold t_1 and t_2 . The t_1 and t_2 in Otsu are selected by calculating the maximum between-cluster variance to achieve, while taking into account the between-cluster variance constant $\sigma B(t_1, t_2)$ is non-negative, so the construction of fitness function is $f(i) = c \sigma B(t_1, t_2)$ is. Where C is any normal number in $c = 1$, to ensure the adaptation degree $f(i)$ constant positive. Based on computational efficiency considerations, it is taken the smallest positive integer 1. So Otsu transition region will extract into a distributed genetic algorithm which has the largest fitness chromosome search.
- **Genetic manipulation for each population alone:** Genetic operators includes selection, crossover and mutation. Every group selection operation uses roulette wheel method selection of offspring; crossover and mutation operations use two-point crossover and two variants. Intersection and variation points randomly generate and were located in chromosome 8 before and after 8. Cross rate P_c chooses greater probability in favor of population evolution, mutation rate of P_m selects small probability in favor of the best individual preservation.
- Determine the migration condition, if satisfied, population each other interactive migration. Migration strategy for a variety of group selection

the best individual is sent to other populations and receiving the other populations of excellent individual and their individual fitness arrangement, out of the worst individual. Migration frequency for each evolutionary generation migration time.

- Determine the termination rule, if satisfied, then the program is terminated, or turn to step (2) and the beginning of the next generation. Termination rules for a given one of the largest number of N_g , algorithm evolving algebra to N_g termination.

Vascular regional characteristics: Literature (Mendonca and Campilho, 2006; Ricci and Perfetti, 2007) demonstrated based on the optimal entropy segmentation of vascular mainly vascular enhancement image after the main blood vessels, for small vessels and not very well separated and extracted from the transition zone not only contains many small vessels and peripheral blood vessels, but also contains part of the background noise of debris. In order to make the transition zone of vascular and noise pieces well apart, the main blood vessels as the entire vascular network trunk, through regional connectivity judgment, namely when the transition zone around 3×3 the pixel neighborhood window has a corresponding pixel in the main vascular images mainly vascular pixel, the pixel judging as the blood vessels, so the cycle to traverse the entire image transition region, until the decision is completed. In this way, the transition zone is located in the main blood vessels around the small vessels of the decision and a transition zone in separate and the main blood vessels without connectivity noise debris was cleared.

THE EXPERIMENTAL RESULTS AND ANALYSIS

This group of patients ages from 40 to 70, 30 of them are diabetic retinopathy patients with 60 eyes, 16 males and 14 females and the history of diabetes for them are more than 10 years, after using international standard vision chart to check the corrected visual acuity of patients, their visual acuity was 0.1~1.0, the average visual acuity was 0.50. The patients all have fundus image and Fundus Fluoresce in Angiography (FFA) images. The Topcon.TRC.50DX fundus camera system was used. Use currently experts-recommended international clinical diabetic retinopathy classification to classify the retinopathy. Fundus image properties are used in the experiment shown in Table 1.

We use Pentium-IV computer in the experiment with the CPU of 2.600 GHz and the Memory of 512M along with MATLAB simulation software to divide and extract the retinal vascular from 120 clinical acquired fundus images and FFA images.

Table 1: The property of clinical images used in the experiment

Disease stage	The number of clinical images (Fundus+FFA image)	Bits	Resolution
No retinopathy	8+8	1024 × 680	24 bits
Mild non-proliferative diabetic retinopathy	15+15		
Moderate non-proliferative diabetic retinopathy	19+19		
Severe non-proliferative diabetic retinopathy	15+15		
Proliferative diabetic retinopathy	3+3		

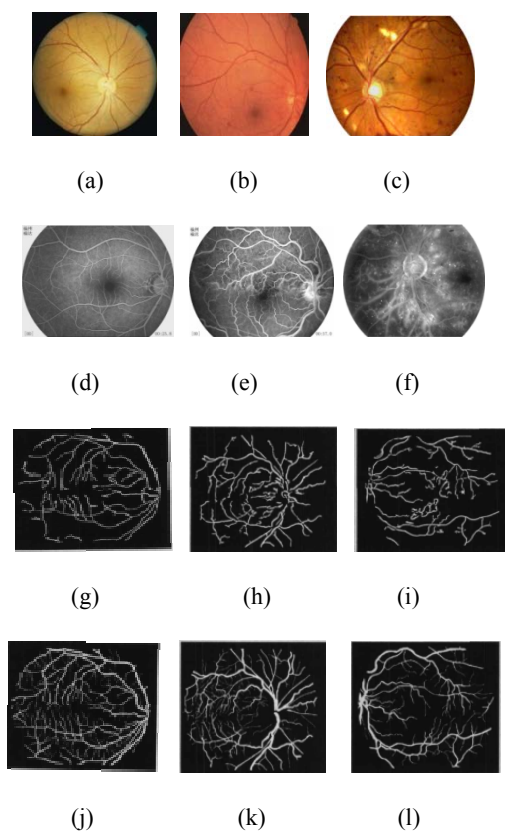


Fig. 1: Comparison of retinal vessel image processing results

Figure 1 is the Comparison of a group of clinical retinal image and renderings which processed with Image Segmentation Technology. The first line is a colorful fundus image, the second line is a fundus fluoresce in angiography image, the third line is traditional Hoover division image (Hoover *et al.*, 2000), the fourth line is retinal blood vessels segmentation rendering based on prior knowledge random walk mode and the first column is normal retinal image, the second and the third column are mild and severe non-proliferative diabetic retinopathy images separately.

Observed from the first and second line: in normal fundus fluorescein angiogram (d), the filling of optic nerve and retinal vascular is normal; in mild non-proliferative diabetic retinopathy images (b), we can see micro-aneurysms or small bleeding points and we can see the widely distributed high fluorescence point capillary hemangioma of its fluoresce in angiography image (e); in severe non-proliferative diabetic retinopathy (c), we can see flake bleeding, hard

exudates and cotton wool spots and in its fluoresce in angiography images (f), more diffuse retinal capillary hemangiomas display fluorescent spots, which diffuse the bleed and mask fluorescence and large capillary was not filled to display low fluorescence.

Comparing the clinical retinal image in Fig. 1 and the image we got with retinal blood vessels segmentation method in this study (Staal *et al.*, 2004; Soares *et al.*, 2006; Chanwimaluang and Guoliang, 2003; Benson and Hong, 2008), we see that the image processing and segmentation method in this study is complete for the segmentation for normal retinal image and vascular disease image and can divide most of the small blood vessels well, while these vessels, no matter in the clinical retinal image or in the result of Hoover segment, cannot be displayed or divided. In the meantime, vascular connectivity is good, we use Hoover division method in the third line to divide broken vessels and connect them in the fourth line's result well. Besides, vascular segmentation method still has strong robustness (robustness means that the control system's maintaining certain performances under certain characteristics such as structure and size) for retinal image with lesions and it has better effects for the lesion areas vessels, especially in the second line (e, f) clinical angiograms' conditions of retinal hemorrhage and cotton wool spots and the condition of poor show of vascular lesions. Comparing the image segmentation results (k, l) with normal fundus standard image (j), we see that the number of wrong segments is small, while the Hoover vessel segment method contains more mistakes.

For the two conditions or natural states that may get confused, the experimenter, professional diagnostics workers or forecasters need to make a meticulous judgment or a quantitative method for accurate decision-making which is an effective method for the evaluation of diagnostic methods. In order to check the effectiveness of the process and analysis for diabetic retinopathy blood vessels based on prior knowledge random walk model's retinal blood vessel segmentation, we use ROC (Receiver Opening Characteristic curve) to analyze the division precision, set vertical axis as sensitivity (true positive rate%), horizontal axis for the specific (fake positive rate%), then get the ROC shown as Fig. 2. From Fig. 2 we know that fake positive is approximately the same, the segment method in this study greatly improved vascular

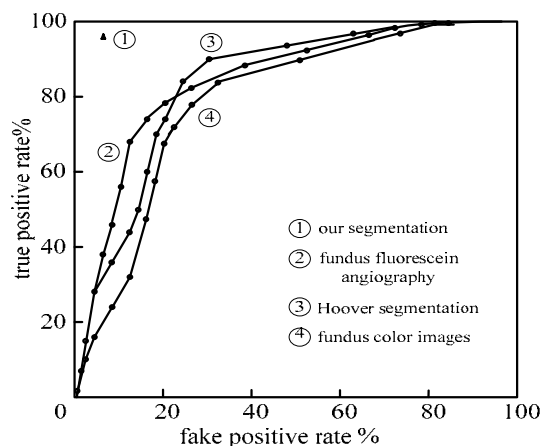


Fig. 2: Comparison of different methods using ROC curve

Table 2: Comparing data for the accuracy of different processing methods

Method	Accuracy		
	P_{vessel}	$P_{background}$	P_{all}
Hoover	0.0700	0.8563	0.9265
Fundus image	0.0825	0.8476	0.9297
This method	0.0835	0.8460	0.9293
FFA image	0.0943	0.8511	0.9375

segmentation true positive when compared with Hoover segmentation, color images of fundus and fundus fluoresce in angiography images. Thus, when the segmentation error probability is the same, the segment method in this study can divide more real vessels. In addition, seen from Fig. 2, the method in this study's AUC approaches 1 more when compared with other segment methods, which further shows that this segment method improved the process and analysis property for retinal blood vessel segmentation. Use the above method to make image segment precision test for 120 clinical retinal vessels, we see that based on model of retinal blood vessels, through constructing image normalized gradient vector divergence, extracting vascular centerline and use different directional laplacian to focus on high/low contract vessels and make this as the prior knowledge for random walk model can achieve the detailed segment for low contract, weak border's retinal vessels, which proved the effectiveness of the vessel segment method.

Table 2 is the accuracy data of different segmentation results. From the data in Table 2 can be seen that the method proposed in this study in the vascular pixel accuracy and the accuracy is higher than Hoover algorithm and clinical color fundus images, but present with clinical and fundus fluoresce in angiography image accuracy compared to still have certain difference, but the two accuracy approaching the size, but the fundus fluoresce in angiography image in the vasculature of the correctly extracted ones is superior to the method proposed in this study.

CONCLUSION

Diabetic retinopathy is a vascular abnormal caused by diabetes, thus result in the change of abnormal retinal ischemia. Seen from clinical fundus: a series of retinal changes such as retinal capillary hemangioma, hard exudates, cotton wool spots, retinal capillary and small artery atresia, neovascularization and fibrous proliferation, retinal detachment, they can lead to severe breaks of visual function (Zhang and Zhao, 2006). Diabetic retinopathy clinical diagnosis is based on ophthalmoscopy fundus and Fundus Fluoresce in Angiography (FFA). We can decide the next checking steps based on fundus and whether FFA image displays retinal perfusion and angiogenesis, including drug therapy and laser photocoagulation and the vitreous body should be cut when fibrous proliferation happens.

However, the FFA Check cannot display all the vascular lesions clearly no matter for the drugs or laser treatment, the direction and the treatment effect is not good enough and patients' visual function cannot be greatly improved. This study did some research on the theory and application on the method of segmentation of retinal blood vessel images. From the effect of segmentation we see that this method can divide and process the image of retinal vascular more clearly and in details, thus improved the precision greatly. So, using this method to process and analyze the retinal vascular can help ophthalmologist find the disease earlier and make the early decision, which provides a new idea for treatment of diabetic retinopathy study and finding earlier therapy methods in order to eliminate the disease in the bud, recover the visual function of patients and help improve their life quality.

ACKNOWLEDGMENT

This study is supported by Guo-dong You, Feng-yuan Sun, Tang Dongrun, Feng-ru Liu, Tong Wu and Hei Luning.

REFERENCES

- Benson, S.Y.L. and Y. Hong, 2008. A novel vessel segmentation algorithm for pathological retinal images based on the divergence of vector fields [J]. IEEE T. Med. Imaging, 27: 237-246.
- Chanwimaluang, T. and F. Guoliang, 2003. An efficient blood vessel detection algorithm for retinal images using local entropy thresholding [J]. Proceedings of the International Symposium on Circuits and Systems, Springer Verlag, Bangkok, pp: 21-24.
- Chaudhuri, S., S. Chatterjee, N. Katz, M. Nelson and M. Goldbaum, 1989. Detection of blood vessels in retinal images using two-dimensional matched filters [J]. IEEE T. Med. Imaging, 8(3): 263-269.

- Fan, Y., T.Z. Jiang and J.E. David, 2002. Volumetric segmentation of brain images using parallel genetic algorithms [J]. *IEEE T. Med. Imaging*, 21(8): 904-909.
- Hoover, A., V. Kouznetsova and M. Goldbaum, 2000. Locating blood vessels in retinal images by piecewise threshold probing of a matched filter response [J]. *IEEE T. Med Imaging*, 19: 203-210.
- Huang, S.Y. and E.H. Zhang, 2006. A method for segmentation of retinal image vessels [A]. *Proceedings of the 6th World Congress on Intelligent Control and Automation, Dalian, New York*, pp: 9673-9676.
- Li, L., 2007. Treatment of diabetic eye disease early [J]. *Sci. Tech. Daily*, pp: 813-814.
- Li, J., 2009. Study on some key problems in processing and analyzing of the fundus images [D]. Ph.D. Thesis, Beijing Jiaotong University, China, 6: 50-64.
- Li, J.P., H.J. Chen and X.Y. Zhang, 2009. Segmentation of retinal blood vessels based on prior knowledge random walks model [J]. *Chinese J. Biomed. Eng.*, 28: 501-507.
- Mendonca, A.M. and A. Campilho, 2006. Segmentation of retinal blood vessels by combining the detection of centerlines and morphological reconstruction [J]. *IEEE T. Med. Imaging*, 25: 1200-1213.
- Otsu, N., 1979. A threshold selection method from gray-level his tograms [J]. *IEEE T. Syst. Man Cyb.*, 9(1): 62-66.
- Ricci, E. and R. Perfetti, 2007. Retinal blood vessel segmentation using line operators and support vector classification [J]. *IEEE T. Med. Imaging*, 26: 1357-1365.
- Soares, J.V.B., J.J.G. Leandro, R.M. Cesar, H.F. Jelinek and M.J. Cree, 2006. Retinal vessel segmentation using the 2-D Gabor wavelet and supervised classification [J]. *IEEE T. Med. Imaging*, 25: 1214-1222.
- Staal, J., M.D. Abramoff, M. Niemeijer, M.A. Viergever and B. Van Ginneken, 2004. Ridge based vessel segmentation in color images of the retina [J]. *IEEE T. Med. Imaging*, 23: 501-509.
- Wang, D. and X. Li, 2003. Research situation and development prospect of ophthalmic informatics [J]. *Chinese J. Ophthalmol.*, 39: 187-189.
- Wang, S., L. Xu and J. Li, 2005. Study on the epidemiology of the relationship between retinal microvascular abnormalities and cardiovascular and cerebrovascular disease [J]. *Section Ophthalmol. Foreign Med. Sci.*, 29(3).
- Wang, X.X., Q. Wang and H. Bao, 2006. Review of the development of ophthalmic informatics [J]. *Chinese J. Ophthalmol.* 42: 476-480.
- Yang, W., L. Wang and S. Hu, 2005. Features of computer-assistant three-dimensional ultrasound diagnosis in ocular fundus diseases [J]. *Chinese J. Ocul. Fundus Dis.*, 21: 351-353.
- Yao, C. and H. Chen, 2010. Automated blood vessel network segmentation in pathological retinal images [J]. *Acta Electron. Sinica*, 5: 1226-1233.
- Zhang, C., 1997. *Fundus Epidemiology* [M]. People's Medical Publishing House, pp: 223-250.
- Zhang, Y., 2005. The progress and prospect of medical imaging [J]. *J. Chinese Modern Imaging*, 6: 103-105.
- Zhang, C. and X. Liu, 2002. The present situation and development trend of clinical and research study for fundus diseases in China [J]. *Chinese J. Ophthalmol.*, 38: 129-131.
- Zhang, B. and J. Zhao, 2006. Clinical efficacy of ligustrazine phosphate and sodium chloride injection in the treatment of background diabetic retinopathy [J]. *Public Med. Forum Mag.*, Vol. 14.