

Research Article

Changes in the Spermatogenesis and Histology of Testis in Rat Treated with *Matricaria recutita*

¹Fereshteh Javadian, ²Jasem Estakhr, ¹Jina Khayatzade, ³Abbas Jamshidiyan and ⁴Dariush Saadati

¹Department of Biology, Faculty of Science, Mashhad Branch, Islamic Azad University, Mashhad, Iran

²Department of Biology, Faculty of Science,

³Department of Photobiology,

⁴Department of Food Hygiene and Quality Control, Faculty of Veterinary Medicine, University of Zabol, Zabol, Iran

Abstract: The present study investigates the anti-spermatogenic potential of ethanolic extract of *Matricaria recutita* a plant belonging to Asteraceae family. The effects of an ethanolic extract of the *Matricaria recutita* on spermatogenesis, histology of testis and level of testosterone were examined in control and experimental groups. Results showed that *Matricaria recutita* extract did not cause any changes in body weight, but significantly decreased the testis weight ($p < 0.05$). The sperm motility and the epididymal sperm counts and serum testosterone levels of rats treated for 56 days were significantly reduced ($p < 0.05$). There were various degrees of damage to the seminiferous tubules including; disorganized germinal epithelium, degenerated and necrotic cells and reduction in the diameter of seminiferous tubules. It can be concluded that that alcoholic extract of *Matricaria recutita* has anti-spermatogenic properties in adult male rats through its compounds and it may be useful to regulate spermatogenesis and male fertility.

Keywords: Anti-spermatogenic, *Matricaria recutita*, rat, testis

INTRODUCTION

Matricaria recutita, once it has been called as *Marticaria chamomilla*, *Chamomilla recutita* and *Chamomilum nobile* family Asteraceae and commonly it is known as German chamomile, Roman chamomile, English chamomile, Camomilla and Flos Chamomile (WHO, 2003; Micromedex Healthcare Series, 2003) It mainly grows indigenously in Europe, NW. Asia, N. Africa and cultivated in N. America and in many parts of the world (Wald and Brendler, 1998). This herb has been used as herbal remedies for thousands of years. One of the most commonly consumed single ingredient herbal tea is chamomile, prepared with dried flowers from *Matricaria recutita*. The composite flower is white in color with a yellowish orange center (WHO, 2003). Infusions and essential oils from fresh or dried flower heads have aromatic, flavoring and coloring properties. Both are used in a number of commercial products including soaps, detergents, perfumes, lotions, ointments, hair products, baked goods, confections, alcoholic beverages and herbal teas. Chamomile flowers contain 0.24 to 2.0% volatile oil that is blue in color (Wald and Brendler, 1998). *Matricaria recutita* is well known for its pharmaceutical properties including; anti-inflammatory (Shipochliev *et al.*, 1981; Al-

Hindawi *et al.*, 1989), immunomodulatory activity (Uteshev *et al.*, 1999), arcaricadal property (Macchioni *et al.*, 2004), anti-cancer activity (Srivastava and Gupta, 2007), antipruritic effect (Kobayashi *et al.*, 2005), wound healing property (Nayak *et al.*, 2007; Jarrahi, 2008; Jarrahi *et al.*, 2008; Martins *et al.*, 2009), treatment of oral mucositis (Mazokopakis *et al.*, 2005), intracanal irrigant (Sadr Lahijani *et al.*, 2006), Treatment of infant botulism (Bianco *et al.*, 2008), treatment of gastrointestinal disorders (Mahady *et al.*, 2005), antimicrobial activity (Nogueira *et al.*, 2008), antiulcer activity (Khayyal *et al.*, 2001), treatment of stress and depression (Pinto *et al.*, 2008), anti-allergic activity (Kobayashi *et al.*, 2003), antisolar agent (Ramos *et al.*, 1996), inhibition of poliovirus replication (Vilaginès *et al.*, 1985), anxiolytic agent (Amsterdam *et al.*, 2009), Prevent osteoporosis (Kassi *et al.*, 2004).

The use of *Matricaria recutita* extract tracts in the treatment of various ailments is increasing, but its impacts on the reproductive system have not been reported. The present study was to investigate the effects of *Matricaria recutita* leaf extract on male rat reproductive functions, such as sperm characteristics, histology of testis and testosterone secretion.

Corresponding Author: Fereshteh Javadian, Department of Biology, Faculty of Science, Mashhad Branch, Islamic Azad University, Mashhad, Iran, Tel.: +989153422059

This work is licensed under a Creative Commons Attribution 4.0 International License (URL: <http://creativecommons.org/licenses/by/4.0/>).

MATERIALS AND METHODS

Plant Material: *Matricaria recutita* collected from Agricultural Research institute at University of Zabol, Zabol, Iran, in March 2011 and authenticated at Department of Biology, University of Zabol. Its leaves, fruits and flowers were dried, under shade and powdered. The extract was prepared by maceration method (80% ethanol in 300 g/L for 48 h), filtered with filter paper. Ethanol was removed by rotary evaporator. The extract was dissolved in normal saline and administered orally into rats.

Animals and treatments: Twenty one Healthy adult male wistar rats (10-12 weeks old, 200-300 g), purchased from Razi Institute (Karaj, Iran) and were housed in animal house, at ambient room temperature with a controlled light and dark period of 12 h. The animals were fed with a standard laboratory food (pellets) and provided ad libitum. They were weighted before and after the study. After 7 days for adapting to the new environment, the rats were randomly divided into three groups of control (treated with normal saline for the period of 56 days, n = 7), experimental1 (treated with 100 mg/kg/day of *Matricaria recutita* extract for 56 days, n = 7) and experimental2 (treated with 100 mg/kg/day of *Matricaria recutita* extract for 56 days, n = 7) groups.

Tissue preparation: At the end of the treatment period, the pentobarbital sodium (40 mg/kg i.p.) was administered for anesthesia. Testes were removed, cleaned of adhering tissue and weighed. The epididymis was removed, used for sperm analysis and testes samples were.

Sperm analysis: Epididymis was exposed by scrotal incision and sperms were expressed out by cutting distal end of the caudal epididymidal tubule. Sperms with epididymal fluid were diluted with hanks balanced salt solution and sperm count and motility were studied. Sperm suspension was placed on both sides of Neubauer's hemocytometer and allowed to settle in a humid chamber for 1 h. The number of sperms in the appropriate squares of the hemocytometer was counted under the microscope of 100· magnification.

Histological studies: Testes were fixed in formalin 10% and after tissue processing were stained with H&E (Hematoxylin and Eosine) for histological studies under light microscope.

Hormonal assay: After cervical dislocation, blood collected in dry tubes. The blood samples were centrifuged and the serum was immediately stored in the freezer (-20EC) for the measurement of testosterone. Testosterone was measured by means of radioimmunoassay.

Statistical analysis: All data were analyzed with IBM® PASW/SPSS® Statistics 18.0-2009. Whereas weighing of rats performed at different time during the study, Repeated Measures ANOVA was used for analysis of body weight. Mean and standard error were calculated and the significance of difference was analyzed by applying One Way ANOVA for analysis of other parameters of the study. Level of significance difference was $p < 0.05$.

RESULTS

The results recorded in Table 1, show that there is an increase in the body weight of experimental groups in compare with control however this increase is not significance ($p < 0.05$). According to the results, significant reduction in the testes weight of experimental groups was observed compare to control group ($p < 0.05$) (Table 1). Results about sperm parameters showed, treatment of rat with *Matricaria recutita* significantly reduced sperm count and motility in experimental groups ($p < 0.05$). From the Fig. 1 it can be observed easily that percentage of none motile sperms and sperms with slow progressive motion have

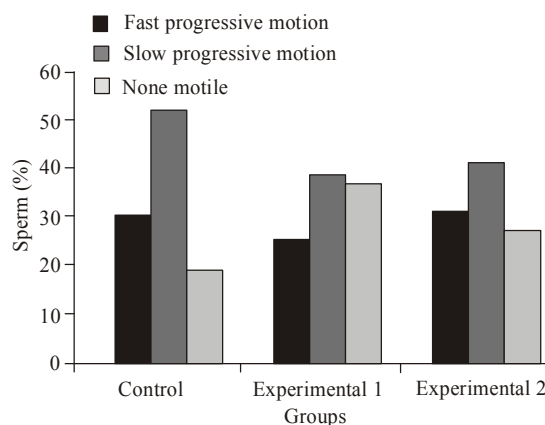


Fig. 1: Increase of percentage of none motile sperms and decrease of sperms with slow progressive motion in groups treated with *Matricaria recutita*

Table 1: Effects of *Matricaria recutita* extract on body weight, testis weight, sperm count and testosterone level in rats

Groups	Body weight (g)	Testis weight (mg/100 g)	Sperm count $\times 10^7$ /mL	Testosterone (ng/mL)
Control	227.9 \pm 1.57	0.505 \pm 0.015	48.29 \pm 1.539	0.728 \pm 0.0055
Experimental 1	229.0 \pm 1.58	0.479 \pm 0.003*	42.71 \pm 1.149*	0.680 \pm 0.0060**
Experimental 2	229.4 \pm 1.61	0.484 \pm 0.002*	42.14 \pm 0.738*	0.693 \pm 0.0049**

n: 7; *, $p < 0.05$; **, $p < 0.001$ compared with the corresponding controls

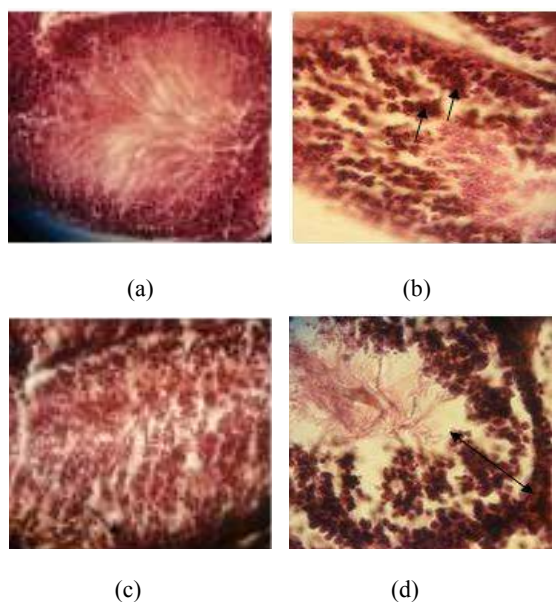


Fig. 2: Light micrograph of testes of rats treated with *Matricaria recutita* extract 56 days. (A) Normal seminiferous tubules of control group, (B and C) Degenerated and necrotic cells in some seminiferous tubules of both experimental groups, (D) Disorganized germinal epithelium seminiferous tubules of experimental groups. H & E, 40 x

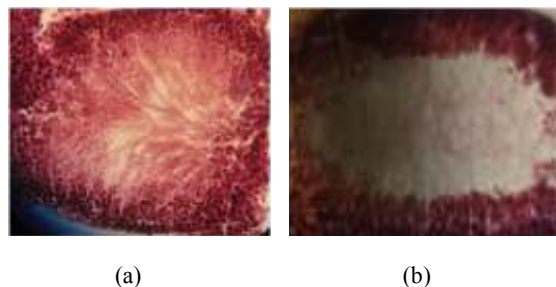


Fig. 3: Reduction of sperm concentration in the center of seminiferous tubules of experimental groups. H & E, 40 x

been increased and decreased, respectively in experimental groups. Measurement of hormone indicated a significant decrease in the testosterone level of experimental groups in compare with control groups ($p < 0.001$).

Results from histological studies showed normal seminiferous tubules in control group (Fig. 2a). Degenerated and necrotic cells were observed in some seminiferous tubules of both experimental groups (Fig. 2B and C). In animals that received 150 mg/kg/day alcoholic extract of *Matricaria recutita* (experimental 1) for 56 days, there were seen disorganized germinal epithelium in the most of seminiferous tubules (Fig. 2D). From the histological studies it is observable truly that concentration of sperm in the center of seminiferous tubules of experimental groups has been reduced (Fig. 3). Studies

Table 2: Effects of *Matricaria recutita* extract on the diameter of seminiferous tubule (mm)

Groups	Diameter of seminiferous tubule (mm)
Control	0.30±0.03
Experimental 1	0.27±0.03*
Experimental 2	0.28±0.03*

*: $p < 0.05$

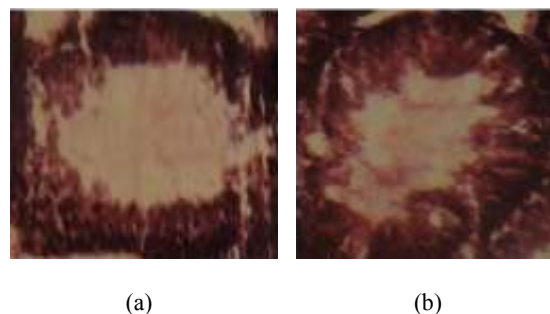


Fig. 4: Effects of *Matricaria recutita* extract on the diameter of seminiferous tubule. H & E, 40 x

also exhibited that there is a reduction in the diameter of seminiferous tubules of experimental groups comparing with control groups (Table 2, Fig. 4).

DISCUSSION

Toxic effects of plant extracts evaluated via changes in the body weight and other organs. In the male reproductive system reduction in the testis weight, epididymis, glands and other tubules and also reduction in the sperm count and motility are standard factors for assessment of toxic effects of extracts on it Da *et al.* (2000). Decrease in the testis and accessory genital glands weight may be due to reduction in the protein concentration in these organs. In this study *Matricaria recutita* extract has not any side effects on body weight and it can be resulted that this plant does not create acute toxic condition in rats. Testicular size and weight is the best primary assessment of spermatogenesis. About testis it should be noted that created reduction has several reasons include; changes in the level of testosterone, decrease in the sperm count and changes in the testis histology. Data from sperm count and motility showed a significant decrease in treated group compared with the control group. This could be due to the influence of the extract on the cell cycle or cell division. Also it is possible that, these changes might be due to an alteration in the microenvironment in the cauda epididymis. The extract can make a toxic microenvironment with its chemical compounds, thus it influences sperm count and motility. There was found an alteration in the spermatogenesis process, such as disorganized germ epithelium, degenerated and necrotic cells that could cause reduction in the diameter of seminiferous tubule. These alterations might be caused by cytotoxicity of *Matricaria recutita* extract. According to the results, we concluded that ethanolic extract of *Matricaria recutita* has antispermatogenic potential in adult male rat.

REFERENCES

- Al-Hindawi, M.K., I.H. I-Deen, M.H. Nabi and M.A. Ismail, 1989. Anti-inflammatory activity of some Iraqi plants using intact rats. *J. Ethnopharmacol.*, 26(2): 163-8.
- Amsterdam, J.D., Y. Li, I. Soeller, K. Rockwell, J.J. Mao and J. Shults, 2009. A randomized, double-blind, placebo-controlled trial of oral *Matricaria recutita* (chamomile) extract therapy for generalized anxiety disorder. *J. Clin. Psychopharmacol.*, 29(4): 378-82.
- Bianco, M.I., C. Lúquez, L.I. De Jong and R.A. Fernández, 2008. Presence of clostridium botulinum spores in *Matricaria chamomilla* (chamomile) and its relationship with infant botulism. *Int. J. Food Microbio.*, 121(3): 357-60.
- Da, S., R.C. Sà, A.A. Vireque, P. De, J.E. Reis and M. Guerra, 2000. Evaluation of the toxicity of *Solanum tyococarjurn* in the reproductive system of male mice and rats. *J. Ethnopharmacol.*, 73: 283-287.
- Jarrahi, M., 2008. An experimental study of the effects of *Matricaria chamomilla* extract on cutaneous burn wound healing in albino rats. *Nat. Prod. Res.*, 22(5): 422-427.
- Jarrahi, M., A.A. Vafaei, A.A. Taherian, H. Miladi and A. Rashidi Pour, 2008. Evaluation of topical *Matricaria chamomilla* extracts activity on linear incisional wound healing in albino rats. *Nat. Prod. Res.*, 22(14): 1197-202.
- Kassi, E., Z. Papoutsi, N. Fokialakis, I. Messari, S. Mitakou and P. Moutsatsou, 2004. Greek plant extracts exhibit Selective Estrogen Receptor Modulator (SERM)-like properties. *J. Agric. Food Chem.*, 52(23): 6956-61.
- Khayyal, M.T., M.A. El-Ghazaly, S.A. Kenawy, M. Seif-el-Nasr, L.G. Mahran, Y.A. Kafafi and S.N. Okpanyi, 2001. Antiulcerogenic effect of some gastrointestinally acting plant extracts and their combination. *Arzneimittelforschung*, 51(7): 545-53.
- Kobayashi, Y., Y. Nakano, K. Inayama, A. Sakai and T. Kamiya, 2003. Dietary intake of the flower extracts of German chamomile (*Matricaria recutita* L.) inhibited compound 48/80-induced itch-scratch responses in mice. *Phytomedicine*, 10(8): 657-664.
- Kobayashi, Y., R. Takahashi and F. Ogino, 2005. Antipruritic effect of the single oral administration of German chamomile flower extract and its combined effect with antiallergic agents in ddY mice. *J. Ethnopharmacol.*, 101(1-3): 308-312.
- Macchioni, F., S. Perrucci, F. Cecchi, P.L. Cioni, I. Morelli and S. Pampiglione, 2004. Acaricidal activity of aqueous extracts of camomile flowers, *Matricaria chamomilla*, against the mite *Psoroptes cuniculi*. *Med. Vet. Entomol.*, 18(2): 205-207.
- Mahady, G.B., S.L. Pendland, A. Stoia, F.A. Hamill, D. Fabricant, B.M. Dietz and L.R. Chadwick, 2005. In vitro susceptibility of helicobacter pylori to botanical extracts used traditionally for the treatment of gastrointestinal disorders. *Phytother Res.*, 19(11): 988-991.
- Martins, M.D., M.M. Marques, S.K. Bussadori, M.A. Martins, V.C. Pavesi, R.A. Mesquita-Ferrari and K.P. Fernandes, 2009. Comparative analysis between *Chamomilla recutita* and corticosteroids on wound healing: An *in vitro* and *in vivo* study. *Phytother Res.*, 23(2): 274-278.
- Mazokopakis, E.E., G.E. Vrentzos, J.A. Papadakis, D.E. Babalis and E.S. Ganotakis, 2005. Wild chamomile (*Matricaria recutita* L.) mouthwashes in methotrexate-induced oral mucositis. *Phytomedicine*, 12(1-2): 25-27.
- Micromedex Healthcare Series, 2003, MICROMEDEX, Inc., Englewood, Colorado, Vol. 115, expires 3.
- Nayak, B.S., S.S. Raju and A.V. Rao, 2007. Wound healing activity of *Matricaria recutita* L. extract. *J. Wound Care*, 16(7): 298-302.
- Nogueira, J.C., F. Diniz Mde and E.O. Lima, 2008. In vitro antimicrobial activity of plants in acute otitis externa. *Braz J. Otorhinolaryngol.*, 74(1): 118-124.
- Pinto, S.A., E. Bohland, P. Coelho Cde, M.S. Morgulis and L.V. Bonamin, 2008. An animal model for the study of *Chamomilla* in stress and depression: Pilot study. *Homeopathy*, 97(3): 141-144.
- Ramos, M.F., E.P. Santos, C.H. Bizarri, H.A. Mattos, M.R. Padilha and H.M. Duarte, 1996. Preliminary studies towards utilization of various plant extracts as antisolar agents. *Int. J. Cosmet Sci.*, 18(3): 87-101.
- Sadr Lahijani, M.S., H.R. Raof Kateb, R. Heady and D. Yazdani, 2006. The effect of German chamomile (*Marticaria recutita* L.) extract and tea tree (*Melaleuca alternifolia* L.) oil used as irrigants on removal of smear layer: A scanning electron microscopy study. *Int. Endod. J.*, 39(3): 190-195.
- Shipochliev, T., A. Dimitrov and E. Aleksandrova, 1981. Anti-inflammatory action of a group of plant extracts. *Vet. Med. Nauki.*, 18(6): 87-94.
- Srivastava, J.K. and S. Gupta, 2007. Antiproliferative and apoptotic effects of chamomile extract in various human cancer cells. *J. Agric. Food Chem.*, 55(23): 9470-9478.
- Uteshev, B.S., I.L. Laskova and V.A. Afanasev, 1999. The immunomodulating activity of the heteropolysaccharides from German chamomile (*Matricaria chamomilla*) during air and immersion cooling. *Eksp Klin Farmakol*, 62(6): 52-55.
- Vilaginès, P., P. Delaveau and R. Vilagines, 1985. Inhibition of poliovirus replication by an extract of *Matricaria chamomilla* (L). *C. R. Acad. Sci. III*, 301(6): 289-294.

Wald, G. and T. Brendler, 1998. PDR for Herbal Medicines. 1st Ed., Medical Economics Company Publishers, Montville, NJ, pp: 903-904.

WHO, 2003. Monograph on Selected Medicinal Plants. Retrieved from: <http://www.who.int/medicines/library>.