

## Research Article

### Robust Classification of Primary Brain Tumor in MRI Images using Wavelet as the Input of ANFIS

<sup>1</sup>B. Rajesh Kumar and <sup>2</sup>S. Karpagaiswarya

<sup>1</sup>Department of Computer Science and Engineering, RVS College of Engineering and Technology, Coimbatore, India

<sup>2</sup>Anna University (Regional Centre), Coimbatore, India

**Abstract:** This study presents a neural network based technique for automatic classification of Magnetic Resonance Images (MRI) of the brain in two categories of benign and malignant. The proposed method consists the following stages; i.e., preprocessing, tumor region segmentation, feature extraction using DWT and classification using ANFIS classifier. Preprocessing involves removing low-frequency surrounding noise, normalizing the intensity of the individual particle images. In the second stage, the fuzzy Connectedness segmentation is used for partitioning the image into meaningful regions. In feature extraction, the obtained feature connected to MRI images using the Discrete Wavelet Transform (DWT). In the classification stage, ANFIS Classifier is used to classify the subjects to normal or abnormal (benign, malignant). The proposed technique gives high-quality results for brain tissue detection and is more robust and efficient compared with other recent works.

**Keywords:** ANFIS, classification, Discrete Wavelet Transform (DWT), fuzzy connectedness segmentation

## INTRODUCTION

Brain tumors can be either malignant (cancerous) or benign (non-cancerous). Primary brain tumors (i.e., brain cancer) comprise two main types: gliomas and malignant meningiomas (Silipo *et al.*, 1999). Gliomas are a familiar type of malignant tumors that consist of a variety of types, named for the cells from which they occur: astrocytomas, oligodendrogliomas and ependymomas. Meningiomas arise from the meninges, which are tissues that surround the external part of the spinal cord and brain. The majority of meningiomas are benign and can be cured by surgery. There are a number of extraordinary brain tumors, with medulloblastomas, which develop from the primitive stem cells of the cerebellum and are most habitually seen in children. The brain is a site where both primary and secondary malignant tumors can occur; secondary brain tumors usually begin to another place in the body and next metastasize, or spread, to the brain.

Benign tumours may form in various parts of the body. Benign tumours grow gradually and do not spread into other tissues. They are not cancerous and are not usually life-threatening. They often do no harm if they are left alone. However, some benign tumours can cause problems. For example, some grow somewhat large and may cause local pressure symptoms in the brain. It arise from cells in hormone glands compose too much hormone which cause

unwanted effects. Malignant tumour is a growth of tissue made up from cancer cells which continue to reproduce. Malignant tumours occupy into nearby tissues and organs, which can cause damage. It spread to other parts of the body. This happens if a few cells split off from the primary tumour and are passed in the bloodstream to other parts of the body (Ashby *et al.*, 2006). These small groups of cells after that grow to form secondary tumours (metastases) in one or additional parts of the body. These secondary tumours may then grow, invade and break nearby tissues and multiply for a second time. Primary malignant brain tumour is a tumor which arises from a cell inside the brain. The cells of the tumour raises and break normal brain tissue. It is similar to benign brain tumours, they can raise the pressure within the skull. It rarely spread to other parts of the body. Secondary malignant brain tumour started in another division of the body and extend to the brain.

The causes of brain tumors are unknown, a small number of risk factors have been proposed. These contain head injuries, hereditary syndromes, immune control, prolonged exposure to ionizing radiation, electromagnetic fields, cell phones, or chemicals similar to formaldehyde and vinyl chloride. Symptoms of brain tumors incorporate continual headache, nausea and vomiting, eyesight, hearing and speech problems, walking and balance difficulties, personality changes, memory lapses, problems with cognition and

**Corresponding Author:** B. Rajesh Kumar, Department of Computer Science and Engineering, RVS College of Engineering and Technology, Coimbatore, India

This work is licensed under a Creative Commons Attribution 4.0 International License (URL: <http://creativecommons.org/licenses/by/4.0/>).

concentration and seizures. Glioma is a tumor that starts within the brain or spine and it arises from glial cells (Doolittle, 2004). The most familiar position of gliomas is the brain. Symptoms of glioma depend on which division of the central nervous system is affected. A brain glioma be able to cause headaches, nausea and vomiting seizures and cranial nerve disorders as an end result of increased intracranial pressure. A glioma of the optic nerve be able to cause visual loss. Spinal cord gliomas can cause pain, weakness, or lack of feeling in the extremities. Gliomas do not metastasize via the bloodstream, but they can spread via the cerebrospinal fluid and cause "drop metastases" to the spinal cord.

MTH is a feature extractor and descriptor to extract the image texture feature which integrates the advantages of co-occurrence matrix and histogram (Jayachandran and Dhanasekaran, 2013a). Here, the attribute of co-occurrence matrix and histogram is represented within this feature vector. The efficiency is achieved with brain tissue and tumor segmentation, feature extraction of the segmented regions and the classification based on support vector machine. Wavelet transforms is an effective tool for feature extraction, because they allow analysis of images at various levels of resolution (Sengur, 2008). This technique requires large storage and is computationally more expensive. Hence an alternative method for the dimensionality reduction scheme is used. In order to reduce the feature vector dimension and increase the discriminating power, the principal component analysis appealing since it effectively reduces the dimensionality of the data and therefore reduces the computational cost of analysis new data. Magnetic resonance image classification approach using enhanced Texton Co-occurrence Matrix and Fuzzy support vector machine is an one of the best method for classification. It consists of feature extraction and classification (Jayachandran and Dhanasekaran, 2013b). In feature extraction; we have taken the advantage of both co-occurrence matrix

and histogram to extract the texture feature from every segment to better classification of the image. In classification, fuzzy SVM classifier is used for improving the classification process. In this method only to T1-weighted post contrast brain MRI images.

### PROPOSED BRAIN TUMOR CLASSIFICATION METHOD

Brain tumor is a compilation of anomalous cells that grow within the brain or around the brain. Tumors can straightforwardly wipe out all the normal brain cells. It can also indirectly harm the strong cells by crowding other components of the brain and producing pain, brain swelling and stress inside the cranium (Jaya *et al.*, 2009). The process of segmenting tumors in brain MRI images rather than normal scenes is mainly challenging. In the proposed method, DWT is used for texture feature extraction and ANFIS classifier is used for texture classification for diagnosis of brain tumor in MRI images. In this method, various texture and intensity based features are extracted using DWT. In classification ANFIS is used to classify the experimental images into normal and abnormal class. The overall process is depicted in the block diagram, given in Fig. 1.

**Preprocessing:** Preprocessing involves removing low-frequency surroundings noise, normalizing the intensity of the individual particle images, removing reflections and masking portions of images. Wiener filter is used to remove the background noise and thus preserving the edge points in the image. The acquisition system corrupts MR images by generating noise. In order to improve the image quality an wiener filtering is used. This technique applies a concurrent filtering and contrast stitching. During filtering homogenous zones, anisotropic filter preserves the edges of objects. In

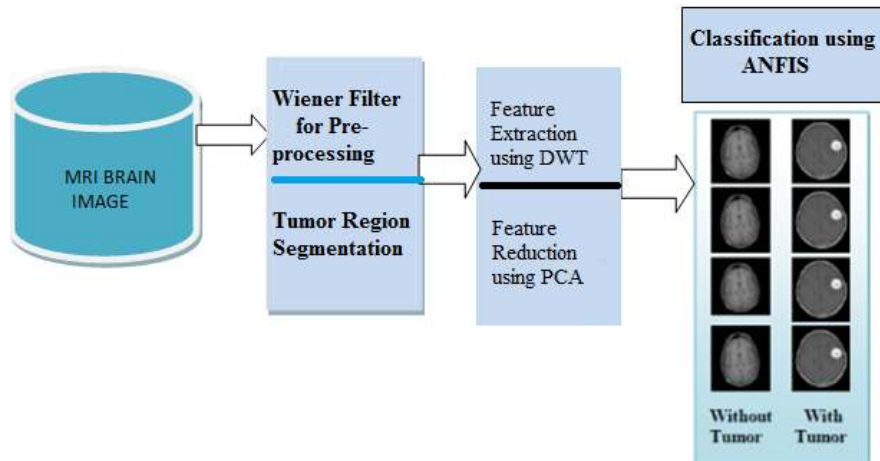


Fig. 1: Block diagram of proposed tumor classification method

wiener filter Gerig *et al.* (1992), a diffusion constant related to the noise gradient and smoothing the background noise by filtering a proper threshold value is chosen. For this purpose higher diffusion constant value is chosen compare with the absolute value of the noise gradient in its edge. Head mask was constructed by thresholding the filtered image. Matching intensity ranges in all the images, the highest and lowest intensities are limited to the interval (0, 255).

**Tumor region segmentation:** Segmentation refers to partitioning an image into important regions, in order to distinguish objects (or regions of interest) from background. There are two main approaches, region-based method in which similarities are detected and boundary-based method in which discontinuities are detected and connected to form boundaries around the regions. Segmentation of nontrivial images is one of the most complicated tasks in image processing. Segmentation accuracy determines the eventual success or failure of computerized analysis procedures.

Thresholding segmentation is used to differentiate brain regions from scalp and pathological tumor tissues from normal tissues. Segmentation, hierarchically, starts by brain detection from skin-neck-bone and ventricles and finally tumor detection from brain images. For detecting brain regions from scalp the algorithm in Lukas *et al.* (2004) is used. In FCS the region is iteratively grown by comparing all unallocated neighboring pixels to the region. The difference between a pixel intensity value and the region's mean, is used as a measure of similarity. The pixel with the smallest difference measured this way is allocated to the respective region (Schmidt *et al.*, 2005).

**Feature extraction using DWT:** Wavelets are numerical functions that decompose data into different

frequency components. Wavelets have emerged as dominant new mathematical tools for analysis of difficult datasets. The Fourier transform provides representation of an image based simply on its frequency content. Hence this representation is not spatially localized while wavelet functions are localized in space. The Fourier transform decomposes a signal into a spectrum of frequencies whereas the wavelet analysis decomposes a signal into a hierarchy of scales ranging from the coarsest scale. Hence Wavelet transform which provides representation of an image at various resolutions is a better tool for feature extraction from images (Chaplot *et al.*, 2006).

The DWT is an implementation of the wavelet transform using a discrete set of the wavelet scales and conversion following some defined rules (Mallat, 1980). The family of wavelet functions is represented in equation:

$$\psi_{m,n}(t) = 2^{m/2} \psi(2^m t - n) \quad (1)$$

The wavelet transform decomposes a signal  $x(t)$  into a family of synthesis wavelets as given below in Eq. (2) and (3):

$$x(t) = \sum_m \sum_n C_{m,n} \psi_{m,n}(t) \quad (2)$$

where,

$$c_{m,n} = \langle x(t), \psi_{m,n}(t) \rangle$$

For a discrete-time signal  $x(n)$ , the wavelet decomposition on  $I$  octaves is given by:

$$x[n] = \sum_{i=1}^{I_{tot}} \sum_{k \in Z} c_{i,k} g[n-2^i k] + \sum_{k \in Z} d_{I,k} h_I[n-2^I k] \quad (3)$$

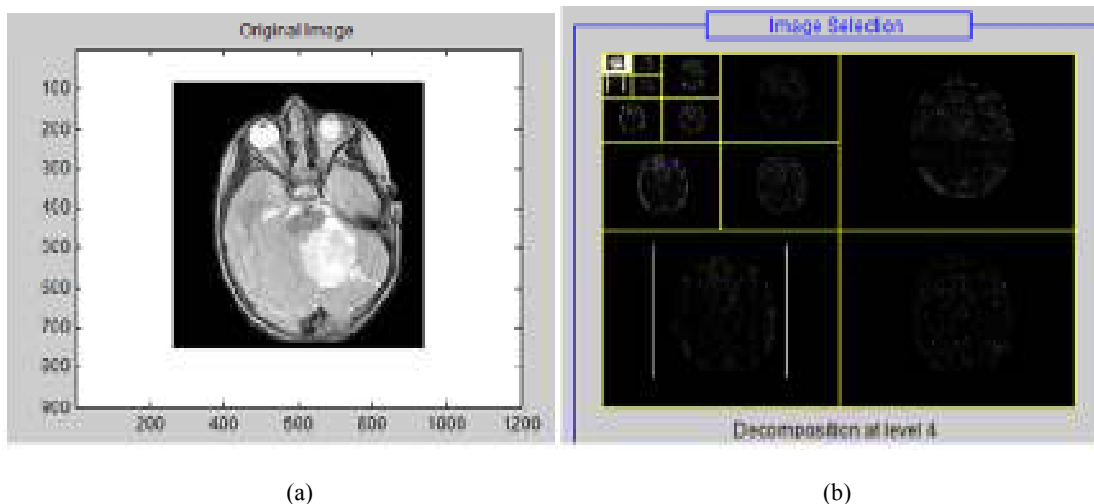


Fig. 2: (a) Original image, (b) decomposition at level 4

where,  $c_{i,k}$  = 1...I is wavelet coefficients and  $d_{i,k}$  = 1...I is scaling coefficients.

The feature extraction of MRI images is obtained using DWT domain subimages. The DWT is implemented using cascaded filter banks in which the lowpass and highpass filters satisfy particular constraints. For feature extraction, only the subimage LL is used for DWT decomposition at next scale. The LL submerge at the last level is used as output features. Using this algorithm, using a 4-level DWT, the size of the input matrix is reduced from 65536 to 64. The original image and decomposition level 4 image is shown in Fig. 2.

**Feature reduction:** Feature selection methods can be divided into feature ranking methods and feature subset selection methods. The feature ranking methods compute a ranking score for each feature according to its discriminative power and then simply select the top ranked features as final features for classification. The principal component analysis and Independent Component Analysis (ICA) are two well-know tools for transforming the existing input features into a new lower dimensional feature space. In PCA, the input feature space is transformed into a lower-dimensional feature space using the largest eigenvectors of the correlation matrix. In the ICA, the original input space is transformed into an independent feature space with a dimension that is independent of the other dimensions. PCA is the most widely used subspace projection technique (Hiremath *et al.*, 2006). These methods provide a suboptimal solution with a low computational cost and computational complexity. Given a set of data, PCA finds the liner lower-dimensional representation of the data such that the variance of the reconstructed data is preserved. Using a system of feature reduction based on PCA limits the feature vectors to the component selected by the PCA.

**Feature classification using ANFIS:** ANFIS is one of hybrid intelligent neuro-fuzzy inference systems and it functioning under Takagi-Sugeno-type fuzzy inference system. A Neuro-Fuzzy (ANFIS) classifier is used to detect the abnormalities in the MRI brain images (Subasi, 2007). Generally the input layer consist of seven neurons corresponding to the seven features. The output layer consist of one neuron indicating whether the MRI is of a normal brain or abnormal and the hidden layer changes according to the number of rules that give best recognition rate for each group of features (Lashkari, 2010). Here the neuro-fuzzy classifier used is based on the ANFIS technique. An ANFIS system is a combination of neural network and fuzzy systems in which that neural network is used to determine the parameters of fuzzy system. ANFIS largely removes the

requirement for manual optimization of parameters of fuzzy system. The neuro-fuzzy system with the learning capabilities of neural network and with the advantages of the rule-base fuzzy system can improve the performance significantly and neuro-fuzzy system can also provide a mechanism to incorporate past observations into the classification process. In neural network the training essentially builds the system. However, using a neuro-fuzzy technique, the system is built by fuzzy logic definitions and it is then refined with the help of neural network training algorithms.

## EXPERIMENTAL RESULTS

The proposed method has been implemented using the MATLAB environment. It has been tested on real brain MRI images consisting of normal and abnormal brain images. The samples tumor and normal images are shown in Fig. 3.

The obtained experimental results from the proposed technique are shown in Fig. 3. In the testing phase, the testing dataset is given to the proposed technique to find the tumors in brain images. The brain tumor classification accuracy of the proposed system is evaluated using the evaluation metrics, such as sensitivity, specificity and accuracy (Zhu *et al.*, 2010):

$$Sensitivity = TP/(TP + FN)$$

$$Specificity = TN/(TN + FP)$$

$$Accuracy = (TN + TP)/(TN + TP + FN + FP)$$

where,  $TP$  stands for True Positive,  $TN$  stands for True Negative,  $FN$  stands for False Negative and  $FP$  stands for False Positive. As suggested by above equations, sensitivity is the proportion of true positives that are correctly identified by a diagnostic test. It shows how good the test is at detecting a disease. Specificity is the proportion of the true negatives correctly identified by a diagnostic test. It suggests how good the test is at identifying normal (negative) condition. Accuracy is the proportion of true results, either true positive or true negative, in a population. It measures the degree of veracity of a diagnostic test on a condition. The segmentation results of the proposed system is shown in Fig. 4.

In this system the classification process are two stages training stage and testing stage. In train stage we have utilized 30 images (20 tumor images and 10 non-tumor images) and the remaining 50 images for testing purpose. The obtained experimental results of the existing and proposed methods are given in Table 1. By analyzing the results, ETCM with FSVM approach has

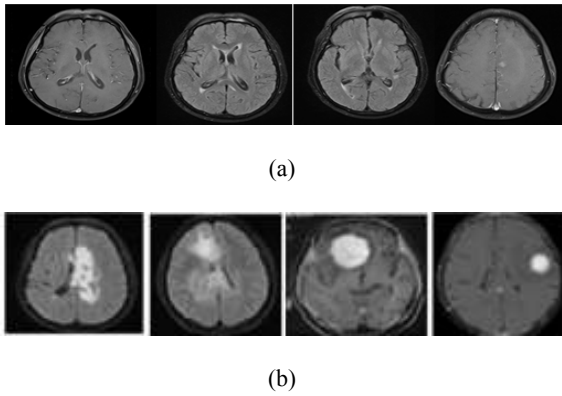


Fig. 3: MRI image dataset, (a) MRI images without tumor, (b) MRI images with tumor

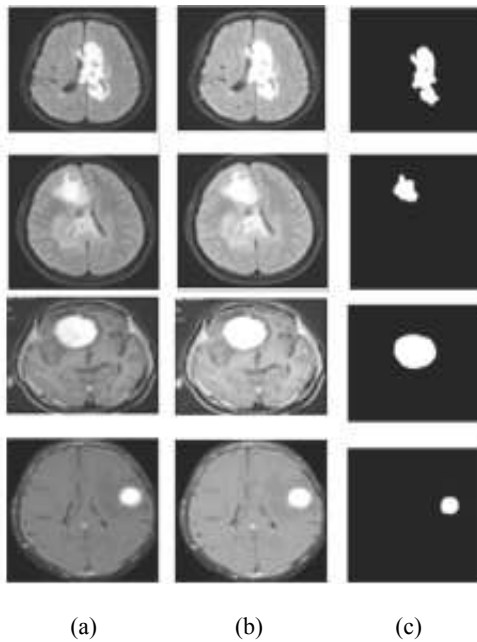


Fig. 4: (a) Original image, (b) filtered image, (c) segmented image

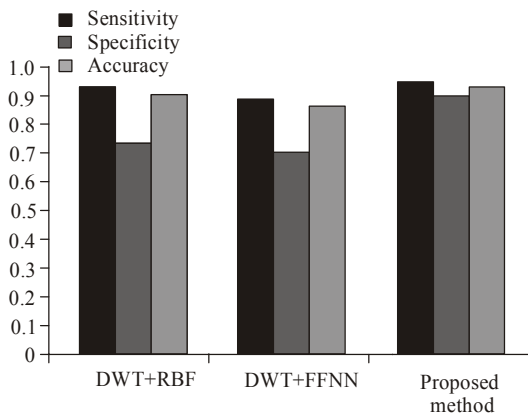


Fig. 5: Comparative analyses of DWT with FSVM, RBF and ANFIS

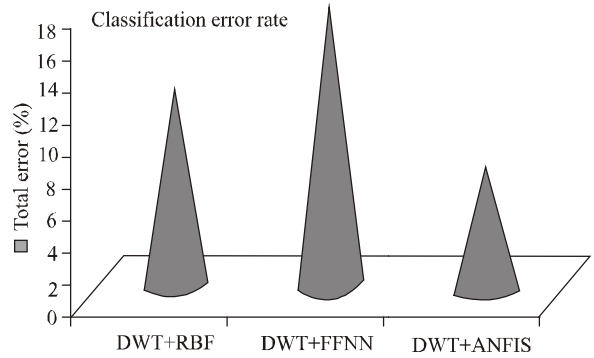


Fig. 6: Comparative error bar of the existing and proposed methods

Table 1: Detection accuracy of the DWT with various classifier approaches in testing data set

Evaluation metrics		DWT+RBF	DWT+FFNN	DWT+ANFIS
Input MRI image data set	TP	37	35	38
	TN	8	8	9
	FP	2	2	1
	FN	3	5	2
	Sensitivity	0.925	0.875	0.95
	Specificity	0.730	0.620	0.90
	Accuracy	0.900	0.860	0.94
	Total error (%)	12.500	17.500	7.50

a better performance. The outcomes of the experimentation proved with 94% of accuracy in enhanced Texton Co-occurrence Matrix based method with detection of tumors from the brain MRI images.

The evaluation graphs of the sensitivity, specificity and the accuracy graph are shown in Fig. 5. Also the proposed system error rate is less to other classifier; it is shown in Fig. 6. In this study, the proposed wavelet with Ada-boost classifier is compared to the other neural network classifier Feed Forward Neural Network (FFNN) and Radial Basis Function (RBF). The proposed model yields better overall results to other classifier in terms of above evaluation metrics. The overall classification error rate is shown in Fig. 6. Compared to the existing system the proposed brain tumor classification method error rate is very less. Based on the experimental results the proposed method produce better results compared to existing methods.

### CONCLUSION

In this study, we have developed a network-based classifier to differentiate normal and abnormal (benign or malignant) brain MRIs. The proposed technique consists of five steps, especially, preprocessing, Fuzzy Connectedness segmentation, connected component labeling, feature extraction using DWT and classification using ANFIS classifier respectively. In the preprocessing stage, an Anisotropic filter is used to remove the noise and thus preserving the edge point of the image. In the FCS stage, an automatic seeded region

rising is used for partitioning an image into important regions. In the third stage, once all groups have been determined, every pixel is labeled according to the component to which it is assigned to. In the fourth the features are extracted using DWT and finally to classify normal and abnormal brain MR images ANFIS is used. According to experimental results, the proposed method is efficient for classification of human brain into normal and abnormal classes.

## REFERENCES

- Ashby, L.S., M.M. Troester and W.R. Shapiro, 2006. Central nervous system tumors. *Cancer Ther.*, 1: 475-513.
- Chaplot, S., L.M. Patnaik and N.R. Jagannathan, 2006. Classification of magnetic resonance brain images using wavelets as input to support vector machine and neural network. *Biomed. Signal Proces.*, 1: 86-92.
- Doolittle, N.D., 2004. State of the science in brain tumor classification. *Semin. Oncol. Nurs.*, 20: 224-230.
- Gerig, G., O. Kubler, R. Kikinis and F.A. Jolesz, 1992. Nonlinear anisotropic filtering of MRI data. *IEEE T. Med. Imaging*, 1(2): 221-232.
- Hiremath, P.S., S. Shivashankar and J. Pujari, 2006. Wavelet based features for color texture classification with application to CBIR. *Int. J. Comput. Sci. Network Sec.*, 6(9A): 124-133.
- Jaya, J., K. Thanushkodi and M. Karnan, 2009. Tracking algorithm for denoising of MR brain images. *IJCSNS Int. J. Comput. Sci. Netw. Secur.* 9(11): 262-267.
- Jayachandran, A. and R. Dhanasekaran, 2013a. Automatic detection of brain tumor in magnetic resonance images using multi-texton histogram and support vector machine. *Int. J. Imag. Syst. Tech.*, 23: 97-103.
- Jayachandran, A. and R. Dhanasekaran, 2013b. Brain tumor detection using fuzzy support vector machine classification based on a texton co-occurrence matrix. *J. Imaging Sci. Techn.*, 57(1): 10507-1-10507-7(7).
- Lashkari, A., 2010. A neural network based method for brain abnormality detection in MR images using gabor wavelets. *Int. J. Comput. Appl.*, 4(7): 9-13.
- Lukas, L., A. Devos, J.A. Suykens, L. Vanhamme, F.A. Howe, C. Majo's, A. Moreno-Torres, M. Van Der Graaf, A.R. Tate, C. Aru's and S. Van Huffel, 2004. Brain tumor classification based on long echo proton MRS signals. *Artif. Intell. Med.*, 31(1): 73-89.
- Mallat, S.G., 1980. A theory of multiresolution signal decomposition: The wavelet representation. *IEEE T. Pattern Anal.*, 11(7): 674-693.
- Schmidt, M., I. Levner, R. Greiner, A. Murtha and A. Bistritz, 2005. Segmenting brain tumors using alignment-based features. *Proceeding of 4th International Conference on Machine Learning and Applications*, Los Angeles.
- Sengur, A., 2008. An expert system based on principal component analysis, artificial immune system and fuzzy k-NN for diagnosis of valvular heart diseases. *Comput. Biol. Med.*, 51(3): 329-338.
- Silipo, R., G. Deco and H. Bartsch, 1999. Brain tumor classification based on EEG hidden dynamics. *Intell. Data Anal.*, 3(4): 287-306.
- Subasi, A., 2007. Application of adaptive neuro-fuzzy inference system for epileptic seizure detection using wavelet feature extraction. *Comput. Biol. Med.*, 37: 227-244.
- Zhu, W., N. Zeng and N. Wang, 2010. Sensitivity, specificity, accuracy, associated confidence interval and ROC analysis with practical SAS® implementations. *Proceeding of NESUG: Health Care and Life Sciences*. Baltimore, Maryland, pp: 1-9.